

Cardioprotective effect of vitamin D and melatonin on doxorubicin-induced cardiotoxicity in rat model: an electrocardiographic, scintigraphic and biochemical study

Serdar Savaş Gül¹, Hatice Aygün²

¹Department of Nuclear Medicine, Gaziosmanpaşa University School of Medicine, Tokat, Turkey

²Department of Physiology, Gaziosmanpaşa University School of Medicine, Tokat, Turkey

DOI: 10.18621/eurj.410029

ABSTRACT

Objectives: Doxorubicin (DOX) is an antineoplastic drug that is widely used in chemotherapy but its cardiotoxicity is the most important side effect that limits the clinical use of this drug. We investigated DOX treatment and the effects of vitamin D and melatonin on heart by electrocardiography, scintigraphic and biochemical methods.

Methods: In this study, forty-nine adult male Wistar albino rats (220 ± 15 g) were randomly divided into seven groups (n = 7 each), namely control (CON, n = 7), doxorubicin (DOX, n = 7), melatonin (MEL, n = 7), vitamin D (Vit D, n = 7), doxorubicin plus melatonin (DOX+MEL, n = 7), doxorubicin plus vitamin D (DOX+Vit D, n = 7), and doxorubicin plus melatonin and vitamin D (DOX+MEL+Vit D, n = 7) groups. Cardiotoxicity was induced by intraperitoneal injection (i.p.) of DOX (18 mg/kg, i.p.) on the 15th, 16th and 17th days. Rats receiving vitamin D and melatonin treatment in the DOX-induced cardiotoxicity group received vitamin D (60,000 IU/kg, i.p.) were administered in a single dose and melatonin (40 mg/kg/day, i.p.) for 17 days and were injected with (18 mg/kg, i.p.) on doxorubicin 15th, 16th, and 17th days. On the 18th day electrocardiography (ECG), ^{99m}Tc-pyrophosphate scintigraphy and biochemical parameters were assessed.

Results: DOX caused changes in the ECG pattern, a significant decrease in heartbeat ($p < 0.01$), P wave ($p < 0.001$) and QRS complex durations ($p < 0.001$), R wave amplitude ($p < 0.001$); elevation in ST-segment ($p < 0.001$) and decrease in QT interval ($p < 0.001$), and R-R interval durations ($p < 0.001$); increase in the serum levels of cardiac injury markers (CK, BUN, cardiac troponin T), ($p < 0.01$), and increased ^{99m}Tc-pyrophosphate uptake ($p < 0.001$) as compared to the CON group. MEL, Vit D and MEL+Vit D administration showed a same protective effect against DOX-induced altered ECG pattern. Pre-treatment with MEL, Vit D and MEL+Vit D significantly protected the heart from the toxic effect of DOX, by decreasing the levels of cardiac injury markers (CK, BUN, cardiac troponin T) ($p < 0.001$) and decreased the elevated level of ^{99m}Tc-pyrophosphate uptake ($p < 0.001$).

Conclusion: Vitamin D and melatonin treatment prevented all the parameters of DOX-induced cardiotoxicity in rats.

Keywords: doxorubicin-induced cardiotoxicity, vitamin D, melatonin, ^{99m}Tc-pyrophosphate

Received: March 27, 2018; Accepted: July 23, 2018; Published Online: September 12, 2018



Address for correspondence: Serdar Savaş Gül, MD., Gaziosmanpaşa University School of Medicine, Department of Nuclear Medicine, Tokat, Turkey
E-mail: opnukleertip@gmail.com

Copyright © 2019 by The Association of Health Research & Strategy
Available at <http://dergipark.org.tr/eurj>

Doxorubicin (DOX) is an anthracycline derivative antibiotic commonly used for the treatment of leukemias, malignant lymphoma and various solid tumors. However, its clinical use is limited because of dose-dependent cardiotoxicity [1]. DOX causes various toxic effects, the most common of which is cardiotoxicity that can be divided into acute effects (electrocardiogram changes), late effect of DOX administration is cardiomyopathy and congestive heart failure [2].

The pathogenesis of DOX-induced cardiotoxicity is acted by different mechanisms; thought that oxidative stress induced cell injury, lipid peroxidation, mitochondrial damage, inflammation, and apoptosis play a role. However, the most popular hypothesis is that it should be noted that DOX increased free radical production and oxidative stress, play a major role in DOX-induced cardiotoxicity [3]. Oxidative stress is characterized as an imbalance between antioxidant defense systems and reactive oxygen species. DOX-induced oxidative stress has been shown to be inhibited by the administration of certain antioxidants to experimental animals [2, 4, 5].

Melatonin as an important natural antioxidant, may reduce DOX-induced oxidative stress [6]. The protective effect of melatonin on cardiotoxicity induced by DOX has been demonstrated [2]. Ahmed *et al.* [7] demonstrated that treatment with melatonin could reduce DOX-induced cardiotoxicity by reduced oxidative stress and increased activity of the antioxidative enzymes.

Vitamin D (Vit D) plays regulatory activity in body function including the cardiovascular system. It is known that the pleiotropic effects of Vit D regulatory activation are responsible for the distribution of Vit D regulatory activity every where in the human body nervous system, intestine, kidney, bone, parathyroid gland, cardiovascular system and myocardium [8-10]. A lot of study has shown that Vit D deficiency is significantly associated with cardiovascular disease [11, 12]. Vit D deficiency leads to increase in serum parathyroid hormone (PTH) [13]. Increased PTH levels were reported to be associated with left ventricular hypertrophy and increased risk of heart failure [14]. In addition, treatment with Vit D decreased blood pressure in patients with hypertension and modified the heart failure, decrease in cardiovascular mortality [15-17].

Although many previous studies have examined the role of Vit D in cardiovascular disease, according to our knowledge none have studied with examined the effects of Vit D on DOX-induced cardiotoxicity. This study was conducted to investigate the potential protective effects of melatonin plus Vit D on DOX-induced cardiotoxicity manifested by changes in the ECG pattern, changes in biochemical parameters such as serum creatine kinase (CK), blood urea nitrogen (BUN), and cardiac troponin T (cTnT) and changes in ^{99m}Techneium pyrophosphate (^{99m}Tc PYP) scintigraphy. ^{99m}Tc PYP radiopharmaceuticals are involved in the necrotic tissue by binding to the calcium complex. It is routinely used in necrosis imaging in the nuclear medicine department. Additionally, our recent study has shown that combined melatonin plus Vit D treatment was superior to either one alone for protecting DOX-induced cardiotoxicity.

METHODS

Study Design

This is a randomized controlled experimental study.

Animal Selection

Forty-nine adult male Wistar albino rats (220 ± 15 g) were kept seven per cage, under standardized conditions of equal periods of light and dark in a room with lighting control (12-hour light/dark cycle, 24 ± 2°C) and had free access to food and water. All the experimental procedures were approved by the Animal Ethics Committee of Gaziosmanpaşa University.

Experimental Procedures

The animals were randomly divided into 7 groups of 7 rats in each:

Group 1: Rats received standard laboratory diet and drinking water ad libitum, and received normal saline 5 ml/kg body weight intraperitoneal (i.p.) and served as normal control (CON) groups.

Group 2: Rats were injected with a DOX at a cumulative dose of 18 mg/kg, i.p. at an interval of 24 h on the 15th, 16th and 17th days and served as the doxorubicin (DOX) group.

Group 3: Rats were injected melatonin at a dose of 40 mg/kg/day, i.p., (sigma, soluble in pure water) for 17

days and served as the melatonin (MEL) group.

Group 4: The first day of the experiment, rats were administered in a single dose of vitamin D (60.000 IU mg/kg, i.p.) and served as the vitamin D (Vit D) group.

Group 5: Rats received melatonin treatment (40 mg/kg/day, i.p., sigma, soluble in pure water) for 17 days and were injected with doxorubicin (cumulative dose: 18 mg/kg, i.p.) on the 15th, 16th and 17th days and served as the doxorubicin plus melatonin (DOX+MEL) group.

Group 6: The first day of the experiment, rats received a single dose of Vit D (60.000 IU mg/kg, i.p.) and were injected with doxorubicin (cumulative dose: 18 mg/kg, i.p.) on the 15th, 16th and 17th days and served as the doxorubicin plus vitamin D (DOX+Vit D) group.

Group 7: Rats received melatonin treatment (40 mg/kg/day, i.p., sigma, soluble in pure water) for 17 days and the first day of the experiment, rats received a single dose of vitamin D (60.000 IU mg/kg/i.p) and were injected with DOX (cumulative dose: 18 mg/kg, i.p.) on the 15th, 16th and 17th days and served as the doxorubicin plus melatonin and vitamin D (DOX+MEL+Vit D) group.

Electrocardiography

Anesthesia was assessed clinically by pedal reflex. Then, needle electrodes were inserted under the skin of the rats in lead II position. Electrocardiography (ECG) recordings were taken for 1 minutes using the acknowledge software (version 3.8) and the MP-150 multi-channel physiological analysis system (BioPac Systems Inc., USA). Changes in ECG pattern (amplitude of ST segment, R-amplitude, duration of P wave, QRS complex, QT interval, and R-R interval) were considered.

Biochemical Assays

At the end of the experimental period, all the rats were anesthetized under light anesthesia and blood was collected from the heart into Vacutainer serum-separated tubes. After 30 min, the tubes were centrifuged at 1500 × g for 10 min. Then, the clear serum was used for all following biochemical assays. CK, BUN, cTnT were estimated by kinetic determination using the commercial kits of Bechman by Bechman Coulter LX-2000 (Brea, CA, USA).

Scintigraphic Images

When experimental model 18th days, 1 mCi ^{99m}Tc PYP radiopharmaceutical was administered through i.p. in anesthetized rats. One hour after ^{99m}Tc PYP radiopharmaceutical administration, static imaging with dual head gamma camera (E-CAM, Siemens, Germany) was performed in anterior and posterior positions with 2.55 zoom factor. The radionuclide uptake heart area was measured by drawing equal rectangular regions of interest (ROI) and ^{99m}Tc PYP uptake was calculated by semi-quantitative method to the all study groups.

Statistical Analysis

Statistical analyses on each parameter were performed using SPSS 20.0 program. Comparison of the groups was made by one-way analysis of variance (ANOVA), followed by the post hoc Tukey test. Pearson correlation analysis revealed a significant correlation between the ^{99m}Tc PYP uptake ratio and serum levels of cardiac injury markers. The results are expressed as the means ± standard error of mean (SEM). For all statistical tests, *p* < 0.05 was considered statistically significant.

Table 1. Electrocardiographic parameters of the groups

Groups	Heart beat (bpm)	P wave duration (s)	QRS complex duration (s)	QT interval duration (s)	R-R interval (s)	R wave amplitude (mV)	ST segment amplitude (mV)
CON	280 ± 4	0.034 ± 0.01	0.060 ± 0.0	0.064 ± 0.01	0.145 ± 0.01	0.91 ± 0.2	0.054 ± 0.05
DOX	220 ± 3 ^c	0.022 ± 0.02 ^c	0.035 ± 0.0 ^c	0.086 ± 0.02 ^c	0.242 ± 0.01 ^c	0.52 ± 0.2 ^c	0.174 ± 0.06 ^c
MEL	279 ± 4	0.033 ± 0.02	0.057 ± 0.01	0.065 ± 0.02	0.154 ± 0.03	0.93 ± 0.2	0.055 ± 0.01
VITD	274 ± 2	0.035 ± 0.01	0.058 ± 0.01	0.064 ± 0.02	0.140 ± 0.01	0.92 ± 0.2	0.050 ± 0.02
DOX+MEL	251 ± 4 ^{b,e}	0.031 ± 0.01 ^f	0.057 ± 0.02 ^f	0.069 ± 0.03 ^f	0.158 ± 0.02 ^f	0.69 ± 0.2 ^{c,f}	0.059 ± 0.01 ^f
DOX+VITD	253 ± 5 ^{a,f}	0.035 ± 0.01 ^f	0.061 ± 0.01 ^f	0.071 ± 0.01 ^c	0.166 ± 0.01 ^f	0.73 ± 0.2 ^{c,f}	0.063 ± 0.01 ^f
DOX+VITD+MEL	250 ± 8 ^{b,e}	0.033 ± 0.0 ^f	0.060 ± 0.01 ^f	0.068 ± 0.01 ^f	0.142 ± 0.01 ^f	0.70 ± 0.2 ^{c,f}	0.057 ± 0.06 ^f

CON = control, DOX = doxorubicin, MEL = melatonin, Vit D = vitamin D, DOX+MEL = doxorubicin plus melatonin, DOX+Vit D = doxorubicin plus vitamin D, DOX+MEL+Vit D = doxorubicin plus melatonin and vitamin D

^a*p* < 0.05, ^b*p* < 0.01, ^c*p* < 0.001 all groups as compared to CON groups

^d*p* < 0.05, ^e*p* < 0.01, ^f*p* < 0.001 DOX+MEL, DOX+VIT D, DOX+VIT D+MEL groups as compared to DOX groups

RESULTS

Electrocardiography

The study show significant alteration of electrocardiographic patterns (duration of both P wave and QRS complex, QT interval, R-R interval, and heart rate, amplitude of ST-segment, R-wave amplitude) in DOX-administered rats as compared to normal control rats. CON group showed a normal pattern on ECG, whereas the DOX-treated group showed an decreased heart beat ($p < 0.01$), P wave ($p < 0.001$) and QRS complex durations ($p < 0.001$), R wave amplitude ($p < 0.001$); elevation in ST-segment ($p < 0.001$) and decrease in QT interval ($p < 0.001$), and R-R interval durations ($p < 0.001$) as compared to the CON group.

MEL pre-co-treatment in the DOX-treated group showed a decreased heart beat ($p < 0.01$) and R wave amplitude ($p < 0.001$), but did not show significant changes the other ECG parameters compared with the CON group. MEL pre-co-treatment in the DOX-treated group showed a increased heart beat ($p < 0.01$), P wave ($p < 0.001$), QRS complex durations ($p < 0.001$) and R wave amplitude ($p < 0.001$), decreased QT interval ($p < 0.001$), and R-R interval durations ($p < 0.001$), ST-segment-amplitude ($p < 0.001$) was significant when compared to the DOX alone-treated group.

Vit D pre-co-treatment in the DOX-treated group showed a decreased heart beat ($p < 0.05$) and R wave amplitude ($p < 0.001$), but did not show significant changes the other ECG parameters compared with the

Table 2. The statistical analysis of the cardiac marker enzyme levels

Groups	BUN	CK	cTnT
CON	17.11 ± 0.59	0.48 ± 0.1	3499 ± 244
DOX	183.77 ± 2.99 ^c	3.87 ± 0.13 ^c	10306 ± 366 ^c
MEL	16.31 ± 0.46	0.41 ± 0.01	2175 ± 34
ViTD	22.5 ± 0.98	0.40 ± 0.01	2376 ± 68
DOX+MEL	84.75 ± 14.41 ^{c, f}	1.64 ± 0.31 ^{c, f}	5673 ± 689 ^{c, f}
DOX+ViTD	126.56 ± 2.25 ^{c, f}	2.18 ± 0.41 ^{c, f}	7336 ± 641 ^{c, f}
DOX+ViTD+MEL	86.44 ± 18.84 ^{c, f}	2.11 ± 0.45 ^{c, f}	6089 ± 681 ^{c, f}

CON = control, DOX = doxorubicin, MEL = melatonin, Vit D = vitamin D, DOX+MEL = doxorubicin plus melatonin, DOX+Vit D = doxorubicin plus vitamin D, DOX+MEL+Vit D = doxorubicin plus melatonin and vitamin D, BUN = blood urea nitrogen, CK = creatine kinase, cTnT = cardiac troponin T
^a $p < 0.05$, ^b $p < 0.01$, ^c $p < 0.001$ all groups as compared to CON groups
^d $p < 0.05$, ^e $p < 0.01$, ^f $p < 0.001$ DOX+MEL, DOX+ViT D, DOX+Vit D+MELgroups as compared to DOX groups

Table 3. The statistical analysis of the scintigraphic data for the groups

Groups	Tc-99m PYP Uptake (cpm)
CON	52140 ± 559
DOX	279266 ± 684 ^c
MEL	53946 ± 987
ViTD	54646 ± 660
DOX+MEL	185793 ± 7073 ^{c, f}
DOX+ViTD	212600 ± 7550 ^{c, f}
DOX+ViTD+MEL	150431 ± 13843 ^{c, f}

CON = control, DOX = doxorubicin, MEL = melatonin, Vit D = vitamin D, DOX+MEL = doxorubicin plus melatonin, DOX+Vit D = doxorubicin plus vitamin D, DOX+MEL+Vit D = doxorubicin plus melatonin and vitamin D
^a $p < 0.05$, ^b $p < 0.01$, ^c $p < 0.001$ all groups as compared to CON groups
^d $p < 0.05$, ^e $p < 0.01$, ^f $p < 0.001$ DOX+MEL, DOX+ViT D, DOX+Vit D+MELgroups as compared to DOX groups

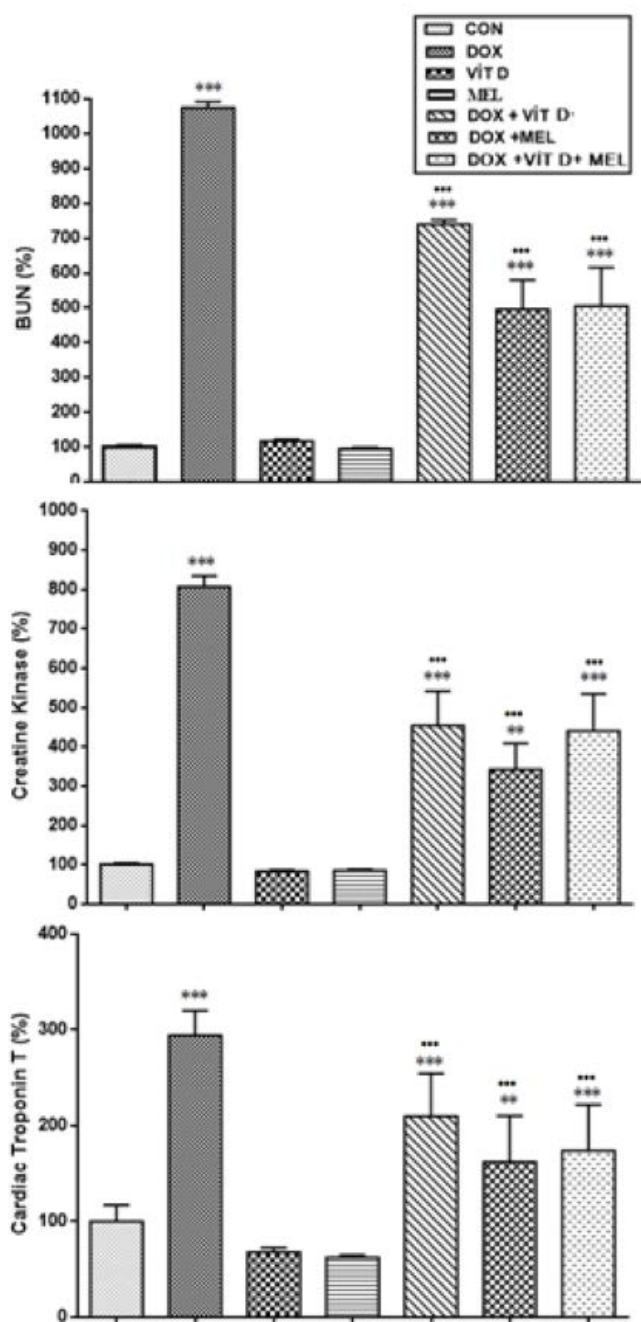


Figure 1. The effect of control (CON), doxorubicin (DOX), melatonin (MEL), vitamin D (Vit D), doxorubicin plus melatonin (DOX+MEL), doxorubicin plus vitamin D (DOX+Vit D), and doxorubicin plus melatonin and vitamin D (DOX+MEL+Vit D) groups pre-treatment on the effect of cardiac marker enzymes, blood urea nitrogen (BUN), creatine kinase and cardiac troponin T. The DOX, DOX+MEL, DOX+Vit D and DOX+Vit D+MEL groups significantly increased the BUN, creatine kinase, cardiac troponin compared to control group ($*p < 0.05$, $**p < 0.01$, $***p < 0.001$). Pre-treatment groups of DOX+MEL, DOX+Vit D and DOX+Vit D+MEL significantly decreased the BUN, creatine kinase, cardiac troponin compared to DOX group ($p < 0.05$, ($p < 0.01$), ($p < 0.001$).

control group. Vit D pre-co-treatment in the DOX-treated group showed a increased heart beat ($p < 0.01$), P wave ($p < 0.001$), QRS complex durations ($p < 0.001$) and R wave amplitude ($p < 0.001$), decreased QT interval ($p < 0.01$), and R-R interval durations ($p < 0.001$), ST-segment-amplitude ($p < 0.001$) was significant when compared to the DOX alone-treated group.

MEL+Vit D+DOX pre-co-treatment in the DOX-treated group showed a decreased heart beat ($p < 0.01$) and R wave amplitude ($p < 0.001$), but did not show significant changes the other ECG parameters compared with the CON group. MEL+Vit D+DOX pre-co-treatment in the DOX-treated group showed an increased heart beat ($p < 0.01$), P wave ($p < 0.001$), QRS complex durations ($p < 0.001$) and R wave amplitude ($p < 0.001$), decreased QT interval ($p < 0.01$) and R-R interval durations ($p < 0.001$), ST-segment-amplitude ($p < 0.001$) was significant when compared to the DOX alone-treated group (Table 1).

Biochemical Assays

DOX-treated group showed an increased BUN ($p < 0.001$), CK ($p < 0.001$, cTnT ($p < 0.001$) as compared to the CON group. MEL, Vit D, MEL+Vit D+DOX pre-co-treatment in the DOX-treated groups showed an increased BUN ($p < 0.001$), CK ($p < 0.001$, cTnT ($p < 0.001$) as compared to the CON group. MEL, Vit D, MEL+Vit D+DOX pre-co-treatment in the DOX-treated groups showed an decreased BUN ($p < 0.001$), CK ($p < 0.001$, cTnT ($p < 0.001$) were significant when compared to the DOX alone-treated group (Figure 1, Table 2).

Scintigraphic Images

^{99m}Tc PYP scintigraphy images of the all study groups are shown in Figure 2. DOX-treated group showed an increased ^{99m}Tc PYP uptakes compared to the CON group. MEL, Vit D, and DOX+MEL+Vit D pre-co-treatment in the DOX-treated groups showed an increased ^{99m}Tc PYP radiopharmaceutical uptake ($p < 0.001$) as compared to the CON group. MEL, Vit D, and DOX+MEL+Vit D pre-co-treatment in the DOX-treated groups showed an decreased ^{99m}Tc PYP uptake ($p < 0.001$) were significant when compared to the DOX alone-treated group (Figure 3, Table 3).

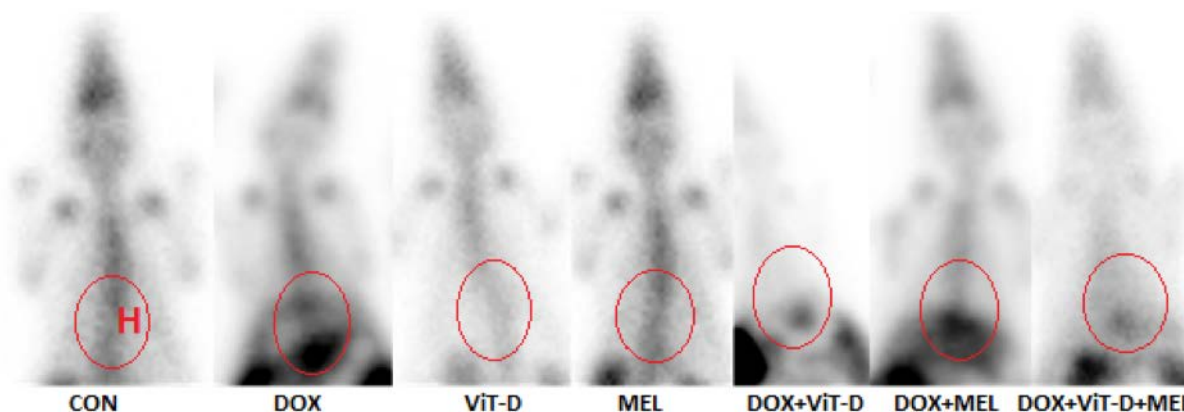


Figure 2. It is present that the ^{99m}Tc PYP scintigraphic images of the all control (CON), doxorubicin (DOX), melatonin (MEL), vitamin D (Vit D), doxorubicin plus melatonin (DOX+MEL), doxorubicin plus vitamin D (DOX+Vit D), and doxorubicin plus melatonin and vitamin D (DOX+MEL+Vit D) groups. The radiopharmaceutical uptake was calculated for each rat by drawing equal rectangular ROI at heart area (H).

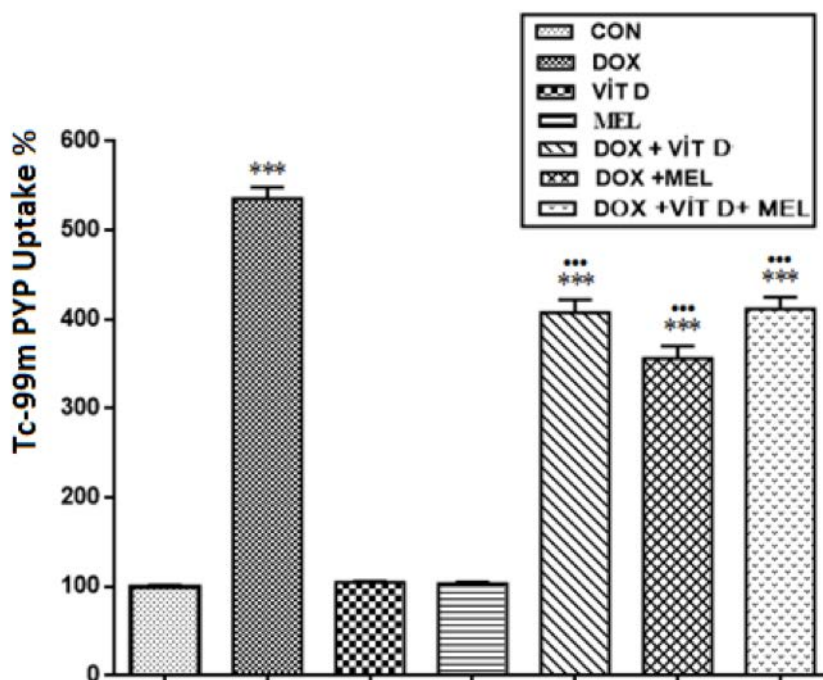


Figure 3. The effect of control (CON), doxorubicin (DOX), melatonin (MEL), vitamin D (Vit D), doxorubicin plus melatonin (DOX+MEL), doxorubicin plus vitamin D (DOX+Vit D), and doxorubicin plus melatonin and vitamin D (DOX+MEL+Vit D) groups on the effect of ^{99m}Tc PYP radiopharmaceutical uptake. The DOX, DOX+MEL, DOX+Vit D and DOX+Vit D+MEL groups significantly increased the the ^{99m}Tc PYP radiopharmaceutical uptake compared to control group (**p* < 0.05 ***p* < 0.01, ****p* < 0.001). Pre-treatment groups of DOX+MEL, DOX+Vit D and DOX+Vit D+MEL significantly decreased the the ^{99m}Tc PYP radiopharmaceutical uptake compared to DOX group (*p* < 0.05, (*p* < 0.01), (*p* < 0.001).

DISCUSSION

Previous studies demonstrated that DOX treatment-induced ECG abnormalities, which consist of non-specific P wave changes, sinus tachycardia, QRS complex, RR interval and R amplitude are frequently

transient and cannot be said to be specific to anthracyclines. Prolonged QTc interval and elevation ST segment amplitude have been reported to be relatively characteristic ECG findings in receiving anthracyclines. The consecutive loss of cellular membrane damage due to oxidative stress might be

characterized by ST elevation and prolonged QTc interval [18-21].

Our results confirmed that a cumulative dose of DOX (18 mg/kg) induces cardiotoxicity in rats as evidenced by ECG changes, ^{99m}Tc PYP scintigraphic images and increased levels of cardiac biomarker enzymes. In the present study MEL and Vit D treated rats demonstrates several major findings regarding the effects of DOX-induced cardiotoxicity. First, we found that all of the ECG parameters changed significantly in the DOX-treated group as compared to the CON group, but MEL and Vit D restored the changes in ECG parameters in the DOX group to the pattern of the CON group. Second, cardiac marker enzymes (BUN, CK, cTnT) of the DOX-treated group increased significantly when compared with the CON group, whereas MEL and Vit D treatment could be attributed in part to the suppression of DOX-induced elevation in the levels of these cardiac marker enzymes. Third, ^{99m}Tc PYP scintigraphic images of the DOX-treated group was significantly changed as compared to the CON group, but MEL and Vit D treatment restored the changes in ^{99m}Tc PYP scintigraphic images of the DOX group to the compared of the CON group.

In this study, ECG after DOX administration showed significant changes. DOX treatment induces a decrease P wave, QRS complex, in the amplitude of R wave, an increase in QT interval, R-R interval and ST segment which may link to its degenerative effect on cell membrane [22, 23]. Treatment with MEL, Vit D and combination MEL and Vit D groups caused increased in P-wave, QRS complex, R amplitude and decreased QT interval, R-R interval, ST segment was also near to normal. These changes in the electrocardiogram pattern induced by MEL and Vitamin D may be due to its membrane stabilizing action.

One of the major toxic effects of DOX is inducing lipid peroxidation. Its activation leads to acute membrane damage and releasing of cellular enzymes which decreased supply of oxygen to the myocardial cell leading to hypoxia [24-26]. The degree of DOX-induced cardiotoxicity can be estimated in serum and used as biomarkers to check the damage caused to the myocardium [27]. Several investigators reported that DOX causes elevation in the levels of CK-MB, BUN and cTnT serum biomarker activities after DOX administration [28, 29]. In comparison to the CON

group, the DOX-treated group showed significant elevation in the levels of cardiac marker enzymes in the serum. Treatment with MEL and Vit D caused a significant decrease in the levels of troponin T, BUN and CK-MB enzymes. This effect shows that MEL and Vit D can be prevent damage to the rat myocardium and stabilized the membrane.

As phosphorous compounds have high affinity for hydroxyapatite crystals, ^{99m}Tc PYP scintigraphy has been widely used in the detection of bone tumors and metabolic bone diseases. ^{99m}Tc PYP radiopharmaceutical accumulates predominantly as apatite-like crystals in mitochondria and cytoplasm of infarcted myocardial cells. Therefore, it has been considered beneficial in the diagnosis of acute phase myocardial infarction and quantification of the infarct size in the clinical setting [30-33]. Previous studies have also suggested that the degree of radiopharmaceutical accumulation such as ^{99m}Tc-labeled phosphonates, and ^{99m}Tc PYP is a good index of the severity of tissue damage [34-38]. In the present study, we observed increased ^{99m}Tc PYP radiopharmaceutical uptake on heart area in the DOX-induced cardiotoxicity rat model.

Limitations

This study was conducted to investigate the potential protective effects of melatonin plus Vit D on DOX-induced cardiotoxicity manifested by changes in the ECG pattern, changes in biochemical parameters and changes in ^{99m}Tc PYP scintigraphy. Histopathological examination was not performed in this study.

CONCLUSION

The results of the present study revealed that subchronic and systemic administration of Vit D doses showed a considerable cardioprotective effect similar to MEL on DOX-induced cardiotoxicity in rat model. MEL is an antioxidant agent that prevents apoptosis in in experimental toxic animal models. Cardiotoxicity induced by DOX ECG findings are very variable and chemical biomarkers alone are not sufficient, therefore additional diagnostic methods are needed. As a result of the study, it was thought that MEL and Vit D administration may be effective in preventing DOX-

induced cardiotoxicity and that ^{99m}Tc PYP scintigraphy could be used in the follow-up of chemotherapy patients using DOX.

Authorship declaration

All authors listed meet the authorship criteria according to the latest guidelines of the International Committee of Medical Journal Editors, and all authors are in agreement with the manuscript.

Conflict of interest

The authors disclosed no conflict of interest during the preparation or publication of this manuscript.

Financing

The authors disclosed that they did not receive any grant during conduction or writing of this study.

REFERENCES

- [1] Lefrak EA, Pitha J, Rosenheim S, Gottlieb JA. A clinicopathologic analysis of adriamycin cardiotoxicity. *Cancer* 1973;32:302-14.
- [2] Bilginoğlu A, Aydın D, Ozsoy S, Aygün H. Protective effect of melatonin on adriamycin-induced cardiotoxicity in rats. *Turk Kardiyol Dern Ars* 2014;42:265-73.
- [3] Swamy AH, Wangikar U, Koti BC, Thippeswamy AH, Ronad PM, Manjula DV. Cardioprotective effect of ascorbic acid on doxorubicin-induced myocardial toxicity in rats. *Indian J Pharmacol* 2011;43:507-11.
- [4] Anjos Ferreira AL, Russell RM, Rocha N, Placido Ladeira MS, Favero Salvadori DM, Oliveira Nascimento MC, et al. Effect of lycopene on doxorubicin-induced cardiotoxicity: an echocardiographic, histological and morphometrical assessment. *Basic Clin Pharmacol Toxicol* 2007;101:16-24.
- [5] Xin Y, Zhang S, Gu L, Liu S, Gao H, You Z, et al. Electrocardiographic and biochemical evidence for the cardioprotective effect of antioxidants in acute doxorubicin-induced cardiotoxicity in the beagle dogs. *Biol Pharm Bull* 2011;34:1523-6.
- [6] Othman AI, El-Missiry MA, Amer MA, Arafa M. Melatonin controls oxidative stress and modulates iron, ferritin, and transferrin levels in adriamycin treated rats. *Life Sci* 2008;83:563-8.
- [7] Ahmed HH, Mannaa F, Elmegeed GA, Doss SH. Cardioprotective activity of melatonin and its novel synthesized derivatives on doxorubicin-induced cardiotoxicity. *Bioorg Med Chem* 2005;13:1847-57.
- [8] Prufer K, Veenstra TD, Jirikowski GF, Kumar R. Distribution of 1,25-dihydroxyvitamin D3 receptor immunoreactivity in the rat brain and spinal cord. *J Chem Immunol* 1999;16:135-45.
- [9] Langub MC, Herman JP, Malluche HH, Koszewski NJ. Evidence of functional vitamin D receptors in rat hippocampus. *Neuroscience* 2001;104:49-56.
- [10] Walbert T, Jirikowski GF, Prufer K. Distribution of 1,25-dihydroxyvitamin D3 receptor immunoreactivity in the limbic system. *Horm Metab Res* 2001;33:525-31.
- [11] Kunadian V, Ford GA, Bawamia B, Qiu W, Manson JE. Vitamin D deficiency and coronary artery disease: a review of the evidence. *Am Heart J* 2014;167:283-91.
- [12] Majumdar V, Prabhakar P, Kulkarni GB, Christopher R. Vitamin D status, hypertension and ischemic stroke: a clinical perspective. *J Hum Hypertens* 2015;29: 669-74.
- [13] Holick MF, Binkley NC, Bischoff-Ferrari HA, Gordon CM, Hanley DA, Heaney RP, et al. Guidelines for preventing and treating vitamin D deficiency and insufficiency revisited. *J Clin Endocrinol Metab* 2012;97:1153-8.
- [14] Bansal N, Zelnick L, Robinson-Cohen C, Hoofnagle AN, Ix JH, Lima JA, et al. Serum parathyroid hormone and 25-hydroxyvitamin D concentrations and risk of incident heart failure: the Multi-Ethnic Study of Atherosclerosis. *J Am Heart Assoc* 2014;3:e001278.
- [15] Park CW, Oh YS, Shin YS, Kim CM, Kim YS, Kim SY, et al. Intravenous calcitriol regresses myocardial hypertrophy in hemodialysis patients with secondary hyperparathyroidism. *Am J Kidney Dis* 1999;33:73-81.
- [16] Shoji T, Shinohara K, Kimoto E, Emoto M, Tahara H, Koyama H, et al. Lower risk for cardiovascular mortality in oral 1-alpha-hydroxy vitamin D3 users in a haemodialysis population. *Nephrol Dial Transplant* 2004;19:179-84.
- [17] Nemerovski CW, Dorsch MP, Simpson RU, Bone HG, Aaronson KD, Bleske BE. Vitamin D and cardiovascular disease. *Pharmacotherapy* 2009;29:691-708.
- [18] Suzuki J, Yanagisawa A, Shigeyama T, Tsubota J, Yasumura T, Shimoyama K, et al. Early detection of anthracycline-induced cardiotoxicity by radionuclide angiocardiology. *Angiology* 1999;50:37-45.
- [19] Kelishomi RB, Ejtemaemehr S, Tavangar SM, Rahimian R, Mobarakeh JI, Dehpour AR. Morphine is protective against doxorubicin-induced cardiotoxicity in rat. *Toxicology* 2008;243:96-104.
- [20] Koti BC, Nagathan S, Vishwanathswamy A, Gadad PC, Thippeswamy A. Cardioprotective effect of Vedic Guard against doxorubicin-induced cardiotoxicity in rats: A biochemical, electrocardiographic, and histopathological study. *Pharmacogn Mag* 2013;9:176-81.
- [21] Bhatt L, Joshi V. *Mangifera indica* L. leaf extract alleviates doxorubicin induced cardiac stress. *J Intercult Ethnopharmacol* 2017;6:284-9.
- [22] Rossi F, Filippelli W, Russo S, Filippelli A, Berrino L. Cardiotoxicity of doxorubicin: Effects of drugs inhibiting the release of vasoactive substances. *Pharmacol Toxicol* 1994;75:99-107.
- [23] Holland RP, Brooks H. TQ-ST segment mapping: Critical review and analysis of current concepts. *Am J Cardiol* 1977;40:110-29.
- [24] Villani F, Monti E, Piccinini F, Favalli L, Lanza E, Rozza

- Dionigi A, et al. Relationship between doxorubicin-induced ECG changes and myocardial alterations in rats. *Tumori* 1986;72:323-9.
- [25] Fujita T. Formation and removal of reactive oxygen species, lipid peroxides and free radicals, and their biological effects. *Yakugaku Zasshi* 2002;122:203-18.
- [26] Zhang YW, Shi J, Li YJ, Wei L. Cardiomyocyte death in doxorubicin-induced cardiotoxicity. *Arch Immunol Ther Exp (Warsz)* 2009;57:435-45.
- [27] Christenson ES, James T, Agrawal V, Park BH. Use of biomarkers for the assessment of chemotherapy-induced cardiac toxicity. *Clin Biochem* 2015;48:223-35.
- [28] Ozdoğan K, Taşkın E, Dursun N. Protective effect of carnosine on adriamycin-induced oxidative heart damage in rats. *Anadolu Kardiyol Derg* 2011;11:3-10.
- [29] Momin F, Shikalgar T, Naikwade N, Kalai B. Cardioprotective effect of methanolic extract of *Ixora coccinea* Linn. leaves on doxorubicin-induced cardiac toxicity in rats. *Indian J Pharmacol* 2012;44:178-83.
- [30] Okuda K, Nohara R, Fujita M, Tamaki N, Konishi J, Sasayama S. Technetium-99m-pyrophosphate uptake as an indicator of myocardial injury without infarct. *J Nucl Med* 1994;35:1366-70.
- [31] Okuda K, Nohara R, Ogino M, Tamaki N, Konishi J, Fujita M, et al. Limitation of infarct size with preconditioning and calcium antagonist (diltiazem): difference in 99mTc-PYP uptake in the myocardium. *Ann Nucl Med* 1996;10:201-9.
- [32] Kawano M, Taki J, Kinuya S, Higuchi T, Nakajima K, Miyazaki Y, et al. Improvement of 99mTc-pyrophosphate scintigraphy in detection of acute myocardial infarction: combined with 99mTc-tetrofosmin. *Kaku Igaku* 2001;38:707-13.
- [33] Mochizuki T, Murase K, Higashino H, Miyagawa M, Sugawara Y, Kikuchi T, et al. Ischemic "memory image" in acute myocardial infarction of 123I-BMIPP after reperfusion therapy: a comparison with 99mTc-pyrophosphate and 201Tl dual-isotope SPECT. *Ann Nucl Med* 2002;16:563-8.
- [34] Affleck DG, Edelman L, Morris SE, Saffle JR. Assessment of tissue viability in complex extremity injuries: utility of the pyrophosphate nuclear scan. *J Trauma* 2001;50:263-9.
- [35] Chang HR, Kao CH, Lian JD, Shu KH, Cheng CH, Wu MJ, et al. Evaluation of the severity of traumatic rhabdomyolysis using technetium-99m pyrophosphate scintigraphy. *Am J Nephrol* 2001;21:208-14.
- [36] Matthews KL, Aarsvold JN, Mintzer RA, Chen CT, Lee RC. Tc-99m pyrophosphate imaging of poloxamer-treated electroporated skeletal muscle in an in vivo rat model. *Burns* 2006;32:755-64.
- [37] Walker UA, Garve K, Brink I, Miehle N, Peter HH, Kelly T. 99mTechnetium pyrophosphate scintigraphy in the detection of skeletal muscle disease. *Clin Rheumatol* 2007;26:1119-22.
- [38] Çiftçi ÖD, Gül SS, Açıksarı K, Maman A, Çavuşoğlu T, Bademci R, et al. The diagnostic utility of scintigraphy in esophageal burn: a rat model. *J Surg Res* 2016;200:495-500.



This is an open access article distributed under the terms of Creative Commons Attribution-NonCommercial-NoDerivatives 4.0 International License.