

## Delayed encephalopathy after acute carbon monoxide poisoning

### *Akut karbonmonoksit zehirlenmesi sonrası gecikmiş ensefalopati*

Mehmet İbrahim Turan<sup>1</sup>, Atilla Çayır<sup>2</sup>, Haşım Olgun<sup>3</sup>

#### ABSTRACT

Carbon monoxide poisoning is a major cause of death following attempted suicide and accidental exposures. Although clinical presentation depends on the duration and the intensity of exposure, the assessment of the severity of intoxication is difficult. A small percentage of patients who show complete initial recovery may develop delayed neurological deficits. Delayed encephalopathy after acute carbon monoxide poisoning is a rare and poor prognosis neurologic disorders and there is no specific treatment. We present a case with early onset of delayed encephalopathy after acute carbon monoxide poisoning with typical cranial imaging findings in a child with atypical history and clinical presentation.

**Key words:** Carbon monoxide, intoxication, encephalopathy

#### INTRODUCTION

Delayed encephalopathy after acute carbon monoxide poisoning (DEACMP) is a group of neuropsychological disorders that occur days or weeks later after the disappearance of the symptoms of acute carbon monoxide (CO) poisoning [1,2]. In DEACMP the lucid interval before appearance of neurologic sequel varies from 2 to 40 days in adult patients. [1]. It has a poor prognosis and there is no a specific treatment [2]. Herein we present early onset of DEACMP with typical magnetic resonance imaging (MRI) findings following carbon monoxide poisoning in a child with atypical history and clinical presentation.

#### CASE REPORT

A 3.5 year-old boy was found unconscious on the tandoor, which is a traditional Turkish coal arger.

#### ÖZET

Karbon monoksit zehirlenmesi intihar girişimlerinin ve kaza ile maruz kalmaya bağlı ölümlerin önemli bir nedenidir. Klinik bulgular maruz kalma süresi ve yoğunluğuna bağlı olsa da, zehirlenme şiddetinin değerlendirilmesi zordur. Tam iyileşme gösteren hastaların küçük bir yüzdesinde gecikmiş nörolojik defisit gelişebilir. Akut karbon monoksit zehirlenmesi sonrasında gelişen gecikmiş ensefalopati nadir ve kötü prognozlu bir nörolojik bozukluktur ve spesifik bir tedavisi yoktur. Burada akut karbon monoksit zehirlenmesi sonrası erken başlangıçlı, tipik kraniyal görüntüleme bulguları ile birlikte atipik öykü ve klinikle gelen gecikmiş ensefalopatili bir olguyu sunuyoruz

**Anahtar kelimeler:** Karbon monoksit, intoksikasyon, ensefalopati

He was admitted with second-degree burns on upper and lower extremities. On further enquiry, it was revealed that he had fallen over the top of a tandoor and nobody knew for how long he had remained there. So the probability of CO poisoning was suspected. Biochemical tests including kidney function tests (urea, creatinine, sodium, potassium) and liver function tests were within normal limits. He was managed conservatively regarding CO poisoning and treated for his burns, in plastic surgery clinic. On the fourth day he had focal seizure and fell unconscious. The patient was transferred to pediatric intensive care unit. On neurological examination, his light reflex was nonreactive and he had spastic quadriparesis. Cranial MRI examination on the same day, revealed peculiar bilateral, symmetrical T2 hyper intensity in the basal ganglia, thalamus and subcortical white matter of the occipital lobes

<sup>1</sup> Department of Pediatric Neurology, Training and Educational Hospital, Diyarbakır, Turkey

<sup>2</sup> Department of Pediatric Endocrinology, Training and Educational Hospital, Erzurum, Turkey

<sup>3</sup> Department of Pediatric Cardiology, Atatürk University Faculty of Medicine, Erzurum, Turkey

**Yazışma Adresi /Correspondence:** Mehmet İbrahim Turan,

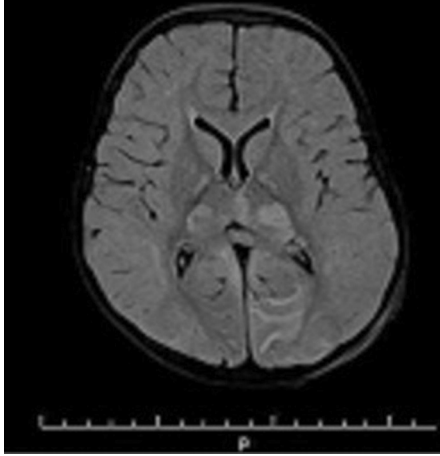
Department of Pediatric Neurology, Training and Educational Hospital, Diyarbakır, Turkey E-mail: turan78tr@hotmail.com

Geliş Tarihi / Received: 25.09.2013, Kabul Tarihi / Accepted: 13.10.2013

Copyright © Dicle Tıp Dergisi 2014, Her hakkı saklıdır / All rights reserved

(Figure 1). Seizures stopped after administration of antiepileptic therapy.

Since hyperbaric-oxygen therapy is unavailable in our center, he was followed with nasal oxygen support during his comatose state, which in turn made no change in his neurological status. Currently he is being followed by physical therapy program.



**Figure 1.** T2 weighted MRI image obtained four days after acute CO intoxication shows bilateral, symmetrical hyperintensity in the basal ganglia, thalamus, and subcortical white matter of the occipital lobes

## DISCUSSION

Prompt diagnosis of CO poisoning requires strong clinical suspicion and detailed patient history indicating duration of the exposure. There are many reasons that can cause CO poisoning. Delayed encephalopathy after acute carbon monoxide poisoning has a poor prognosis. In adult patients the lucid interval before appearance of neurologic sequelae varies from 2 to 40 days in DEACMP [3]. Kim et al reported that neurological symptoms which are preceded by a lucid interval of two to three weeks after

the recovery of the acute stage may be observed in delayed encephalopathy of carbon monoxide poisoning [4]. In present case, neurological signs appeared on the fourth day and the patient was transferred to the intensive care unit immediately.

The MRI neuroimaging findings in CO poisoning may be detected before appearance of clinical symptoms. MRI is a highly sensitive method to demonstrate the neuroimaging abnormalities after CO poisoning. Changes may visible as early as 1 hour post-exposure. Acute CO poisoning typically shows deep gray matter involvement, most commonly in the globus pallidii, putamen and thalami, occasionally with a hemorrhagic component [3]. In present case, MRI examination was performed as the neurological signs first appeared, and bilateral, symmetrical T2 hyper intensity in the basal ganglia, thalamus and subcortical white matter of the occipital lobes was observed.

Herein we would like to specify that CO poisoning should also be keep in mind in patients with burns. To our knowledge, this case is one of the pediatric case in the literature, presenting with the earliest clinical and neuroimaging findings of DEACMP.

## REFERENCES

1. Choi S. Delayed neurologic sequelae in carbon monoxide intoxication. *Arch Neurol* 1983;40:433-435.
2. Weaver LK. Carbon monoxide poisoning. *N Engl J Med* 2009;360:1217-1225.
3. O'Donnell P, Buxton PJ, Pitkin A, Jarvis LJ. The magnetic resonance imaging appearances of the brain in acute carbon monoxide poisoning. *Clin Radiol* 2000;55:273-280
4. Kim JH, Chang KH, Song IC, et al. Delayed encephalopathy of acute carbon monoxide intoxication: diffusivity of cerebral white matter lesions. *Am J Neuroradiol* 2003;24:1592-1597.