

A rare cause of dysphagia in a young man

Genç bir erkekte nadir bir yutma güçlüğü nedeni

Adnan Taş¹, Seyfettin Köklü²

¹Department of Gastroenterology, Osmaniye Public Hospital, Osmaniye, Turkey

²Department of Gastroenterology, Ankara Education and Research Hospital, Ankara, Turkey

Geliş Tarihi / Received: 27.07.2011, Kabul Tarihi / Accepted: 12.12.2011

Dear Editor

Gastrointestinal stromal tumors are the commonest mesenchymal tumors of the gastrointestinal tract. GIST account for only 1-4% of gastric tumours, 20% of small bowel tumours, and 1% of colorectal tumours. They have older than 50 years, with the median ages 60 years.¹ GIST is neoplasm of mesenchymal origin originating from precursors of the interstitial cells of cajal. The symptoms of gastrointestinal stromal tumor depend on the site and size of the tumor. We describe 30 age male with gastric cardia gastrointestinal stromal tumor presenting as dysphagia.

A 30-year-old male presented to the emergency department with dysphagia. The patient has dysphagia to solid and liquid food for the past four mounts. He also vomited digested food taken one week earlier. Physical examination, blood biochemistry and hematologic tests were within normal rates. The patient underwent upper gastrointestinal endoscopy observed approximately 3 cm mass at gastric cardia and presented a submucosal tumor with central umblicated two ulcers (Figure 1). Endoscopic ultrasonography showed a subepithelial lesion in the gastric cardia suggestive of a gastrointestinal stromal tumor (GIST). The patient underwent exploratory laparotomy. During surgery, a well-circumscribed lesion, measuring 5x4x3 cm was identified at the gastric cardia. The mass was resection completely. The patient had an uneventful postoperative course and was discharged on the five postoperative days. The histopathological examination of the resected lesion revealed a mesenchymal tumour categorized

as GIST tumour. The stromal tumour demonstrated whirling sheets of spindle cells with moderate level of phenomorphism and mitotic activity (5-8 mitoses/50 HPF) (H&E stain). No necrosis was observed.

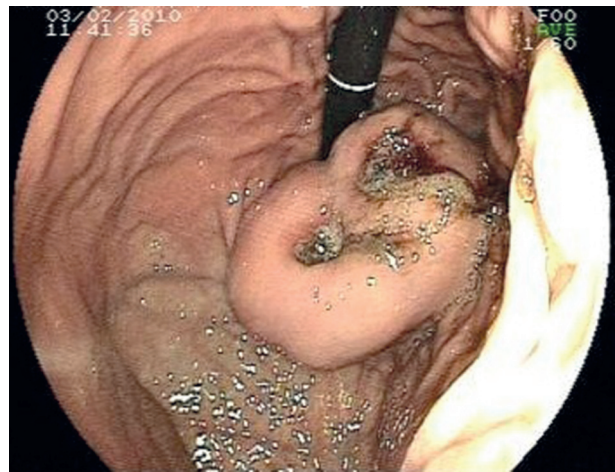


Figure 1. Endoscopic imaging showing gastrointestinal stromal tumor at gastric cardia.

The term GIST was introduced in 1983.² The majority of these tumours show identified mutations in cell-surface proteins called tyrosine kinase receptors. Most GIST show mutations in a gene that produces a growth factor receptor called KIT.¹ The most common presentation of GIST is acute or chronic gastrointestinal bleeding. They often present with nausea, vomiting, abdominal pain, metastatic diseases, and bowel obstruction. However, the symptoms depend on GIST location and size.³ In our case, the patient presented with dysphagia. In

Yazışma Adresi /Correspondence: Dr. Adnan Taş

Department Gastroenterology, Ankara Education and Research Hospital, Ankara, Turkey Email: dradnantas@gmail.com
Copyright © Dicle Tıp Dergisi 2012, Her hakkı saklıdır / All rights reserved

this reported case, GIST was diagnosed as a malignancy with moderate level of phenomorphism and mitotic activity while immunohistochemical staining for CD117, SMA, and S-100 protein was positive. Surgery is the standard treatment for localized primary disease without metastatic involvement.⁴ The treatment of choice is the complete resection of the tumour.

In conclusion, GIST is an uncommon type of dysphagia that is caused by gastric cardia intrinsic mechanical compression. It should be differentiated from other causes of dysphagia, such as gastroesophageal reflux disease, motility disorders or esophageal and stomach mass.

REFERENCES

1. Nishida T, Hirota S, Taniguchi M, et al. Familial gastrointestinal stromal tumours with germline mutation of the KIT gene. *Nat Genet* 1998;19(4):323-4.
2. Mazur MT, Clark HB. Gastric stromal tumors. Reappraisal of histogenesis. *Am J Surg Pathol* 1983;7(6):507-19.
3. DeMatteo RP, Lewis JJ, Leung D, Mudan SS, Woodruff JM, Brennan MF. Two hundred gastrointestinal stromal tumors: recurrence patterns and prognostic factors for survival. *Ann Surg* 2000; 231(1): 51-8.
4. Blay JY, Bonvalot S, Casali P, et al. GIST consensus meeting panelists. Consensus meeting for the management of gastrointestinal stromal tumors. *Ann Oncol* 2005; 16(4): 566-78.