

## Chronic venous insufficiency patterns in lower extremity veins detected by Doppler Ultrasound

### *Alt ekstremitede Doppler ultrasonografi ile tespit edilen kronik venöz yetmezlik tipleri*

Özhan Özgür, Emel Alimoğlu, Kağan Çeken, Ali Apaydın, Hakkı Timur Sindel

#### ABSTRACT

**Objective:** The aim of this study was to reveal patterns of chronic venous insufficiency of lower extremity detected by color Doppler ultrasound and clarify its clinical implications in the patients with varicose veins symptoms.

**Methods:** Between 2006 to 2011, a total of 2006 patients presented with symptoms of venous insufficiency were included in study. A total of 3938 lower extremity venous systems were examined using color Doppler US. We classified four patterns considering combinations of superficial and deep venous insufficiency.

**Results:** Of 2006 patients, 966 had either single venous insufficiency (790, 82%) or combined insufficiency (176, 18%). Superficial venous insufficiency was observed at the sapheno-femoral junction (SFJ) in 25.5%, at the Great Saphenous Vein (GSV) in 57.6%, at the Giacomini Vein in 2.4%, at the saphenopopliteal junction in 1.8% and finally at the Small Saphenous Vein (SSV) in 9.1% of the patients. We found multilevel venous insufficiency showing connections at the rate of 51%. We described four patterns as Pattern 1: SFJ insufficiency combined with GSV (97.9%), GSV branching (7.1%), and perforating vein (20.8%) insufficiency, Pattern 2: Deep venous insufficiency combined with SFJ (63.6%), GSV (76.4%), and SSV (16.4%) insufficiency, Pattern 3: SPJ insufficiency combined with SSV insufficiency (95.5%) and Pattern 4: Giacomini Vein insufficiency combined with GSV (67.9%) and SSV (75%) insufficiency.

**Conclusion:** Chronic venous insufficiency may show four different patterns. Our results revealed that SFJ and GSV insufficiency combination and deep venous insufficiency and GSV insufficiency combinations are the most common insufficiency patterns seen in lower extremity.

**Key words:** Doppler ultrasound, varicose veins, venous insufficiency

#### ÖZET

**Amaç:** Bu çalışmada, varis şikayeti olan hastalarda Doppler US ile alt ekstremitede tespit edilen kronik venöz yetmezliğinin paternlerinin ve klinik öneminin ortaya konması amaçlanmıştır.

**Yöntemler:** Venöz yetmezlik semptomu olan 2006 hasta çalışmaya dahil edilmiştir. Doppler US inceleme yapılan toplam 3938 alt ekstremitede venöz sistemi incelenmiştir. Araştırmada yüzeysel ve derin venöz yetmezlik kombinasyonu gösteren dört patern klasifiye edilmiştir.

**Sonuçlar:** İnceleme yapılan 2006 hastanın, 966'sında ya tek venöz yetmezlik seviyesi (790, %82) ya da yetmezlik kombinasyonu (176, %18) saptanmıştır. Yüzeysel venöz yetmezlik, %57,6 Vena Safena Manga (VSM), %25,5 safenofemoral bileşke (SFB), %9,1 Vena Safena Parva (VSP), %2,4 Giacomini Veni, %1,8 safenopopliteal bileşke (SPB) seviyesinde karşımıza çıkmıştır. Yetmezlik gösteren hastalar arasında %51 oranında çoklu seviye yetmezlik kombinasyonları saptanmıştır. Bu kombinasyonlar dört patern olarak açıklanmıştır. Patern 1: SFB ile VSM (%97,9), VSM'nin dallarının (%7,1) ve perforan venlerin (%20,8) birlikteliği. Patern 2: Derin venöz yetmezliğin, SFB (%63,6), VSM (%76,4), ve VSP (%16,4) ile kombinasyonu. Patern 3: SPB yetmezliğinin VSP (%95,5) ile birlikteliği. Patern 4: Giacomini Ven yetmezliğinin VSM (%67,9) ve VSP (%75) ile kombinasyonu.

**Tartışma:** Kronik venöz yetmezlik dört patern olarak karşımıza çıkabilir. Sonuçlarımız özellikle SFB ile VSM ve derin venöz sistem ile VSM yetmezlik birlikteliğinin çok sık olduğunu ortaya koymaktadır.

**Anahtar kelimeler:** Doppler ultrasonografi, variköz ven, venöz yetmezlik.

Akdeniz University, Faculty of Medicine, Department of Radiology, Antalya, Turkey

**Yazışma Adresi /Correspondence:** Özhan Özgür,

Akdeniz University, Faculty of Medicine, Department of Radiology, Antalya, Turkey Email: ozhanozgur@akdeniz.edu.tr

Geliş Tarihi / Received: 19.08.2013, Kabul Tarihi / Accepted: 04.09.2013

Copyright © Dicle Tıp Dergisi 2013, Her hakkı saklıdır / All rights reserved

## INTRODUCTION

Chronic venous insufficiency (CVI) and its associated varicose veins can induce physiological disorders, pain and cosmetic problems. The quality of life in the patients with CVI decreases even just because of these reasons over time. This disorder can only be treated by accurately determining the level of venous insufficiency that is the cause of the varicose veins. Venous valve insufficiency is the most common cause of venous insufficiency [1-3]. Evidence of valve failure can be observed as a stream of reflux on color Doppler ultrasound (US) [4]. An accurate assessment of the lower extremity venous system is only possible if color Doppler US is used to find the location of venous insufficiency. CVI may be seen in deep or superficial venous system. On the other hand, it is well known that deep venous insufficiency and superficial venous insufficiency may be coexistent. Moreover, the insufficiencies in different levels may be connected each other. To our knowledge, the most important step in diagnosing and treating CVI is to clarify, which vein or veins incompetent are and, what the anatomic levels of insufficiency are and which incompetent veins show a connection with each other. To date, no comprehensive study describing combinations of CVI on lower extremity exist in literature. Considering all of these mentioned above, we aimed to research the combinations of CVI together with its clinical importance by generating an anatomic map.

## METHODS

From February 2006 to June 2011, 2006 patients (654 males and 1352 females) with complaints or symptoms of varicose veins were examined by color Doppler US. All of the patients were in the age range of 14-88 years old (mean, 49); the male patients ranged from 17 to 87 years old (mean, 50), and the female patients ranged from 14 to 88 years old (mean age 48). Of 2006 patients undergoing Doppler US examinations, 74 had unilateral, 1932 had bilateral lower extremity examinations. 3938 lower extremities were examined using Doppler US. Color Doppler US is the method that most accurately reveals the cause of venous insufficiency and the gold standard for assessing venous reflux disease through non-invasive, anatomical, and functional methods [5,6]. US was performed using high-frequency broadband linear transducer

with central frequencies of 8 MHz connected to an Aplio 80 (Toshiba, Tokyo, Japan). We saved the US reports and images in our digital US database (Tomtec, version 2.7; Munich, Germany) between 2006 and 2011. The examinations were performed by two radiologists who had almost ten years of experience in venous Doppler US. Examination took about 15 minutes for each leg. Examination of lower extremity vascular system was performed considering superficial venous system (great saphenous vein (GSV), small saphenous vein (SSV)), the deep venous system, the pelvic venous system, saphenofemoral junction (SFJ), saphenopopliteal junction (SPJ), perforating veins, and the arterial system. In addition, the insufficiency of the superficial and deep venous systems that could be directly related to a patient's complaint of varicose veins were evaluated in terms of presence of their combinations. All of the pathological findings and levels were recorded separately. When we detected multilevel venous insufficiency, we also noted their connections by classified four patterns considering deep venous insufficiency, superficial venous insufficiency, perforating vein insufficiency: When GSV insufficiency, GSV branching, and perforating vein insufficiency at a high level are coexisted and connected with SFJ insufficiency, it is called as "Pattern 1". When deep venous insufficiency, SFJ, GSV and SSV insufficiencies are together and connected each other, we called as "Pattern 2". When SPJ insufficiency is connected with SSV insufficiency, we called as "Pattern 3". When Giacomini Vein insufficiency is together with both GSV and SSV insufficiencies at the same time and if they are connected, we called as "Pattern 4" (fig.1).

When we determined CVI, we also noted the presence of thrombosis. Since endovascular or surgical treatments are contraindicated for superficial system when the arterial insufficiency or deep venous thrombosis present, we performed detailed examination in terms of thrombosis in both arterial and venous system.

Firstly, the patients were examined in a supine position. We continued to examination in erect position for superficial venous system. The patient was requested to weight his/her body weight to the side of not being examined (fig. 2). In this way, by shifting one's body weight, a patient could relax the muscle of the leg being examined such that the pres-

ence of reflux could be detected [7]. The recognized retrograde reflux flow was one second or longer for the femoropopliteal region and 0.5 seconds or longer for the calf [7-10]. The diameter of veins ignored in this study. Since some of non-dilated veins could also show insufficiency. If varicose veins of pelvic origin were detected in the vulvar, vaginal, or proximal medial thigh region, the patients were recommended to have pelvic venography to assess the reflux level and plan the treatment.

Institutional review board approval was not obtained, because it was not required for retrospective studies at our institution until 2011. Statistical analysis was performed with Fisher's exact test and Pearson's chi-square method by using software (Statistical Package for Social Sciences, version 18, SPSS Inc., Chicago, Illinois, USA).

**RESULTS**

Of 2006 patients, 966 had CVI, of which 790 patients (82%) had single level insufficiency and 176 patients (18%) had multilevel insufficiency. Superficial venous insufficiency was observed at the sa-

phenofemoral junction (SFJ) in 25.5%, at the great saphenous vein (GSV) in 57.6%, at the communicating vein in 2.4%, at the saphenopopliteal junction (SPJ) in 1.8% and finally at the small saphenous vein (SSV) in 9.1% of the patients. Our results and frequencies of these patterns are summarized in Tables 1,2,3 and figure 1.

**Table 1.** Superficial venous insufficiency levels in the case group with a detected pathology

Finding	Male %	Female %	Total %
SFJ ins.	194 23.2	412 27	606 25.5
GSV ins.	514 61.6	858 56	1,372 57.6
Giacomini Vein ins.	16 2	42 2.7	58 2.4
SPJ ins.	20 2.4	24 1.5	44 1.8
SSV ins.	76 9	142 9.1	218 9.2
Pelvic ins.	14 1.7	68 4.4	82 3.4
Total	834 100	1,546 100	2,380 100

SFJ: Saphenofemoral Junction, ins.: insufficiency, GSV: Great Saphenous Vein, SPJ: Saphenopopliteal Junction, SSV: Small Saphenous Vein

**Table 2.** Statistical analysis of all cases examined using Doppler US

Deep Venous Insufficiency		Absent n (%)	Present n (%)	P
SFJ	Absent n	1,486 (78.4)	40 (36.4)	<0.05
	Present n	410 (21.6)	70 (63.6)	<0.05
GSV	Absent n	1,236 (65.2)	26 (23.6)	<0.05
	Present n	660 (34.8)	84 (76.4)	<0.05
SSV	Absent n	1,768 (93.2)	92 (83.6)	<0.05
	Present n	128 (6.8)	18 (16.4)	<0.05
SFJ		Absent n (%)	Present n (%)	P
GSV	Absent n	1,252 (82)	10 (2.1)	<0.05
	Present n	274 (18)	470 (97.9)	<0.05
GSV branch	Absent n	1,492 (97.8)	446 (92.9)	<0.05
	Present n	34 (2.2)	34 (7.1)	<0.05
GSV level perforans	Absent n	1,350 (88.5)	380 (79.2)	<0.05
	Present n	176 (11.5)	100 (20.8)	<0.05

SFJ: Saphenofemoral Junction, GSV: Great Saphenous Vein, SSV: Small Saphenous Vein

We found multilevel venous insufficiency which also showing connections at the rate of 51% (90/176). Of this showing connection, pattern 1 was shown in 28 patients (31%), pattern 2 in 12 (13%), pattern 3 in 42 (47%), pattern 4 in only 8 (9%).

In our study, the insufficiency finding was associated with the deep venous system in only 6% of the cases, whereas with the superficial venous system in 94% of the cases.

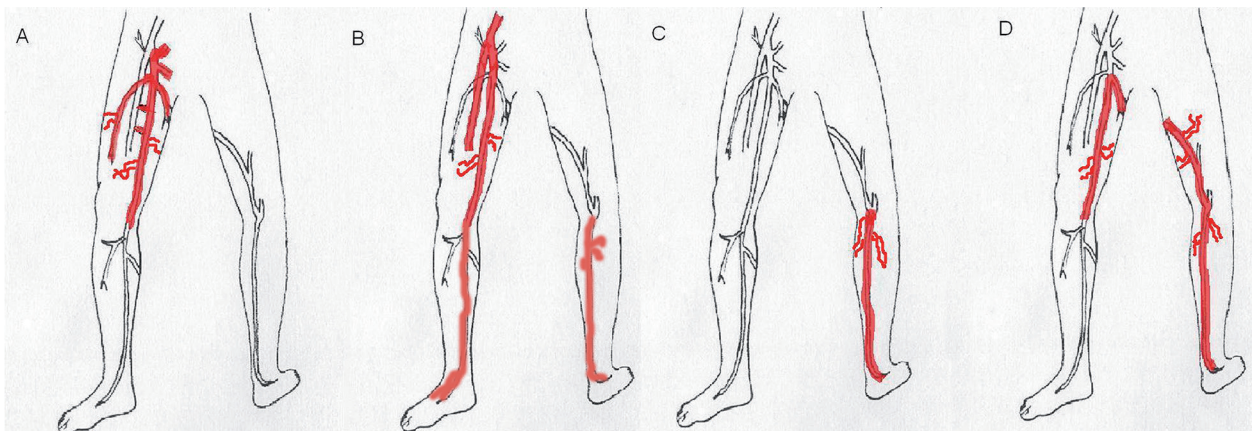
In pattern 1, our approach was laser therapy for insufficiency of GSV and its branches. If the branches of GSV are tortuous, we perform foam therapy. If

we detected recurrence in the branches of GSV during follow-ups, we applied foam therapy for them. In addition, we extended the period of ablation for the level of perforating veins insufficiency in pattern 2. In pattern 2, we preferred the laser therapy for GSV and SSV in addition to foam sclerotherapy for subcutaneous varicose veins. We performed laser therapy for SSJ and SSV in addition to foam therapy for subcutaneous varicose veins in pattern 3. Finally, we preferred laser therapy for GSV, Giacomini vein, SSV and foam therapy for subcutaneous varicose veins in pattern 4.

**Table 3.** Statistical analysis of all cases examined using Doppler US

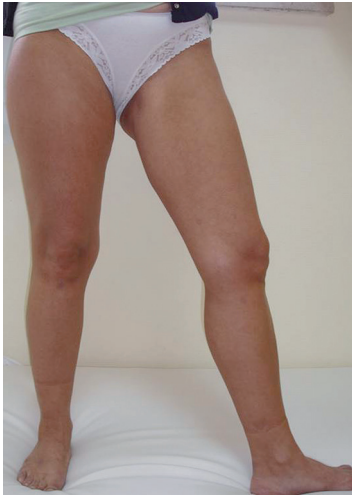SPJ			<i>Absent n (%)</i>	<i>Present n (%)</i>	<i>P</i>
SSV	Absent n	1,858 (94.7)	2 (4.5)	<0.05	
	Present n	104 (5.3)	42 (95.5)	<0.05	
Giacomini Vein			<i>Absent n (%)</i>	<i>Present n (%)</i>	<i>P</i>
GSV	Absent n	1,244 (63.8)	18 (32.1)	<0.05	
	Present n	706 (36.2)	38 (67.9)	<0.05	
SSV	Absent n	1,856 (93.3)	4 (25)	<0.05	
	Present n	134 (6.7)	12 (75)	<0.05	

SPJ: Saphenopopliteal Junction, SSV: Small Saphenous Vein, GSV: Great Saphenous Vein,



**Figure 1.** Patterns of chronic venous insufficiency that we detected; a: pattern 1, b: pattern 2, c: pattern 3, d: pattern 4





**Figure 2.** Position of patient during superficial venous system examination

## DISCUSSION

Patients with venous insufficiency may present with a variety of symptoms depending on their daily lifestyles. These symptoms include itching, fatigue, pain, and swelling. Such patients can present with symptoms that lead to venous ulcers. In turn, the ulcers can affect patients' quality of life because of the associated cosmetic problems [11-16]. Furthermore, a large number of patients visit the doctor with fears of developing bleeding varices, ulcers, or deep venous thrombosis (DVT) [17]. Conventional venography, which diagnoses DVT by examining a patient's lower extremity venous system and which was one of the most standard techniques in this area for many years, was replaced by highly efficient sonographic examinations in the 1980s [18,19]. However, few doctors in the US have applied sonographic examinations to analyze patients' deep venous systems because the use of conventional venography is highly ingrained in the US system.

Primary varicose veins occur in the superficial venous system secondary to venous insufficiency. Patients examined for varicose veins will undergo sonographic examinations of their lower extremity venous systems. Thus, these examinations will largely focus on their superficial venous systems. In our study, the insufficiency finding was associated with the deep venous system in only 6% of the cases, whereas with the superficial venous system in 94% of the cases. As it is seen, lower extremity venous insufficiency is composed of mainly superficial

venous system insufficiency. Unfortunately, until the early 2000s, many health center examinations of the lower extremity venous system by Doppler US were primarily limited to the deep venous system. Deep venous thrombosis and insufficiency constituted the basis for those exams. To our knowledge, deep or superficial venous examinations should be performed at the same time, because both will play an important role in the patient's diagnosis and future treatment. Secondary varicose veins associated with deep venous obstruction may be responsible for lower extremity varicose veins even if this type of insufficiency is not seen so frequently. In the case of deep venous obstruction, varicose veins may form, because these veins take on a collateral task. For this reason, this type of varicose veins is of high clinical importance. Varicose veins secondary to deep venous obstruction create a contraindication for surgical and endovenous treatment [9].

Varicose veins formation is particularly common in Western society, and the incidence of varicose veins increases with age [20]. In a large population screening performed in the United Kingdom, 40% of the men and 32% of the women were observed to have varicose veins formation [21]. The study presented in these paper-included patients who suffered from varicose veins. In this study, 51.1% of the men and 47.8% of the women were found to have venous insufficiency. This high ratio can be explained by the differences in the study groups.

The results in our study revealed four patterns that some deep or venous insufficiencies were showing communications between them. As known, venous I. could be single or multiple in different level at the same time. If radiologists depict a map, he or she would see multiple venous insufficiencies could show connections. Therefore, the approach of therapy will be changed at the first step of treatment or during follow-ups. We prefer the laser therapy, when truncal vein insufficiency existent. Our approach was laser therapy (for GSV and its branches insufficiency if not showing tortiosity) and foam therapy during follow-ups in addition laser therapy. We generated an anatomical mapping showing the anatomic levels of the venous insufficiency leading to varicose veins so that the most appropriate treatment approach could be chosen.

Our result could alert the physicians who examine the patients with varicose veins to diagnose correct insufficiency levels totally. Because the patients with deep venous insufficiency had SFJ, GSV, and SSV at high frequencies, it is particularly important to clarify whether the incidences of deep venous insufficiency were post-thrombotic. The secondary varicose veins that are associated with post-thrombotic syndrome are contraindicated for endovenous or surgical treatments. Among the cautionary signs for a physician assessing the levels of insufficiency, there are observations of GSV level insufficiency in patients with SFJ insufficiency, observations of SSV insufficiency in patients

With SPJ insufficiency, and observations of Giacomini's vein, GSV and SSV insufficiencies within the same patient. In our study, the results obtained from Doppler US examinations of the system segments of patients with varicose veins helped guide the physicians during their diagnoses. The results of our study, which revealed the statistical relationship for patients initially diagnosed with venous insufficiency, their the distribution of insufficiency findings across segments that shows patterns and the prevalence values, will both caution and enlighten the physicians who perform these examinations. At the same time, our findings will provide insights for future studies.

In conclusion, venous insufficiency is determined mainly in the form of superficial venous insufficiency in the lower extremity. Multilevel venous insufficiency is at the rate of 18%, of which the connection is seen very common up to 51%. We recommend to radiologist to keep in their mind this situation for the efficiency of treatment.

## REFERENCES

- Scurr JH, Tibbs DJ. Varicose veins and venous disorders. In: Tibbs DJ (ed) *Varicose veins, Venous disorders, and lymphatic problems in the lower limbs*. Oxford University Press, Oxford, 1997; 3-20.
- Sumner DS. *The hemodynamics and pathophysiology of venous diseases*. Vascular surgery. Philadelphia: WB Saunders 1977: 147-161.
- Agus GB, Allegra C, Antignani PL, et al. Guidelines for the diagnosis and treatment of chronic venous disorders. *International Angiology*; 2005;24:107-168.
- Cina A, Pedicelli A. Color-Doppler Sonography in Chronic Venous Insufficiency: What the Radiologist Should Know. *Curr Probl Diagn Radiol* 2005; 34:51-62.
- Campbell WB, Halim AS, Aertssen A, Ridler BM, Thompson JF, Niblett PG. The place of duplex scanning for varicose veins and common venous problems. *Ann R Coll Surg Engl*. 1996;78:490-493.
- Dixon PM. Duplex ultrasound in the pre-operative assessment of varicose veins. *Australas Radiol* 1996; 40:416-421.
- Yilmaz, S. Yeni tedaviler isiginda alt ekstremite yuzeyel venoz Doppler US incelemesi. *Turkrad* 2007;177-184.
- Thorisson HM, Pollak JS, Scoutt L. The role of ultrasound in the diagnosis and treatment of chronic venous insufficiency. *Ultrasound Quarterly* 2007;23:137-150.
- Min RJ, Khilnani NM, Golia P. Duplex Ultrasound Evaluation of Lower Extremity Venous Insufficiency, *J Vasc Interv Radiol* 2003;14:1233-1241.
- Labropoulos N. Definition of venous reflux in lower-extremity veins. *Journal of Vascular Surgery* 2003;38:793-798.
- Tibbs, D Sabiston, P Mortimer, M Davis. *Varicose Veins, Venous Disorders, and Lymphatic Problems in the Lower Limbs* DJ J Scurr Oxford University Press, USA 1997.
- Allegra C, Carlizza A. Oedema in chronic venous insufficiency: Pathophysiology and investigation. *Phlebology* 2000; 15:122-125.
- Tibbs DJ, Sabiston D, Mortimer P, et al. *Varicose Veins, Venous Disorders, and Lymphatic Problems in the Lower Limbs*, 1997 - Oxford University Press, USA.
- Sobaszek A, Frimat P, Tiberquient A, et al. Venous insufficiency of the lower limbs and working conditions. *Phlebology* 1998; 13:133-141.
- Bradbury A, Evans C, Allan P, et al. What are the symptoms of varicose veins? Edinburgh vein study cross sectional population survey. *BMJ* 1999; 318:353-356.
- Giuliano A *The Fundamentals Of Phlebology: Venous Disease for Clinicians 2<sup>nd</sup> edition*, London 2007.
- Campbell WB, Decaluwe H, MacIntyre J, et al. Most patients with varicose veins have fears or concerns about the future, in addition to their presenting symptoms. *Eur J Vasc Endovasc Surg* 2006; 31:332-334.
- Sindel T, Apaydin A, Soke B, Luleci E. Derin ven trombozu tanısında ultrasonografinin degeri, *Radyoloji ve Tibbi Goruntuleme Dergisi* 1992;2:95-99.
- Lewis BD. Diagnosis of acute deep venous thrombosis of the lower extremities: prospective evaluation of color doppler flow imaging versus venography. *Radiology* 1994;192:651-655.
- Evans CJ, Fowkes FG, Hajivassiliou CA, Harper DR & Ruckley V. Epidemiology of varicose veins. A review. *Int Angiol* 1994;13:263-270.
- Lee AJ, Evans CJ, Allan PL, et al. Lifestyle factors and the risk of varicose veins. *J Clin Epidemiol* 2003;56:171-179.