

CASE REPORT / OLGU SUNUMU

Primary stenting of an anomalous left main coronary artery originating from the right sinus of Valsalva during acute myocardial infarction

Akut miyokardiyal enfarktüsü esnasında sağ sinus Valsalva'dan köken alan anormal sol ana koroner artere primer stent uygulanması

Gökhan Çiçek¹, Servet Altay², Seçkin Satılmış³, Zekeriya Nurkalem³

ABSTRACT

Anomalous origin of left and right coronary arteries from a single coronary ostium in the right sinus of Valsalva is rare. Previously, few reports have described percutaneous coronary interventions (PCI) in this anomaly. We report a case of a 78-year-old female who had acute inferior myocardial infarction with a severe lesion in the anomalous left main coronary artery (LMCA) arising from a single ostium in the right sinus of Valsalva.

Key words: Coronary artery anomaly, single coronary artery, acute myocardial infarction, Primary PCI

ÖZET

Sağ Valsalva sinüsünden çıkan tek koroner arterden kaynaklanan anormal çıkışlı sol ve sağ koroner arterler oldukça nadirdir. Daha önceden böyle anomalili vakalarda, az sayıda perkütan koroner girişim (PKG) tanımlanmıştır. Biz akut inferior miyokart enfarktüsü, sağ Valsalva sinüsünden kaynaklanan ve ciddi lezyonu olan anormal sol ana koroner artere sahip 78 yaşında kadın vakayı bildiriyoruz.

Anahtar kelimeler: Koroner arter anomalisi, tek koroner arter, akut miyokard enfarktüsü, primer PKG

INTRODUCTION

Coronary artery anomalies are a diverse group of congenital disorders whose manifestations and pathophysiological mechanisms are highly variable. Although these anomalies and stenoses of anomalous vessels have been described previously, treatment of atherosclerotic lesions by primary percutaneous coronary intervention has rarely been reported.

CASE REPORT

A 78-year-old previously healthy female patient presented to emergency department with severe chest pain of 5 hours duration. In the emergency department ECG showed ST segment elevation in leads II, III, aVR and ST segment depression in leads I, aVL, and V2-V6 with isolated ventricular extra systoles

(Figure 1 A). On her physical examination blood pressure and heart rate were 100/65mmHg and 84bpm respectively. 300 mg aspirin was chewed and 600 mg clopidogrel was loaded. She was taken to cardiac catheterization laboratory for primary PCI. Coronary angiogram revealed that a single coronary artery (SCA) originated from the right sinus of Valsalva which gave right coronary and left main coronary arteries (LMCA). The anomalous LMCA then gave left anterior descending and tce Circumflex coronary artery branches. There was a 99% thrombotic stenosis in mid-LMCA (Figure 2A). The patient was consulted to cardiovascular surgery clinic and their decision was primary stenting rather than emergent coronary bypass surgery. The anomalous coronary artery was cannulated by a 6FAL3 guiding catheter. The lesion was passed by a 0.014 inch floppy wire and a 3x14 mm bare metal stent (BMS) was implanted at 14 atm. TIMI 3

¹ Ankara Numune Hastanesi Kardiyoloji AD, Ankara, Türkiye

² Edirne Devlet Hastanesi Kardiyoloji AD, Edirne, Türkiye

³ Siyami Ersek Hastanesi Kardiyoloji AD, İstanbul, Türkiye

Yazışma Adresi /Correspondence: Servet Altay,
Edirne Devlet Hastanesi Kardiyoloji AD, Edirne, Türkiye Email: svaltay@gmail.com

Geliş Tarihi / Received: 13.02.2015, Kabul Tarihi / Accepted: 18.03.2015

Copyright © Dicle Tıp Dergisi 2015, Her hakkı saklıdır / All rights reserved

flow was derived (Figure 2B). Chest pain and ECG changes had resolved. She transferred coronary care unit and intraaortic balloon counter pulsation was performed. One hour after the coronary intervention, chest pain repeated and the patient became hypotensive. On ECG, there were ST segment elevation in D1-aVL and ST segment depression in inferior leads and V5-V6 (Figure 1B). The patient

was taken to the catheter laboratory again. Coronary artery was cannulated by AL3 guiding catheter. The stent in LMCA was occluded (Figure 3A) The lesion was predilated with 2.5x15 mm balloon under 14 atm. Later 3x9 mm BMS was deployed (Figure 3B) and tirofiban infusion was started. Unfortunately, the patient died at third hospitalization day.

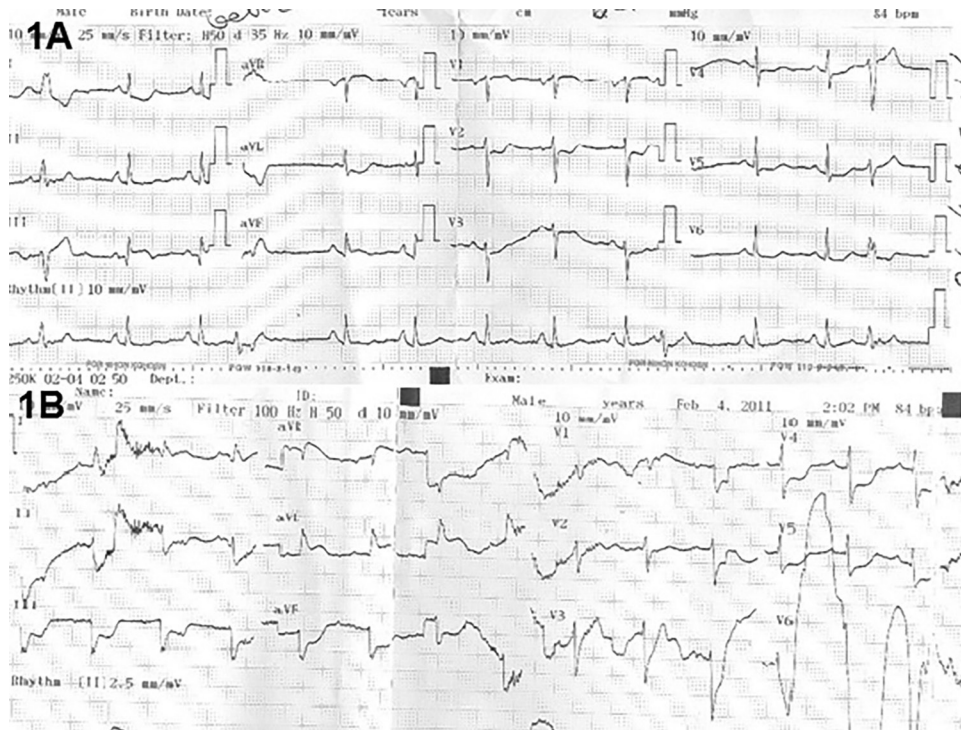


Figure 1A. First appeal ECG showing ST segment elevation in leads II, III, aVR and ST segment depression in leads I, aVL, and V2-V6 with isolated ventricular extrasystoles.

Figure 1B. In the intensive care unit, during recurrent ECG showing ST segment elevation in D1-aVL and ST segment depression in inferior leads and V5-V6

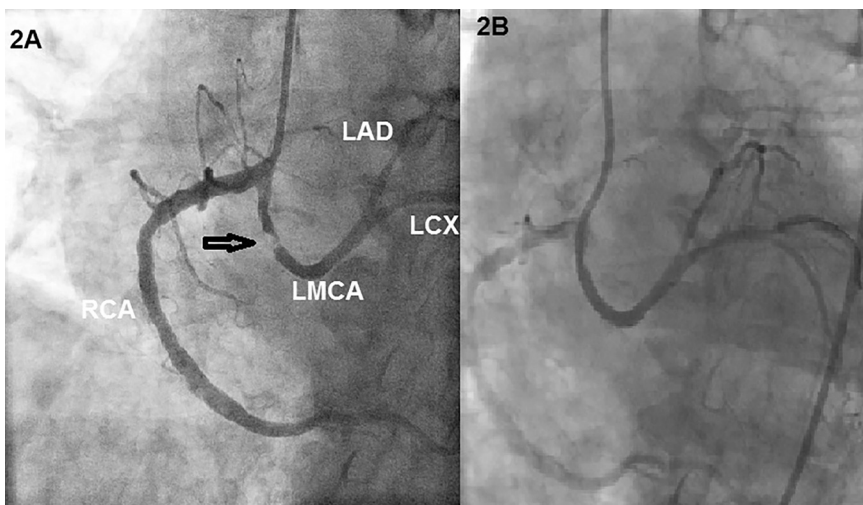


Figure 2A. Initial coronary angiogram revealed that a single coronary artery originated from the right sinus of Valsalva which gave right coronary and left main coronary arteries. The anomalous LMCA then gave LAD and Cx branches. There was a critical thrombotic stenosis in mid-LMCA.

Figure 2B. The LMCA after a direct stent implantation and the percutaneous transluminal coronary angioplasty.

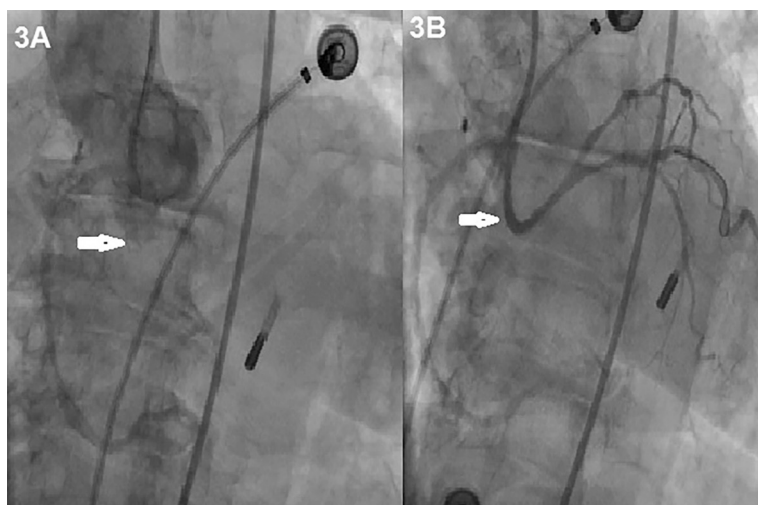


Figure 3A. Secondary coronary angiogram revealed that stent in LMCA was occluded.

Figure 3B. The occluded stent was pre-dilated with 2.5x15 mm balloon under 14 atm. Later 3x9 mm BMS was deployed

DISCUSSION

Single coronary artery is a very rare congenital abnormality characterized by a common origin of both the right and left coronary arteries from a single aortic ostium [1]. A SCA consists of 5-20% of major coronary artery anomalies and has an incidence of 0.024% in angiographic series [2]. Several classification systems for coronary artery abnormalities exist. Lipton et al. [3] classified coronary variations based on origin and anatomical course relating to the ascending aorta and pulmonary trunk.

The LMCA arising from the right sinus of Valsalva is a potentially serious coronary artery anomaly. The anomalous origin and proximal course of the LMCA from the right sinus of Valsalva may be associated with an increased risk of myocardial infarction and sudden death [4]. The anomalous origin of the LMCA has been investigated frequently because of reports linking this congenital anomaly with sudden death in young people [4-7]. In the present case, after its origin the main trunk divides into the right coronary artery and left main arteries, left anterior descending coronary artery, and circumflex artery. The SCA anomaly is usually asymptomatic, but may present as myocardial ischemia, syncope, or sudden cardiac death depending on its course and the presence and severity of atherosclerosis [8].

The literature contains variable reports. Porto et al showed that there is an increased risk of atherosclerosis in the case of a single coronary artery, which may result from acute-angle take-off mal-

formation [9]. Gleeson et al have reported a patient with SCA from the right aortic sinus of Valsalva who had significant lesions in right coronary arteries and was treated successfully by PCI [10]. Additionally, Özer et al. [11] and Şimşek et al. [12] have described PCI in this anomaly. Tortuous angle and unusual direction of the coronary artery may challenge percutaneous intervention. In addition, if a dissection occurs, it may expand retrogradely to involve the common SCA. The treatment of elderly patients with ST segment elevated myocardial infarction (STEMI) remains controversial.

Our case presented with STEMI and the patients was elderly too. Primary angioplasty in patients aged 75 years and over seems to be associated with low procedural complication, high procedural success, improved short and long term survival [13]. We report a rare case of a patient who had an anomaly of the left and right coronary arteries with a single coronary ostium in the right sinus of Valsalva, in which percutaneous coronary intervention was successfully performed in the LMCA. However, acute stent thrombosis developed after the procedure. Although we had a repeat revascularization procedure under resuscitation, the patient died. Coronary angioplasty with stenting may be a feasible therapeutic option for a single anomalous coronary artery. However, the operator should be aware of the potential risk of complications and the limitations of the procedure. Therefore we suggest coronary bypass surgery as an alternative treatment modality in acute coronary syndromes in the setting of SCA.

REFERENCES

1. Desmet W, Vanhaecke J, Vrolix M, et al. Isolated single coronary artery: a review of 50,000 consecutive coronary angiographies. *Eur Heart J* 1992; 13:1637-1640.
2. Kurşaklıoğlu H, İyisoy A, Köse S, et al. Sağ sinüs valsalvadan çıkan tek koroner arter (Olgu Sunumu). *Gülhane Tıp Dergisi* 2002; 44:442-443.
3. Lipton MJ, Barry WH, Obrez I, et al. Isolate single coronary artery: diagnosis, angiographic classification, and clinical significance. *Radiology* 1979; 130:39-47.
4. Cheitlin MD, De Castro CM and McAllister HA: Sudden death as a complication of anomalous left coronary origin from the anterior sinus of Valsalva, A not-so-minor congenital anomaly. *Circulation* 1974; 50:780-787.
5. Taylor AJ, Rogan KM and Virmani R. Sudden cardiac death associated with isolated congenital coronary artery anomalies. *J Am Coll Cardiol* 1992 20: 640-647.
6. Basso C, Maron BJ, Corrado D, et al. Clinical profile of congenital coronary artery anomalies with origin from the wrong aortic sinus leading to sudden death in young competitive athletes. *J Am Coll Cardiol* 2000;35:1493-1501.
7. Maron BJ, Gohman TE and Aeppli D. Prevalence of sudden cardiac death during competitive sports activities in Minnesota high school athletes. *J Am Coll Cardiol* 1998; 32:1881-1884.
8. Angelini P, Velasco JA, Flamm S. Department of adult cardiology, incidence, pathophysiology and clinical relevance. *Circulation* 2002; 105:2449-2454.
9. Porto I, Banning AP. Unstable angina in a patient with single coronary artery. *Heart* 2004;90:858.
10. Gleeson T, Thiessen R, Wood D, et al. Single coronary artery from the right aortic sinus of Valsalva with anomalous pre pulmonic course of the left coronary artery. *Can J Cardiol* 2009; 25:136-138.
11. Özer N, Tangürek B, Tartan Z, et al. A rare coronary anomaly detected during primary percutaneous coronary angioplasty: totally occluded left main coronary artery originating from the right coronary artery. *Türk Kardiyol Dern Ars* 2008; 36:184-186.
12. Şimşek H, Şahin M, İşlek M, et al. Anomaly of left main coronary artery arising from the right sinus of valsalva. *J Clin Exp Invest* 2011; 2:225-227.
13. Işık T, Uyarel H, Ergelen M, et al. Short and long term outcomes of primary angioplasty in patients aged 75 years and over. *Dicle Med J* 2011; 38:189-196.