

# **Resin Nano Ceramic Endocrown: An Alternative To Post-Core Supported Crowns**

**Işıl Kaya BÜYÜKBAYRAM<sup>1</sup>**  
**Gülce ALP<sup>2</sup>**

## **Abstract**

### **Background**

The longevity of an endodontic treatment largely depends on the selection of an appropriate restoration that is concerned with efforts to save the tooth structure. In this perspective, endocrowns can be considered as a feasible alternative for post-core restorations.

### **Objective**

To evaluate the clinical efficiency of CAD/CAM resin nano ceramic endocrowns in restoring posterior teeth.

### **Case description**

A 37-year-old man who reported a chief complaint of pain was referred for treatment. After clinical and radiographic examination: three endocrowns was planned for the rehabilitation of the teeth number 14, 25, 26. The endocrowns were scanned and designed by using CEREC 3D software and milled from a CAD/CAM resin nano ceramic block. At one-year follow-up, no cracks, caries or decementation of the endocrowns was seen.

### **Practical implications**

Endocrowns seems as a successful treatment technique as an alternative to post-core supported crowns in restoring the posterior teeth.

**Keywords:** *CAD/CAM, endocrown, resin nano ceramic, CEREC*

## **Rezin Nano Seramik Endokron: Post-Kor Destekli Kron Restorasyonlara Bir Alternatif**

### **Özet**

#### **Giriş**

Endodontik tedavili dişlerin uzun ömürlü olması, büyük oranda diş yapısının korunduğu uygun bir restorasyonun seçimine bağlıdır. Bu perspektifte, endokronlar post-kor restorasyonlara uygun bir alternatif olarak değerlendirilebilir.

<sup>1</sup> (DDS PhD) Istanbul Aydın University, Faculty of Dentistry, Department of Endodontics, Corresponding Author: [isilkayabuyukbayram@aydin.edu.tr](mailto:isilkayabuyukbayram@aydin.edu.tr)

<sup>2</sup> (DDS PhD) Istanbul Aydın University, Faculty of Dentistry, Department of Prostodontics

## **Amaç**

Arka grup dişlerde CAD/CAM rezin nanoseramik endokron restorasyonların klinik etkinliğinin değerlendirilmesi.

## **Olgu Raporu**

37 yaşındaki erkek hasta ağrı şikayet ile kliniğimize başvurmuştur. Klinik ve radyografik incelemeden sonra, 14, 25, 26 nolu dişlere 3 adet endokron planlanmıştır. Endokronlar CEREC 3D yazılımı kullanılarak taranıp dizayn edilmiş ve CAD/CAM rezin nanoseramik blok kullanılarak kazınmıştır. Bir yıllık takip sonucunda endokronlarda herhangi bir çatlak, çürük ve desimantasyon gözlenmemiştir.

## **Klinik bağlantı**

Endokronlar arka dişlerin restorasyonunda, post-kor destekli kron restorasyonlarına alternatif olarak başarılı bir tedavi tekniği olarak görülmektedir.

*Anahtar Kelimeler: CAD/CAM, endokron, rezin nano seramik, CEREC*

## **Introduction**

Endodontically treated teeth are considered to have a higher risk of fracture when compared to vital teeth. In the maintenance of long-term success, those teeth present specific challenges for the restorative dentists and the prosthodontists.<sup>1</sup>

Although there are a number of studies on endodontically treated teeth, there is no consensus about the optimal build-up design, treatment planning and the choice of material for the restoration.<sup>2</sup>

In the past a common protocol of restoring such teeth has been to build up the tooth with a post and core<sup>3</sup>, not only to retain the crown but also to recover the stiffness of the tooth.<sup>4</sup> Contrary to this preconceived idea, many clinical and laboratory studies have reported that placing a post will contribute to the retention of the core portion of the restoration<sup>3</sup> but they do not reinforce roots and may have a weakening effect on the root through loss of radicular dentin necessitated by post space preparation.<sup>5</sup>

Endocrowns, have been presented as an alternative to post-core supported crowns for restoration of non-vital posterior teeth regarding the advent of bonding systems, especially those which have sufficient tooth structure.<sup>6</sup>

Compared to conventional crowns, endocrowns' main advantage is that it is a more conservative approach, which preserves peripheral enamel and allows re-intervention in case of endodontic failure.<sup>4</sup> Endocrowns are easy to apply, low cost, short preparation time and less invasive preparation, minimal chair time and aesthetic properties are the other advantages of endocrowns.<sup>7</sup>

Additionally endocrowns can be made through computer-aided design/computer-aided manufacturing (CAD/CAM) technology by using a wide collection of ceramic materials. Although there is

a wide collection of ceramic materials has been available for CAD/CAM technology, most recently, a resin nano ceramic has been introduced for permanent CAD/CAM fabricated restorations.<sup>3</sup> On the other hand, the optimal material for endocrown restorations has been discussed and the issue remains controversial.<sup>3</sup>

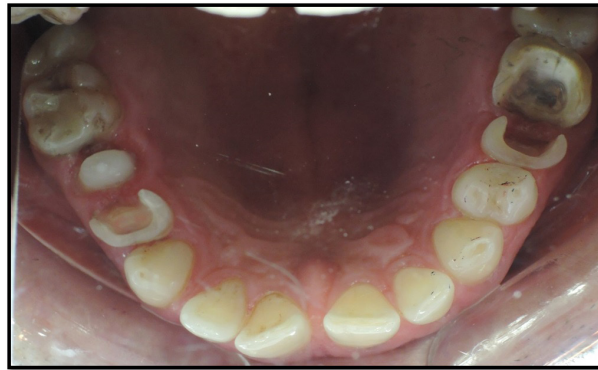With the intent of increasing the amount of information about endocrown application with resin nano ceramic, the aim of this study is to discuss the indication and use of the endocrown and present a clinical case report on the 1-year clinical follow-up of three endocrown restorations, fabricated from resin nano ceramic (Lava Ultimate™/3M ESPE) with CAD/CAM.

### Case Report

A 37-year-old male patient referred to the Department of Endodontics, Istanbul Aydın University with chief complaint of pain. Clinical and radiographic examinations revealed that maxillary right first premolar's palatal cusp was broken and teeth number 14, 25, 26 had secondary caries under large composite resin restorations. The treatment was planned in two stages including respectively endodontic and prosthodontic treatments.

According to first stage of the treatment plan, endodontic treatments were performed for the teeth number 14, 15, 25, 26. After one week waiting time all the teeth were asymptomatic. For the second stage of the treatment protocol, the teeth was examined for prosthodontic restorations. A conservative approach of restoring the teeth number 14, 25, 26 with an endocrown was decided as treatment option, as more than half the residual tooth structure was remaining and there were no occlusal wear facets. The tooth number 15 had palatal cusp fracture which was in 2mm depth subgingivally and a post-core supported full crown restoration was planned for this tooth.

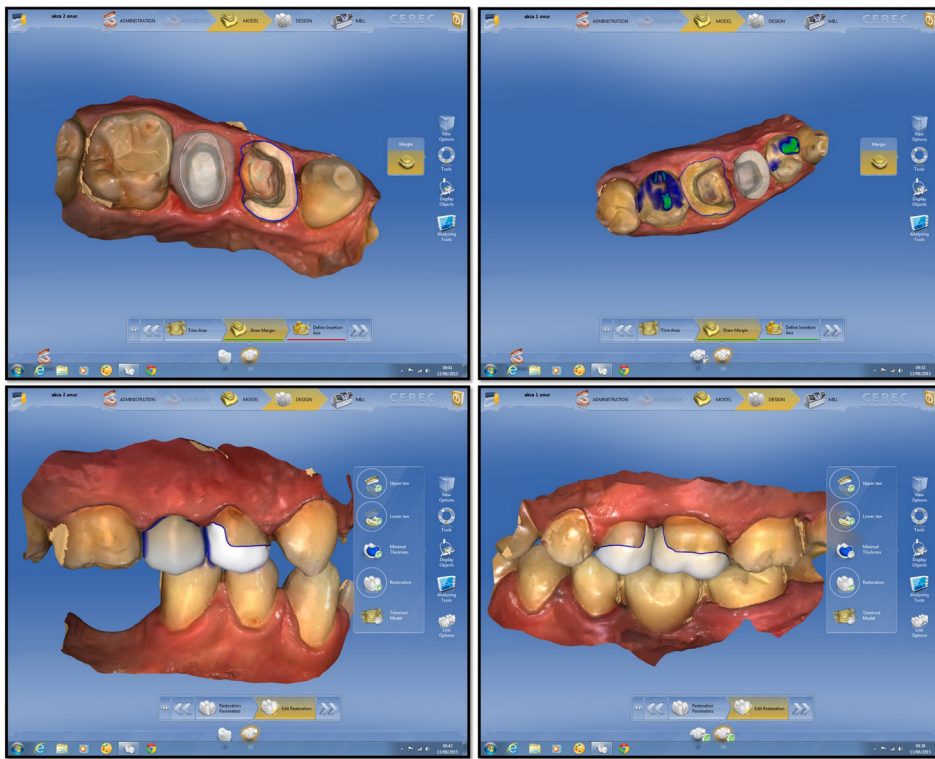
For endocrown preparations temporary filling restorations removed. The preparation consisted of a circular equigingival butt-joint margin and central retention cavity into the entire pulp chamber constructing both the crown and the core as a single unit (Figure 1). After cavity preparations, flowable composite (Filtek TM Bulk Fill Flowable Restorative, 3M ESPE GmbH, Neuss, Germany) were applied into the isolated cavities to eliminate the undercuts. The appropriate reduction of the buccal and lingual walls was done and interocclusal space was carefully evaluated. Occlusal reduction was done to achieve a clearance of 2 mm.



*Figure 1. Preparation of the teeth for endocrown.*

For full crown restoration, a glass fiber posts #1 (White Post, FGM, Joinville, SC, Brazil) was cemented using an adhesive system (Adper Single Bond, 3M ESPE) and dual resin cement (RelyX ARC, 3M ESPE) and a resin composite filling core was applied with increments of resin composite (Tetric N-Ceram, Ivoclar- Vivadent AG, Schaan, Liechtenstein). Following core build-up a chamfer finish line was applied for full crown restoration.

After the completion of preparations, digital impression and bite scans were performed using both side of the maxilla with an intra-oral scanner (CEREC Omnicam, Sirona Dental Systems GmbH, Bensheim, Germany). Then endocrowns and all-ceramic crown was designed (CEREC inLab version 4.2 version Sirona Dental Systems GmbH, Bensheim, Germany) (Figure 2) and shade-A2 was selected for all the crown restorations (VITAPAN Zahnfabrik, Germany).



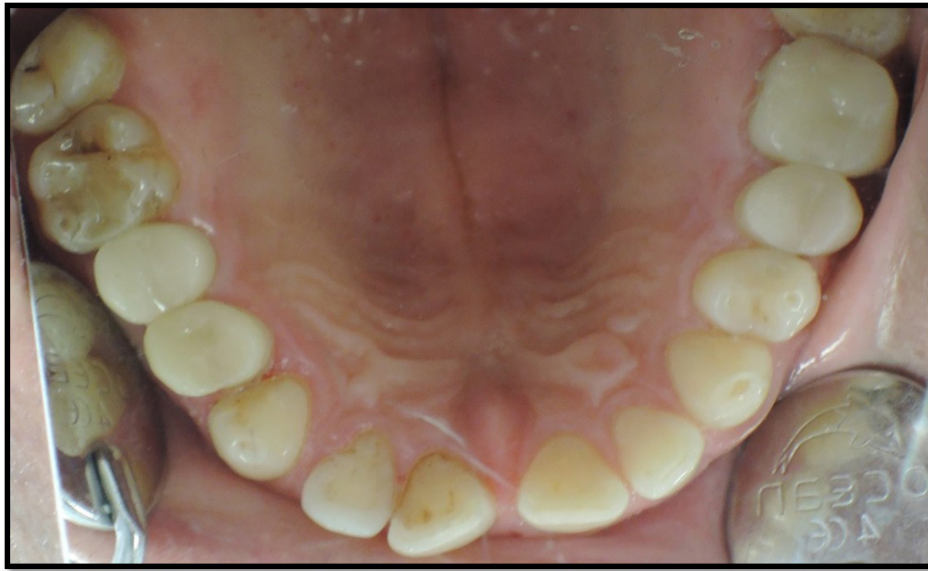**Figure 2.** CEREC views

Endocrowns were milled from a CAD/CAM composite resin nano ceramic blocks (LAVA Ultimate™, 3M ESPE, Neuss, Germany). All ceramic crown was milled from the feldspathic ceramic block (Sirona, CEREC blocks, Vita Zahnfabrik, Bad Sackingen, Germany). Before cementation, the marginal adaptation of the crowns was checked.

For endocrown cementation, intaglio surfaces of each endocrown were sandblasted with aluminium oxide (50m Cojet™, 3M ESPE Neuss, Germany) for 5 seconds and cleaned with alcohol and dried with oil-free, moisture-free air. Single-bond Universal™ adhesive (3M ESPE Neuss, Germany) were applied intaglio surfaces for 20 seconds and air-thinned. Prepared tooth surfaces were etched with 37% phosphoric acid-etching gel for 15 seconds, rinsed for 20 seconds, and

dried with oil-free air for another 5 seconds. Single-bond Universal™ adhesive (3M ESPE Neuss, Germany) was applied for 20 seconds and dried thoroughly for 5 seconds and polymerized by a LED light-curing lamp Bluephase (Ivoclar Vivadent AG, Schaan, Liechtenstein) for 10 seconds as recommended by manufacturer. All endocrowns were cemented with Rely X™ Ultimate resin cement (3M ESPE Neuss, Germany) under a constant load of finger pressure. Excess material was removed with the help of a microbrush and restoration margins were covered with a glycerine gel (Liquid Strip, Ivoclar Vivadent) to prevent oxygen inhibition of polymerization. The resin cement was light activated at each surface for 20 seconds using a LED light-curing lamp Bluephase (Ivoclar Vivadent AG, Schaan, Liechtenstein). Then, margins of the restorations were finished with sandpaper polishing discs (Sof-Lex, 3M ESPE). For all ceramic crown cementation a dual cure resin luting agent (Variolink, Ivoclar/Vivadent, Schaan/Liechtenstein) was used.

After cementation procedure, clinical and radiographic evaluation was done (Figure 3) and a one year follow up showed no secondary caries, fracture, discoloration or loosening/decementation of the crowns.



*Figure 3. Clinical view of the final restorations from occlusal aspect*

## Discussion

Endocrown restorations promote biomechanical integrity of the compromised structure of non-vital posterior teeth and appear to be a feasible option instead of post-core restorations for endodontically treated posterior teeth.<sup>8</sup>

Moreover, they appear to be a solution for teeth with a short clinical crown and atresic, calcified, curved, or short root canals that make it impossible to use posts.<sup>9</sup> The internal portion of the endocrown allows minimal tooth wear and thus strengthens the tooth, since it helps preserve root tissue and canal structures and limits internal preparation of the pulp chamber to its anatomic shape.<sup>10</sup>

Additionally when compared with traditional crowns supported on fiber posts, greater resistance to compression forces of endocrown restorations reported by Biacchi and Basting.<sup>8</sup>

Endocrowns also have clinical advantages. The clinical procedure that involves the fabrication of endocrown restorations, compared with the fabrication of crowns with cores or posts, may be considered less complex, more practical, and easier to perform<sup>8</sup> with the development of CAD/CAM systems and software. CAD/CAM fabricated endocrowns can be produced chairside and applied to the patient in one appointment.

Today different materials can be used to fabricate an endocrown like feldspathic and glass-ceramic, hybrid resin composite and the newest CAD/ CAM ceramic and resin composite blocks.<sup>3</sup>

In vitro fatigue tests showed that endocrowns made of more flexible composite resin or resin nano ceramic (RNC) materials may also have a great potential for this indication.<sup>5</sup>

Therefore in the presented case it was preferred to use resin nano ceramic blocks for endocrown restoration. Any esthetic and functional degradation was not seen during one year follow up. Lander and Dietschi evaluated a three-year follow-up of two Empress II endocrowns and stated satisfactory behavior in terms of esthetics, restoration stability, and tissue preservation which is similar to our results.<sup>6</sup>

The success and longevity of the endocrown are directly related to case selection and correct preparation of the tooth, the selection of the most suitable ceramic options, and the choice of bonding material and correct adhesive cementation.<sup>9</sup> It may be concluded that endocrowns fabricated using CAD/CAM and resin nano ceramic blocks are reliable restorative options for endodontically treated teeth with advantages in terms of mechanical performance, cost, and clinical time. Long-term follow up and clinical studies are needed to confirm their overall success.

### **Conflict of Interest**

The authors of this article certify that they have no proprietary, financial, or other personal interest of any nature or kind in any product, service, and/or company that is presented in this article.

### **REFERENCES**

- [1] Linn J, Messer HH. Effect of restorative procedures on the strength of endodontically treated molars. *J Endod* 1994;20:479–85.
- [2] Magne P, Carvalho AO, Bruzi G, Anderson RE, Maia HP, Giannini M. Influence of No-Fer rule and No-Post Buildup Design on the Fatigue Resistance of Endodontically Treated Molars Restored With Resin Nanoceramic CAD/CAM Crowns. *Oper Dent* 2014;39:595-602.
- [3] El-Damanhoury HM, Haj-Ali RN, Platt JA. Fracture Resistance and Microleakage of Endocrowns Utilizing Three CAD-CAM Blocks. *Oper Dent* 2015;40:201-10.

- [4] Pashley DH, Tay FR, Breschi L, Tjaderhane L, Carvalho RM, Carrilho M, Tezvergil-Mut luay A. State of the art etch-and-rinse adhesive. *Dent Mater.* 2011;27:1–16.
- [5] Chang C-Yu, Kuo JS, Lin YS, Chang YH. Fracture resistance and failure modes of CEREC endocrowns and conventional post and core-supported CEREC crowns. *J Dent Sci* 2009;4: 110-7.
- [6] Lander E. and Dietschi D., “Endocrowns: a clinical report,”. *Quintessence Int* 2008;39:99–106.
- [7] Dietschi D, Duc O, Krejci I, Sadan A. Biomechanical considerations for the restoration of endodontically treated teeth: A systematic review of the literature, part ii (evaluation of fatigue behavior, interfaces, and in vivo studies). *Quintessence Int* 2008;39:117-129.
- [8] Biacchi GR, Basting RT. Comparison of fracture strength of endocrowns and glass fiber post-retained conventional crowns. *Oper Dent* 2012;37:130–3.
- [9] Biacchi GR, Mello B, Basting R. The Endocrown: An Alternative Approach for Restoring Extensively Damaged Molars. *J Esthet Restor Dent* 2013;25:383–391.
- [10] Asmussen E, Peutzfeldt A, Sahafi A. Finite element analysis of stresses in endodontically treated, dowel-restored teeth. *J Prosthet Dent* 2005;94:321–9.