



A case of cutaneous pseudolymphoma induced by medicinal leech application and review of the literature

Tıbbi sülük uygulaması sonucu ortaya çıkan kutanöz psödolenfoma olgusu ve literatürün gözden geçirilmesi

Habibullah Aktaş¹, Aziz Ahmad Hamidi², Gökşen Ertuğrul¹, Harun Erol³

Abstract

Medicinal leech application is a common traditional therapy used for various disorders in many cultures for thousands of years. Although it is usually a safe method, serious side effects can also be seen. As a rare side effect of this method, cutaneous pseudolymphoma is a reactive skin disease caused by foreign antigens, infectious processes and arthropod bites. Idiopathic cases sometimes can be seen.

In this article, we present a case of cutaneous pseudolymphoma in an elderly woman with multiple nodules over her lumbar region emerging after leech application.

Keywords: Medicinal leeches, pseudolymphoma, traditional methods.

¹ Karabük University, Faculty of Medicine, Department of Dermatology, Karabük, Turkey.

² Karabük University, Research and Training Hospital, Department of Infectious Diseases, Karabük, Turkey.

³ Karabük University Faculty of Medicine Department of Pathology, Karabük, Turkey.

Informed Consent: The written consent was received from the patient who was presented in this study.

Hasta Onamı: Çalışmada sunulan hastadan yazılı onam alınmıştır.

Conflict of Interest: No conflict of interest was declared by the authors.

Çıkar Çatışması: Yazarlar çıkar çatışması bildirmemişlerdir.

Financial Disclosure: The authors declared that this case has received no financial support.

Finansal Destek: Yazarlar bu olgu için finansal destek almadıklarını beyan etmişlerdir.

Geliş Tarihi / Received: 15.06.2018

Kabul Tarihi / Accepted: 20.07.2018

Yayın Tarihi / Published: 30.11.2018

Sorumlu yazar / Corresponding author
Habibullah Aktaş

Adres/Address: Karabük Training and Research Hospital Department of Dermatology, Karabük/Turkey.

e-mail: aktashabib@hotmail.com

Tel/Phone: 0905324084611

Copyright © ACEM

Öz

Tıbbi sülük uygulaması binlerce yıldır birçok kültürde çeşitli hastalıkların tedavisinde kullanılan yaygın bir geleneksel tedavi yöntemidir. Genellikle güvenli bir yöntem olmasına rağmen, bazen ciddi yan etkiler de görülebilir. Bu metodun nadir bir yan etkisi olarak kutanöz psödolenfoma, yabancı antijenler, enfeksiyöz süreçler, arthropod ısırıkları ve bazen idiyomatik nedenlerle oluşan reaktif bir deri hastalığıdır.

Bu yazıda, sülük uygulaması sonrası çok sayıda nodülü olan ve kutanöz psödolenfoma tanısı konulan bir kadın olguyu sunuyor ve literatürü gözden geçiriyoruz.

Anahtar kelimeler: Psödolenfoma, tıbbi sülük, geleneksel yöntemler.

Introduction

Medicinal leech application (MLA) is a known traditional therapy in the eastern countries for thousands of years for various disorders [1]. The traditional therapies have been accepted as legal by Ministry of Health in Turkey for a couple of years. This legalization led to a significant increase in the number of applications of traditional methods including MLA in this country.

Lymphocytoma cutis or pseudolymphoma is a reactive skin disease, sometimes named as cutaneous lymphoid hyperplasia. The disease manifests itself as single or multiple red or purple papules, nodules or plaques mostly over the face, but the lesions are also involved in other body regions. There is a dense lymphocyte accumulation within the dermis histologically [2]. The causative factors include foreign antigens, infectious processes and arthropod bites. Idiopathic cases sometimes can also be seen. A detailed history is very helpful in differential diagnosis of cutaneous pseudolymphoma. Adnexal tumors, granuloma faciale, skin tuberculosis, rosacea, sarcoidosis and other granulomatous disorders should be thought for differential diagnosis of the disease.

We present a case of cutaneous pseudolymphomas caused by MLA.

Case report

A 65-year-old woman was admitted to our clinic due to rash with severe itchiness in the lumbar region. On skin examination, we observed eight semi-hard purple nodules over her lumbar area (Figure 1). There was no pain on palpation. In detailed history, we learned that she put eight leeches over her lumbar area for a lumbar pain. Excisional biopsy was performed for one of the lesions. Histopathological examination yielded dense polyclonal lymphocyte infiltration in the superficial and deep dermis, compatible with the diagnosis of benign cutaneous lymphoid hyperplasia (Figure 2). In hematological and radiological investigation, we did not see any abnormalities suggestive of lymphoma. We administered 20 mg/ml intralesional triamcinolone with 30 seconds open spray freeze (cryotherapy) per lesion with liquid nitrogen. There were residual hyperpigmented macules over the disordered area with no subjective symptoms after three weeks.

Written consent was taken from the patient.

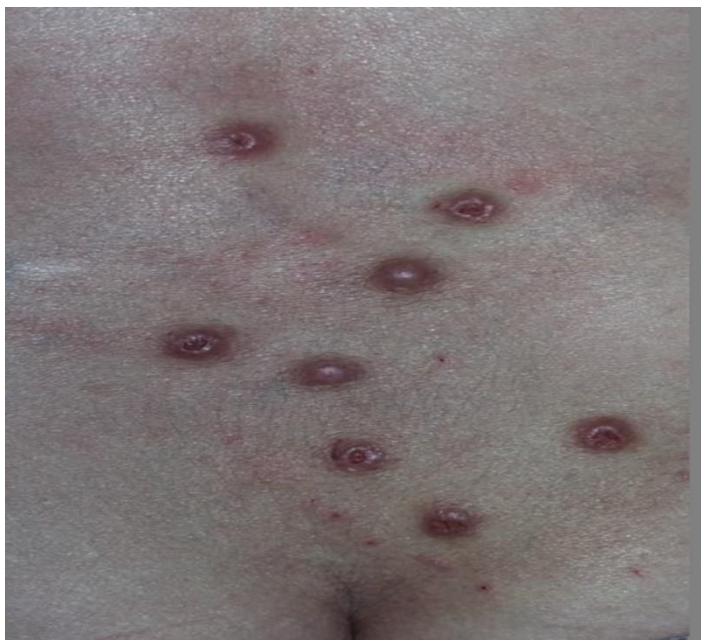

Figure 1: Purple nodules over the lumbar region.

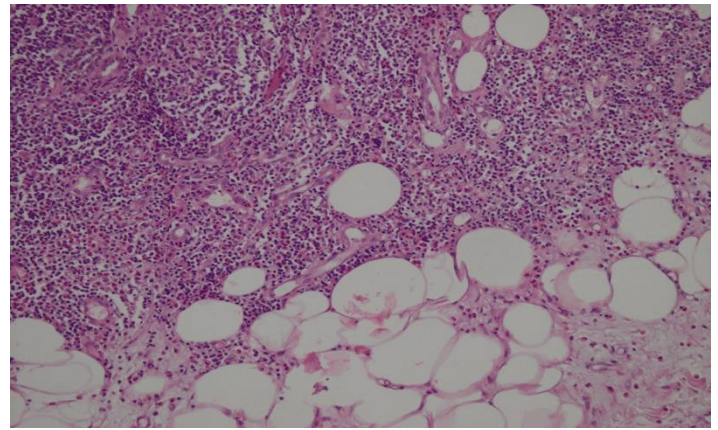


Figure 2: Pathological image shows dense lymphocytic infiltration in the dermis.

Discussion

MLA is an auxiliary method which is mainly used in association with vascularization. MLA has been found to be an effective medication in salvage of venous congestion of free flap by increasing its revascularization [1]. However, it also carries the significant risk of contamination of severe infectious agents to the host. Life-threatening infectious diseases such as sepsis and meningitis have also been reported [3-5]. Prolonged bleeding is another dangerous complication of medicinal leech therapy [6]. Cutaneous pseudolymphomas caused by MLA have been rarely reported in the literature. The summary of reported cases are shown in Table [2, 7-10]. Among the cases, there was only one male patient, the others were women. Probably the women are more interested in such traditional treatments. In female patients, the leech application was performed due to pain, contrary to an esthetic reason for the male patient [2, 7-10].

Histopathology is the gold standard in the diagnosis of cutaneous pseudolymphoma together with a detailed patient history. If detailed history is not taken, etiology could be missed because the lesions usually occur at least one month after MLA.

This case report may be regarded as a public health alert about uncontrolled traditional treatment methods. Increase in MLA may lead to life-threatening events such as severe infections and uncontrolled bleedings apart from cutaneous lymphoid hyperplasia which is a relatively benign side effect compared with others. We recommend that the authorities inform public about traditional treatment methods, including medical leeches, and that they carefully monitor inappropriate practices which are not made by physicians.

Table. Pseudolymphoma cases reported in the literature.

Article	Age (year)	Gender	Localization	*Duration after MLA	Reason for MLA	Treatment
Smolle J 2000	56	F	Lower legs	After several weeks	Venous insuff.	IL steroid
Choi Y 2012	52	M	Lower eyelids	After several months	Infra orbital dark circles	IL steroid
Khelifa E 2013	77	F	Lower back	After several months	Lumbar pain	Topical and IL steroid
Altamura D 2014	50	F	Back	After 5-6 weeks	Fibro myalgia	Topical steroids
Topikowska M 2018	38	F	Pubic region	Unclear	Uterine myoma	Topical and IL steroid
Our case	65	F	Lower back	After a few months	Lumbar pain	IL steroid

*Time to development of lesions after leech application, MLA: Medicinal leech application, IL: intralesional.

References

1. Spear M. Medicinal Leech Therapy: Friend or Foe. *Plast Surg Nurs.* 2016;36:121-5.
2. Choi Y, Kim SC. Cutaneous pseudolymphoma induced by *Hirudomedicinalis* therapy. *J Dermatol.* 2012;39:195-7.
3. Verriere B, Sabatier B, Carbonnelle F, Mainardi JL, Prognon P, Whitaker I, et al. Medicinal leech therapy and *Aeromonas* spp. infection. *Eur J Clin Microbiol Infect Dis.* 2016;35:1001-6.
4. Butt AM, Ismail A, Lawson-Smith M, Shahid M, Webb J, Chester DL. Leech therapy for the treatment of venous congestion in flaps, digital replants and revascularizations - A two-year review from a regional centre. *J Ayub Med Coll Abbottabad.* 2016;28:219-23.
5. [Reese K, Gumbel D, Seifert J, Daeschlein G, Napp M, Ekkernkamp A. Infections associated with treatment with *hirudomedicinalis* - Report of two cases and review of the literature]. *Handchir Mikrochir Plast Chir.* 2015;47:206-9.
6. Zengin S, Yarbil P, Kilic H, Al B. Prolonged bleeding due to a medicinal leech bite: another treatment method, primary suture. *BMJ Case Rep.* 2012 Jul 13;2012. doi: 10.1136/bcr.02.2012.5759.
7. Smolle J, Cerroni L, Kerl H. Multiple pseudolymphomas caused by *Hirudo medicinalis* therapy. *J Am Acad Dermatol.* 2000;43:867-9.
8. Khelifa E, Kaya G, Laffitte E. Cutaneous pseudolymphomas after leech therapy. *J Dermatol.* 2013;40:674-5.
9. Altamura D, Calonje E, Liao JI, Rogers M, Verdolini R. Diffuse cutaneous pseudolymphoma due to therapy with medicinal leeches. *JAMA Dermatol.* 2014; 150:783-4.
10. Tupikowska M, Woźniak Z, Wojciechowska-Zdrojowy M, Maj J, Jankowska-Konsur A. Hirudotherapy - a rare cause of pseudolymphoma. *Postepy Dermatol Alergol.* 2018;35:225-6.