

CASE REPORT

Melioidosis: An unusual presentation as mycotic pseudoaneurysm of Left Superficial Femoral Artery

Sarin J. Harison, Pratibha Bhat U., Rekha Rai

Department of Microbiology, K.S.Hegde Medical Academy, Deralakatte, Mangaluru, India

ABSTRACT

Melioidosis is a potentially fatal infectious disease usually seen in, but not restricted to the tropical areas of the world. *Burkholderia pseudomallei*, a soil saprophytic bacterium are the causative agent. It can produce latent infection and reactivate many years after initial exposure and can have varied clinical presentations. Here we put forward an unusual yet successfully treated case of melioidosis presenting as mycotic pseudoaneurysm of superficial femoral artery. A 62 year old male patient came with a one and a half month old history of swelling and pain in the left thigh. Culture of blood and pus samples from the patient yielded *Burkholderia pseudomallei*. Combinations of surgical and medical management lead to a good outcome in the patient. *J Microbiol Infect Dis 2018; 8(4):162-164*.

Keywords: melioidosis, pseudoaneurysm, superficial femoral artery

INTRODUCTION

Melioidosis is an infectious disease caused by *Burkholderia pseudomallei*. It is predominantly seen in tropical countries of the world, commonly in South-East Asia and Northern Australia. In these areas, it is present as a saprophyte in the soil and water of the paddy fields. Humans may acquire infection by direct contact, inhalation or consumption of contaminated water or soil dust [1].

B. pseudomallei are small, oxidase positive, motile, aerobic gram negative bacilli. Clinically, melioidosis can range from acute bloodstream infection to chronic suppurative infection with abscess formation in any organ, the lung, skin, joints, liver, spleen and skeletal muscle being common sites. Pneumonia or lung abscess is the most common manifestation of this disease [2,3].

In literature, most of the reports of mycotic pseudoaneurysms due to *Burkholderia pseudomallei* are of the large arteries like aortic, common iliac, subclavian arteries. There are very few cases of melioidotic mycotic aneurysm of superficial femoral artery [4-7]. In India, there is report of only 2 cases of pseudoaneurysm

secondary to melioidosis by Padmaja et al. in 2015 [8]. Both the cases involved a large artery, the descending thoracic aorta. To our knowledge there is no report of pseudoaneurysm of superficial femoral artery due to *B.pseudomallei* from South India.

METHODS

A 62-year old male who was employed in a local restaurant to wash the dishes was admitted to a tertiary care hospital in South India with chief complaints of pain in the left lower limb and swelling on the left thigh since one and a half months. He gave history of severe pain and swelling of entire left lower limb one week prior to admission. The pain progressed to a level that he had difficulty in walking. He was a known diabetic and an alcoholic.

On admission he was normotensive and afebrile. On physical examination, he had an 8 x 8 cm size, pulsatile swelling on the antero-medial aspect of left thigh. The distal left foot pulses were not palpable. Routine blood investigations showed hemoglobin 9.5 g/dl, WBC count of 11,500 cells/mm³ with 85% polymorphs, 12% lymphocytes and an erythrocyte sedimentation rate of 70 mm/hour.

Correspondence: Dr. Pratibha Bhat U., Department of Microbiology, K. S. Hegde Medical Academy, Deralakatte, Mangaluru, India

E-mail: pratibhabhat.u@gmail.com

Received: 25 July 2018 Accepted: 24 November 2018

Copyright © JMID / Journal of Microbiology and Infectious Diseases 2018, All rights reserved

Computed tomography (CT) angiogram was done and the patient was diagnosed to have pseudoaneurysm of left mid and distal superficial femoral artery with peripheral thrombus compressing the left superficial femoral artery (as shown in figure [1]).

After four days of admission, pseudoaneurysm excision with left great saphenous vein interposition grafting was done (Figure 2). Post operatively he was started on cefoperazone-sulbactam and metronidazole. But even on the 4th post-operative day, he was continuously having fever, pain and an elevated total count of 12,800 cells/mm³. Histopathology of the aneurysmal tissue reported features consistent with organizing thrombus and suppuration. Due to this pus and blood samples were sent to the laboratory for bacterial culture.

In the microbiology laboratory, blood sample was cultured by the automated BacT/ALERT-3D system. After 3 days of incubation, BacT/ALERT gave an alert for a positive growth and the broth was subcultured on MacConkey's agar and blood agar. The organism was identified by looking at its typical wrinkled colony morphology, typical bipolar staining on gram stain and by standard biochemical tests as *Burkholderia pseudomallei*. The same organism was isolated from the pus of the surgical site. The isolate was sensitive to ceftazidime, imipenem, meropenem, doxycycline and cotrimoxazole.

In the 20 days after the initial surgical treatment the patient had 2 episodes of massive bleeding from the site for which re-exploration and suturing was done. He continued to have fever, pain and purulent discharge from the wound site. Discussion with the surgeon revealed that though the microbiological investigations were suggestive of melioidosis; specific antibiotic therapy was not initiated.

He was then immediately started on intensive therapy with Inj. ceftazidime 2 g intravenously, 6th hourly and oral cotrimoxazole 160/800 mg 12th hourly for two weeks. The patient gradually improved, fever subsided, discharge from the site of wound stopped and there was no further episode of bleeding. The patient was discharged from the hospital after two weeks of commencement of specific antibiotic therapy with the advice to continue cotrimoxazole 160/800 mg orally twice daily for 3 months. The

patient was on regular follow up for 6 months and he had recovered completely.

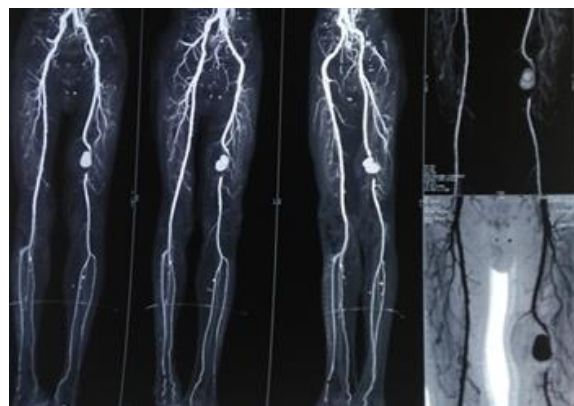


Figure 1. CT angiogram showing pseudoaneurysm of left mid and distal superficial femoral artery.

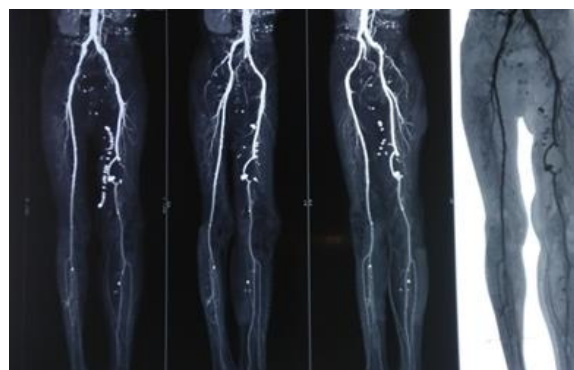


Figure 2. CT angiogram after pseudoaneurysm excision with left great saphenous vein interposition grafting.

DISCUSSION

Melioidotic pseudoaneurysm is associated with high morbidity, mortality and relapse rate. An aneurysm is a localized swelling of wall of an artery. In pseudoaneurysm, the sac wall is made up of only a single layer of fibrous tissue. When this is infected, it is known as mycotic pseudoaneurysm. Infection may be of a healthy artery or of a pre-existing aneurysm [6]. Mycotic aneurysms are commonly caused by *Staphylococci*, *Streptococci* and non typhoidal *Salmonellae* [6,8] Contrastingly, a retrospective study of 40 cases of mycotic aneurysms in Northeast Thailand, which is endemic for melioidosis, 42.5% were caused by *B. pseudomallei* followed by *Salmonella* species (30%) [7].

Timely diagnosis of infected pseudoaneurysm is of prime importance to prevent complications like rupture or embolization. Bacterial culture is essential for the diagnosis. *B. pseudomallei* broadly resemble other pseudomonads biochemically. Additional tests are necessary for the proper identification of the organism. It is also intrinsically resistant to many antimicrobial drugs like penicillins, aminoglycosides, first and second generation cephalosporins [1].

Surgical and medical treatment must go hand in hand for such complicated cases. Specific antibiotic regimen includes initial intensive treatment with ceftazidime or meropenem or imipenem for 2 weeks. Any one of the three may be combined with cotrimoxazole. Eradication therapy with cotrimoxazole for 3-6 months should be given after the initial therapy [1]. Surgical intervention consists of excision of the aneurysm and reconstruction with replacement graft in-situ or with an extra-anatomic bypass graft. (5) Schindler et al opined that in case of aneurysms infected with such highly pathogenic bacteria, autogenous vein replacement would not be a wise option as it may lead to treatment failure and relapse. Extra-anatomic bypass grafting would be a better option [4,9].

This case highlights that melioidosis can have unusual and surprising presentations and can cause lethal complications. Awareness and understanding among clinicians regarding the pathogenic potential of *B. pseudomallei* is of prime importance. The treating surgeon and consultant microbiologist should be vigilant for such kind of cases especially in endemic areas which would be helpful for timely diagnosis and proper management. This case also emphasizes the significance of specific antibiotic therapy in the management of melioidosis.

ACKNOWLEDGMENTS

Financial Disclosure: No financial support was received.

Declaration of Conflicting Interests: The authors declare that they have no conflict of interest.

REFERENCES

- Blaser MJ, Dolin R, Blaser. *Burkholderia pseudomallei* and *Burkholderia mallei*: Melioidosis and Glanders. In: Currie BJ, editor. Mandell, Douglas, and Bennett's Principles and practice of infectious diseases. 8th ed. Philadelphia: Churchill Livingstone Elsevier; 2015. p. 2541-2551.
- White NJ. Melioidosis. Lancet 2003; 361(9370):1715-1722.
- Vidyalakshmi K, Lipika S, Vishal S, Damodar S, Chakrapani M. Emerging clinico-epidemiological trends in melioidosis: analysis of 95 cases from western coastal India. Int J Infect Dis 2012; 16 (7):e491-7.
- Schindler N, Calligaro KD, Dougherty MJ, Diehl J, Modi KH, Braffman MN. Melioidosis presenting as an infected intrathoracic subclavian artery pseudoaneurysm treated with femoral vein interposition graft. J Vasc Surg 2002; 35(3):569-572.
- Low JGH, Quek AML, Sin YK, Ang BSP. Mycotic Aneurysm Due to *Burkholderia pseudomallei* Infection: Case Reports and Literature Review. Clin Infect Dis 2005; 40(1):193-198.
- Rao J, Kaushal AS, Hoong CK. Abdominal Aortic Pseudoaneurysm Secondary to Melioidosis. Asian J Surg 2009; 32(1):64-69.
- Anunnatsiri S, Chetchotisakd P, Kularbkaew C. Mycotic Aneurysm in Northeast Thailand: The Importance of *Burkholderia pseudomallei* as a Causative Pathogen. Clin Infect Dis 2008; 47(11):1436-1439.
- Padmaja K, Lakshmi V, Sudhakaran S, Malladi SVS, Gopal P, Ravinuthala KV. Unusual presentation of melioidosis in a case of pseudoaneurysm of descending thoracic aorta: Review of two case reports. Res Cardiovasc Med 2015; 4(2):7.
- Goh BKP, Chen CYY. Infected Pseudoaneurysm of the Femoral Artery Secondary to Melioidosis Infection of a Previous Femoropopliteal Bypass Graft. Ann Vasc Surg 2005; 19(1):90-93.