

Resistant Radial Artery Spasm During Coronary Angiography by Radial Approach Responded to Sedation: Importance of Anesthesia



Radiyal Arter Yoluyla Yapılan Koroner Anjiyografi Sırasında Gelişen ve Sedasyon ile Çözülen Dirençli Radiyal Arter Spazmı: Anestezinin Önemi

Hülya Yılmaz Ak

İstanbul University Cardiology Institute, Department of Anesthesiology and Reanimation, İstanbul, Turkey

Coronary interventions using the radial artery is a safe alternative to the femoral approach. However, the possible spasm of the radial artery limits this technique⁽¹⁾. The spasm of radial artery may be resistant to vasodilator medications including verapamil, lidocaine, and nitroglycerin and may cause serious complications such as pain and ischemia. In this letter, we present a case with radial artery spasm, which was resistant to vasodilators, but responded to sedation. A 45-year-old woman was referred to our angiography laboratory for chest pain and positive exercise testing. After the positive Allen test, we decided to perform angiography via right radial artery. Right radial artery was punctured following the local skin anesthesia. Before insertion of the guide wire, 5000 U unfractionated heparin, 5 mg verapamil, and 100 microgram nitroglycerin were given by radial artery sheath. A diagnostic 5F left Judkins catheter was placed in the left main coronary artery ostium. After left coronary system angiography, severe painful spasm in the radial artery occurred. The catheter and the sheath could not be retrieved (Figure 1A). Lidocaine, verapamil, and nitroglycerin were given at increasing doses via diagnostic catheter. At the end of all these medications, the spasm was not resolved. Then, we decided to make a sedation with anesthesia consultation. After 150 seconds sedation with propofol (40 mg) and midazolam (2 mg), the pain was completely resolved and the catheter and radial sheath were easily retrieved (Figure 1B). The patient was discharged at 3 hours. Radial artery spasm may occur during coronary angiography. The spasm may be resistant to vasodilator medications including verapamil, lidocaine, nitric oxide, and nitroglycerin. Therefore, novel drugs and methods including sedation and warm compress are needed in the management of this situation⁽²⁾. In the present case, radial artery spasm responded well to the sedation with propofol and midazolam. In conclusion, sedation is an effective method for radial artery spasm via vasodilation and decrease in vascular resistance and anxiety.

Correspondence

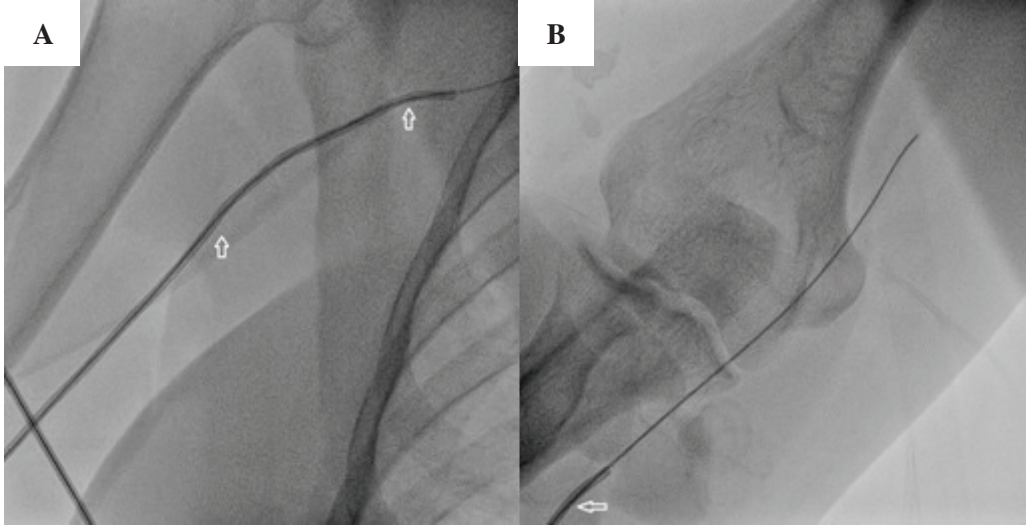
Hülya Yılmaz Ak

E-mail: hlyilmazz@hotmail.com

Submitted: 30.06.2017

Accepted: 03.07.2017

© Copyright 2017 by Koşuyolu Heart Journal. Available on-line at www.kosuyoluheartjournal.com



REFERENCES

1. Goldsmit A, Kiemeneij F, Gilchrist IC, Kantor P, Kedev S, Kwan T, et al. Radial artery spasm associated with transradial cardiovascular procedures: results from the RAS registry. *Catheter Cardiovasc Interv* 2014;83:E32-6.
2. Barçın C, Kurşaklıoğlu H, Köse S, Amasyalı B, Işık E. Resistant radial artery spasm during coronary angiography via radial approach responded to local warm compress. *Anadolu Kardiyol Derg* 2010;10:90-1.