



Early Detection of Ascending Aorta Dissection Using the Right Parasternal Echocardiographic Window

Cem Bostan¹, Murat Başkurt², Nihan Turhan Çağlar³, Serdar Küçüköğlü³

¹ İstanbul University Cardiology Institute, Department of Cardiology, İstanbul, Turkey

² İstanbul Bilim University, Avrupa Florence Nightingale Training and Research Hospital, Clinic of Cardiology, İstanbul, Turkey

³ İstanbul Training and Research Hospital, Clinic of Cardiology, İstanbul, Turkey

ABSTRACT

Right parasternal image is not a part of the routine echocardiographic examination and is seldom used. In cases of ascending aorta aneurysm and dissection, this view may help provide crucial information when the standard views are unable to visualize them adequately. Here, we reported a case of aortic dissection that was diagnosed early and easily using the right parasternal image.

Key Words: Echocardiography; aortic dissection; right parasternal image

Sağ Parasternal Ekokardiyografik Pencere Görüntüsü ile Çıkan Aorta Diseksiyonunun Erken Tanısı

ÖZET

Sağ parasternal ekokardiyografik pencere günlük pratikte sık kullanılmamaktadır. Çıkan aort anevrizması veya diseksiyon olgularında standart görüntülere ek olarak tanıda ciddi katkı sağlayabilmektedir. Biz de olgumuzda sağ parasternal ekokardiyografik pencere görüntüsü ile hızlı ve net olarak çıkan aort diseksiyonu tanısı konabileceğini belirtmekteyiz.

Anahtar Kelimeler: Ekokardiyografi; aort diseksiyonu; sağ parasternal görüntü

INTRODUCTION

If an echocardiographer uses only standard imaging planes (left parasternal, apical, subcostal, and suprasternal planes), he or she may fail to obtain vital information about the aorta, atrial septum, superior and inferior vena cavae, and coronary arteries. The right parasternal image is not a part of the routine echocardiographic examination and is usually not used in clinical practice. It has to be remembered that in cases of ascending aorta enlargement, this view may provide satisfactory images of the ascending aorta. Further, using this window, the echocardiographer may accurately visualize the sites of the communication points and tears in cases of ascending aorta aneurysm and dissection⁽¹⁻³⁾. Here, we reported a case of aortic dissection that was diagnosed early and easily using the right parasternal image.

CASE REPORT

A 65-year-old woman was admitted to the emergency department with a sudden onset of severe chest and back pain beginning 30 min ago. She had uncontrolled hypertension for 20 years, and she was not taking her medicine regularly. She was a non-smoker and had no history of any operation. Physical examination showed that she was mildly confused, and her blood pressure was 80/60 mmHg and was equal in both the arms. Her heart rate was 120 beats/min, and on cardiac auscultation, there was a mid-systolic murmur radiating to the neck and an early diastolic murmur at the right sternal border. Her respiratory system examination was normal along with other systems. Surface electrocardiogram was normal. Chest radiograph revealed a mild enlargement of the middle mediastinum. An emergent transthoracic echocardiogram was performed (Acuson Sequoia, Siemens Medical Solutions, Mountain view, CA, USA).

Correspondence

Cem Bostan

E-mail: bostancem@yahoo.com

Submitted: 06.08.2015

Accepted: 12.08.2015

© Copyright 2017 by Koşuyolu Heart Journal.
Available on-line at
www.kosuyoluheartjournal.com

Multiple echocardiographic images were taken in standard view, and a circumferential pericardial effusion compressing the right atrium was the only detected abnormality in the apical four-chamber view. Then the transducer was placed in the second right intercostal space, and several images of the dilated and dissected ascending aorta (dissection line and prominent moving intimal tear) were easily taken from the right parasternal view by providing different angles and positions to the transducer

(Figure 1). In the suprasternal view, the aortic arch was not dilated and the big vessels were observed to be uninvolved. An aortic aneurysm and dissection (DeBakey type II) was the diagnosis. Computerized tomography of the chest confirmed the diagnosis (Siemens Somatom Sensation 64, Siemens Medical Systems, Forchheim, Germany) (Figure 2). An emergent surgery was decided. She was transferred to the cardiovascular surgery center for emergent surgery.

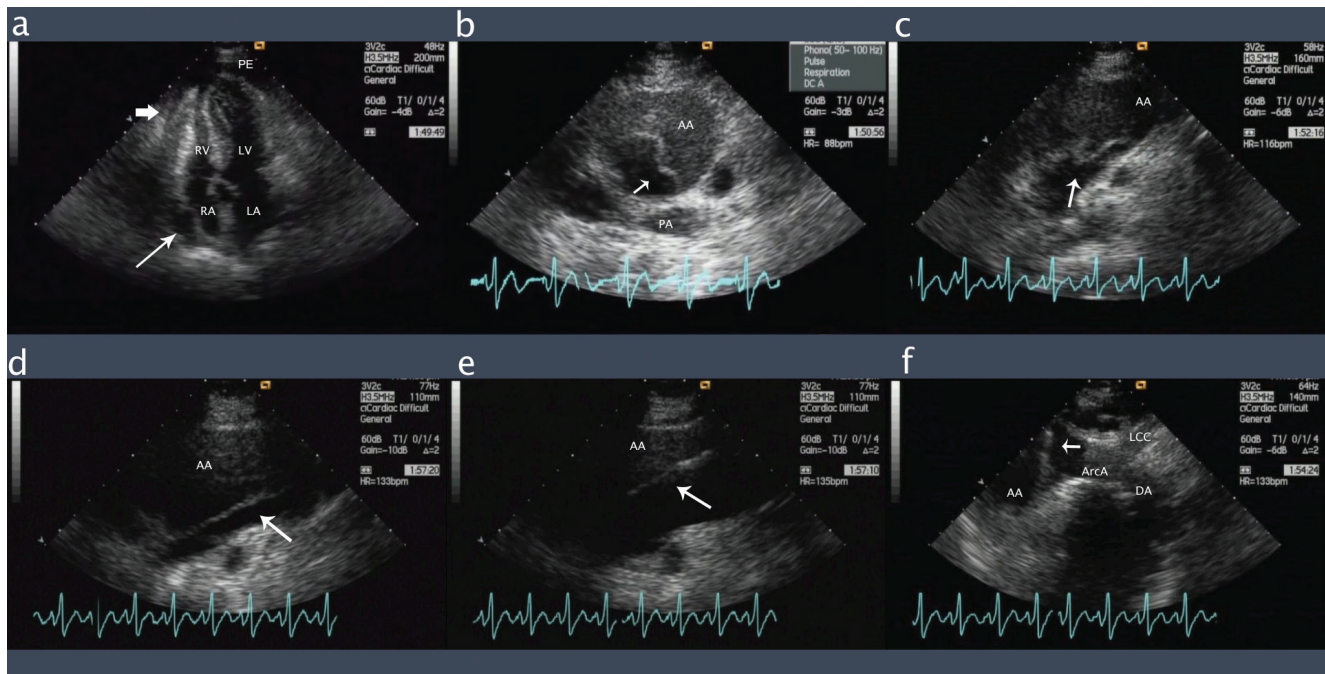


Figure 1. Right parasternal echocardiographic view of the patient.

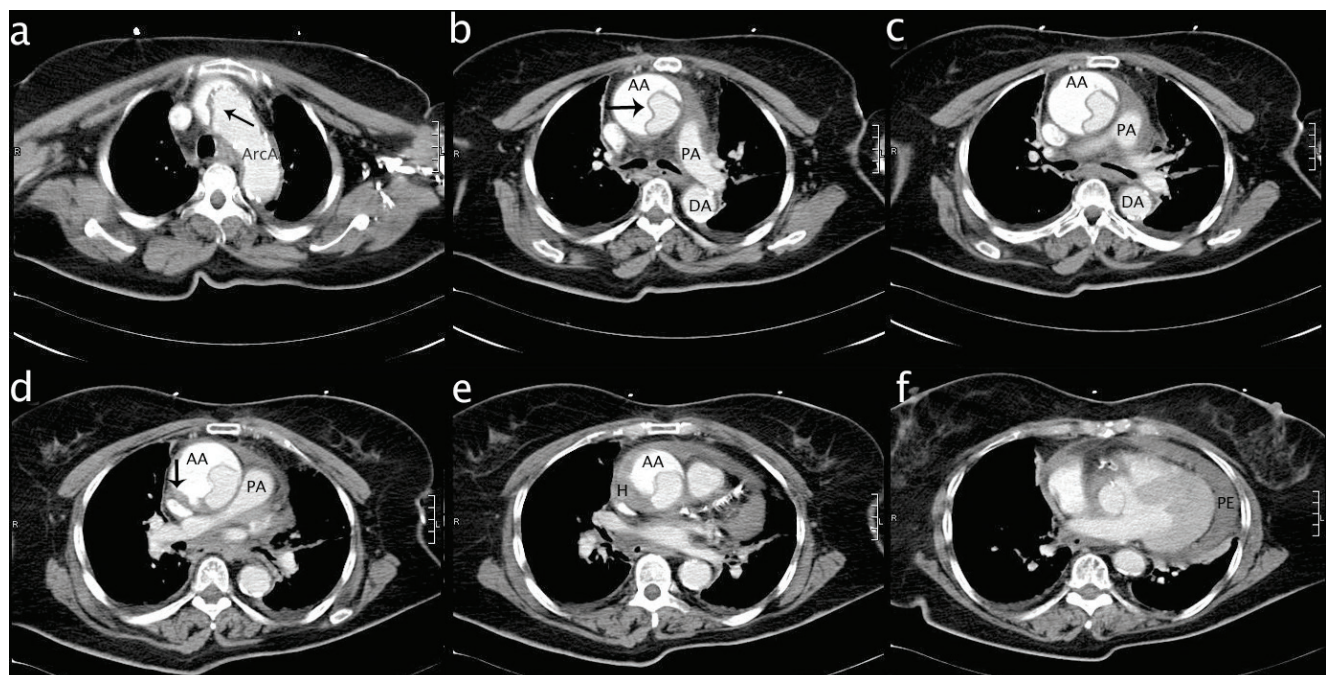


Figure 2. Computed tomography views of the patient.

DISCUSSION

This case revealed that ascending aorta dissection may be easily and accurately detected by right parasternal views using transthoracic echocardiography. Right parasternal image is not a part of the routine echocardiographic examination in clinical practice. In cases of ascending aorta aneurysm and dissection, this view may help provide crucial information regarding these areas when the standard views are unable to delineate them adequately⁽¹⁻³⁾. In conclusion, the right parasternal view should become a part of complete echocardiographic examination in any patient with suspected ascending aorta pathology.

REFERENCES

1. D'Cruz IA, Jain DP, Hirsch L, Levinsky R, Cohen HC, Glick C. Echocardiographic diagnosis of dilatation of the ascending aorta using right parasternal scanning. *Radiology* 1978;129:465-9.
2. D'Cruz IA, Jain M, Campbell C, Goldbarg AN. Ultrasound visualization of aortic dissection by right parasternal scanning, including systolic flutter of the intimal flap. *Chest* 1981;80:239-42.
3. Marcella CP, Johnson LE. Right parasternal imaging: an underutilized echocardiographic technique. *J Am Soc Echocardiogr* 1993;6:453-66.