



## Giant Abdominal Aortic Aneurysm: a Wondrous Image with Multidetector Computed Tomographic Angiography

### Dev Abdominal Aort Anevrizması: Çok Kesitli Bilgisayarlı Tomografi ile Eşsiz Görüntüsü

Mehmet Tuğrul Göncü, Burak Erdolu, Mesut Engin, Orhan Güvenç, Arda Aybars Pala  
Bursa High Specialization Training and Research Hospital, Clinic of Cardiovascular Surgery, Bursa, Turkey

A 76-year-old male patient was admitted to our emergency department with abdominal pain that became more intense in the last two days. His medical history was no table for hypertension, severe chronic obstructive pulmonary disease, and abdominal aortic aneurysm. Multidetector computed tomographic angiography (MDCT) showed a giant aortic aneurysm with a diameter of 11 cm × 12 cm, initiating from 2 cm below the right renal artery orifice (Figure 1A,B,C). Bifurcated stent prosthesis (Bolton Medical, Treovance) was implanted in the usual manner (Figure 2A,B). The patient was discharged on postoperative day 2.

Ruptured abdominal aortic aneurysms cause 12.000 deaths per year, of which 8.000 are infrarenal<sup>(1)</sup>. Aneurysm size is the most important factor related to likelihood of rupture, and the risk substantially increases in large aneurysms. A few cases with maximum diameter > 10 cm have been reported in the literature<sup>(2)</sup>. Furthermore, our MDCT scan view with a three-dimensional reconstruction is wondrous (Figure 1A).

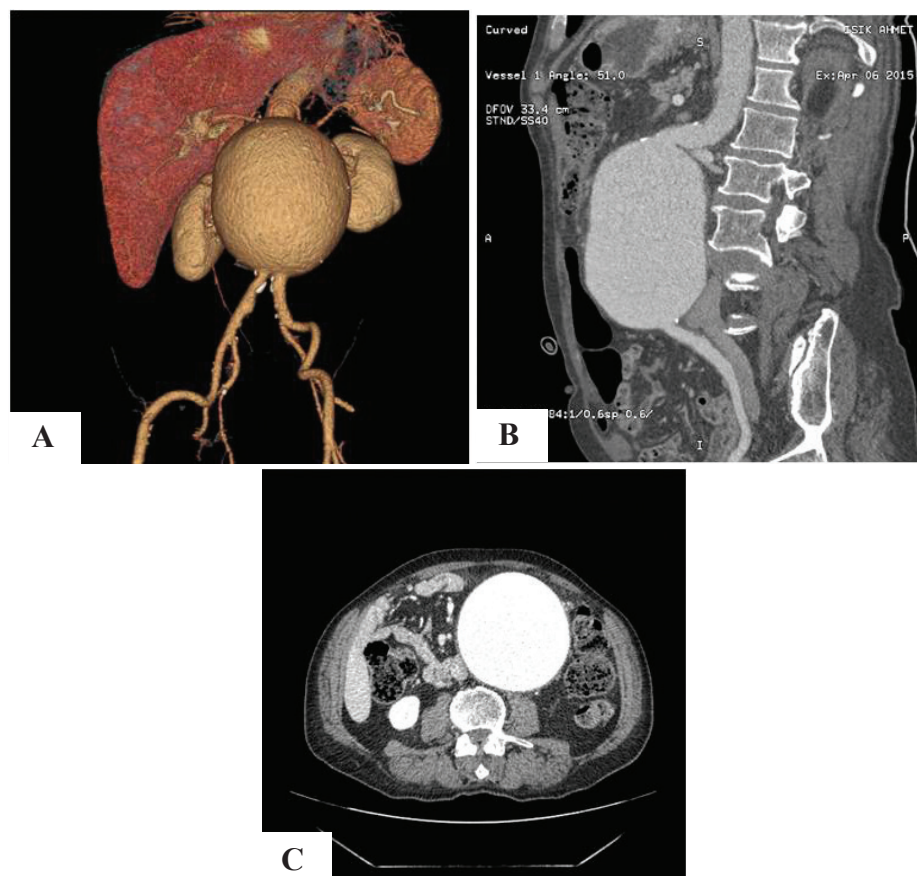


Figure 1. (A, B, C) Thoracoabdominal computerized tomographic angiographic images of the aneurysm.

#### Correspondence

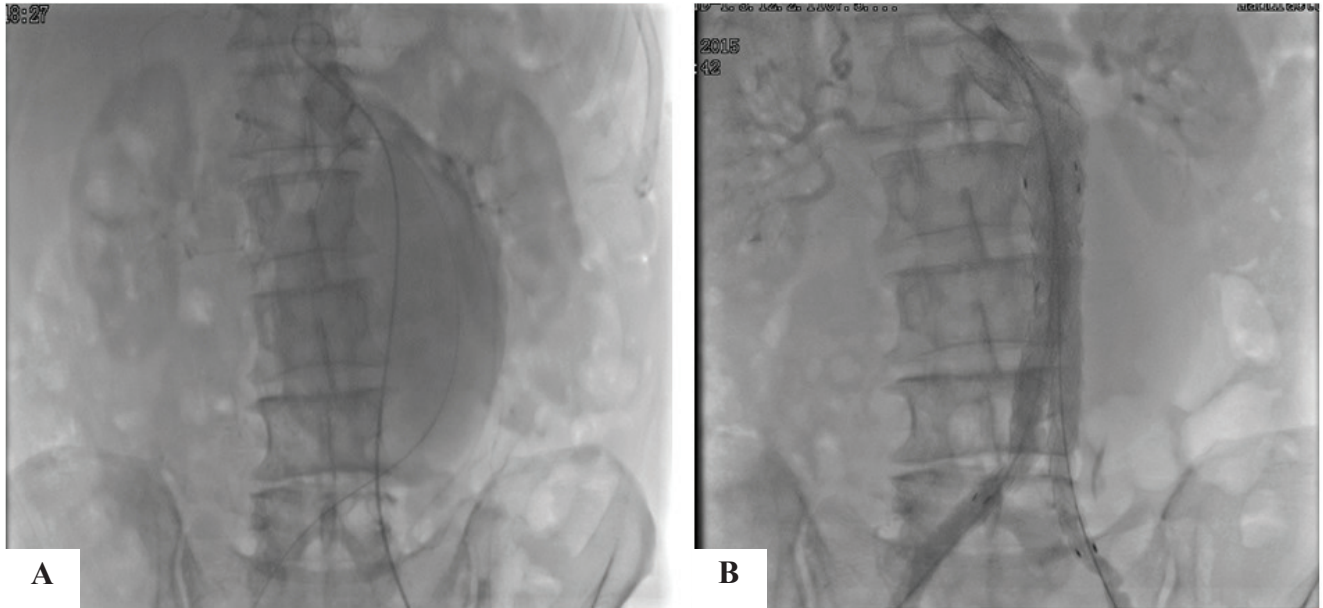
Mesut Engin

E-mail: mesut\_kvc\_cor@hotmail.com

Submitted: 13.11.2016

Accepted: 19.11.2016

© Copyright 2017 by Koşuyolu Heart Journal.  
Available on-line at  
www.kosuyoluheartjournal.com



**Figure 2.** (A, B) Bifurcated stent prosthesis was implanted in the usual manner.

## REFERENCES

1. National Institute for Health and Care Excellence (NICE). Access date: 25 February 2009. Available from: <https://www.nice.org.uk>
2. Gencinar T, Ayoglu U, Yılmaz A, Yılmaz M, Emmiler M. A 15 cm diameter ruptured abdominal aortic aneurysm: a case report. Clinical and operational techniques. *Causa Pedia* 2013;2:639. Available from: [www.causapedia.com](http://www.causapedia.com)