

Vestibular neuritis presenting in pregnancy: case report of rare entity and treatment options

Mert Cemal Gökgöz¹, Murat Binar¹, Fatih Arslan², Bülent Satar¹

¹Department of Otolaryngology-Head and Neck Surgery, University of Health Sciences, Gülhane Training and Research Hospital, Ankara, Turkey

²Department of Otolaryngology-Head and Neck Surgery, Beytepe Murat Erdi Eker State Hospital, Ankara, Turkey

DOI: 10.18621/eurj.436874

ABSTRACT

Vestibular neuritis in pregnancy is not often and it may be difficult for obstetricians and ENT doctors to evaluate a pregnant woman and to choose best treatment because of drug contraindications. A 33-year-old woman presented with vertigo at 28 weeks of the gestation. After physical examination and audiological and vestibular tests, vestibular neuritis was diagnosed, and the treatment was initiated. The patient completely recovered without any complaints; neither vestibular nor gynecological. There are few studies in the literature pointing out the evaluation of pregnant women with vestibular neuritis. However, there are safe ways to manage such patients.

Keywords: pregnancy, vertigo, vestibular neuritis, treatment

Received: June 25, 2018; Accepted: November 17, 2018; Published Online: December 13, 2018

Vertigo in pregnancy directly affects the quality of life both physically and emotionally [1]. Vestibular neuritis in pregnancy is not often and it may be difficult for obstetricians and ear, nose and throat (ENT) doctors to evaluate a pregnant woman and to choose best treatment because of drug contraindications. Since no guidelines exist for the management of vestibular neuritis in pregnancy, literature review is conducted to following case report to suggest the most effective method.

CASE PRESENTATION

A 33-year-old female patient, in 28th week of her pregnancy, consulted from obstetrics clinic to our ENT department with complaints of sudden onset of

vertigo, nausea, vomiting, having difficulty in standing up. There were no auditory complaints and no history of significant passed disease, except common cold history two weeks ago. In the general ENT examination of the patient; oropharyngeal, anterior rhinoscopic and otoscopic examination were observed healthy. In otoneurological examination, spontaneous horizontal nystagmus to the left and positive head impulse test on the right side were observed. She tended to fall right side while her eyes were closed.

The pure tone audiogram showed normal hearing of all frequencies tested (Figure 1). Biochemical parameters were also normal. We performed vestibular evoked myogenic potential (VEMP) test which revealed a prolonged P1-N1 latency (means reduced vestibular function) on the right side (Figure 2). Considering 28 week-gestation, we did not perform



Address for correspondence: Fatih Arslan, MD., Beytepe Murat Erdi Eker State Hospital, Department of Otolaryngology, Ankara, Turkey
E-mail: drfatiharslan@gmail.com, Tel: +90 312 9060670, Fax: +90 312 3045700

Copyright © 2018 by The Association of Health Research & Strategy
Available at <http://dergipark.org.tr/eurj>

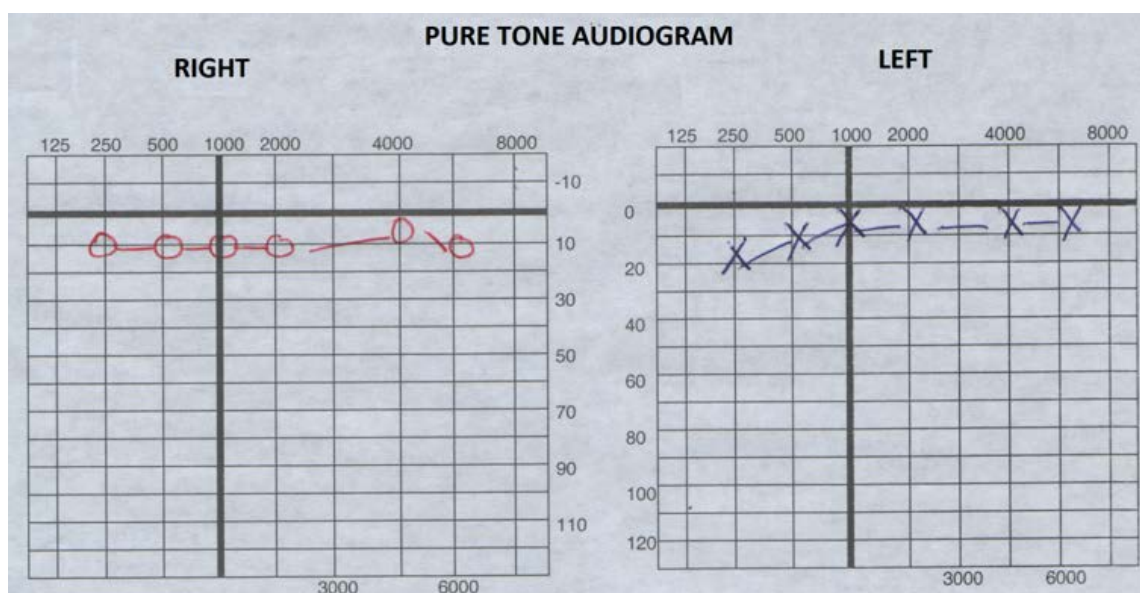


Figure 1. The pure tone audiogram of the patient.

caloric test, since it would exacerbate the vertigo, moreover, could have worsen the pregnancy.

We began medical treatment for acute vestibular neuritis. For 3 days, 2 times a day, we administrated intravenous treatment of dexamethasone, vitamin B6-B12 complex and metoclopramide. Because of pregnancy, we did not give vestibular suppressants like diazepam.

After medical treatment, vestibular rehabilitation exercises were explained to the patient to ensure complete recovery. One month later, vestibular system examination was repeated and all evaluation was normal. The term delivery of a healthy baby without any complication was pleased the mother. Written informed consent was obtained from the patient since no ethics committee approval is needed for case reports in our institution.

DISCUSSION

More than 80% of pregnant women receive medication for any reason and ENT causes are leading [2]. The study evaluating hearing and vestibular complaints in pregnant women demonstrated that the most frequent auditory complaint in pregnant is tinnitus [1]. Dizziness is another frequent complaint in pregnant. As mostly seen and treated in many ENT clinics, vestibular neuritis is a peripheral vestibular

disease which is thought to be caused by neurotropic viruses. It is characterized by sudden onset of severe dizziness, nausea and vomiting. Generally there are no symptoms related to hearing and pure tone audiogram is normal. Vestibular neuritis treatment in pregnant women has not been reported sufficiently in the English literature.

VEMP is used to determine whether the saccular, inferior vestibular nerve and central connections are working normally. Peripheral vestibular pathologies such as vestibular neuritis may show increased amplitudes of P1-N1, prolongation of latency, or absence of response. In our patient, latency was prolonged and pathological appearance could persist after the acute process [2].

Vlastarakos *et al.* [3] found that first and some second generation antihistamines (according to trimester) can be used in pregnant women if required. As antiemetics for vertigo attacks, they suggest meclizine, dimenhydrinate or metoclopramide. They also mentioned that betahistine, one of the most widely used antivertiginous drug, and vasodilatory agents are contraindicated in pregnancy.

Diazepam is used as a vestibular suppressant by many otolaryngologists. It is contraindicated in pregnancy (category: D), if used in a long time or high doses in pregnant women, may cause side effects such as floppy infant syndrome and benzodiazepine withdrawal syndrome [4]. So we did not apply

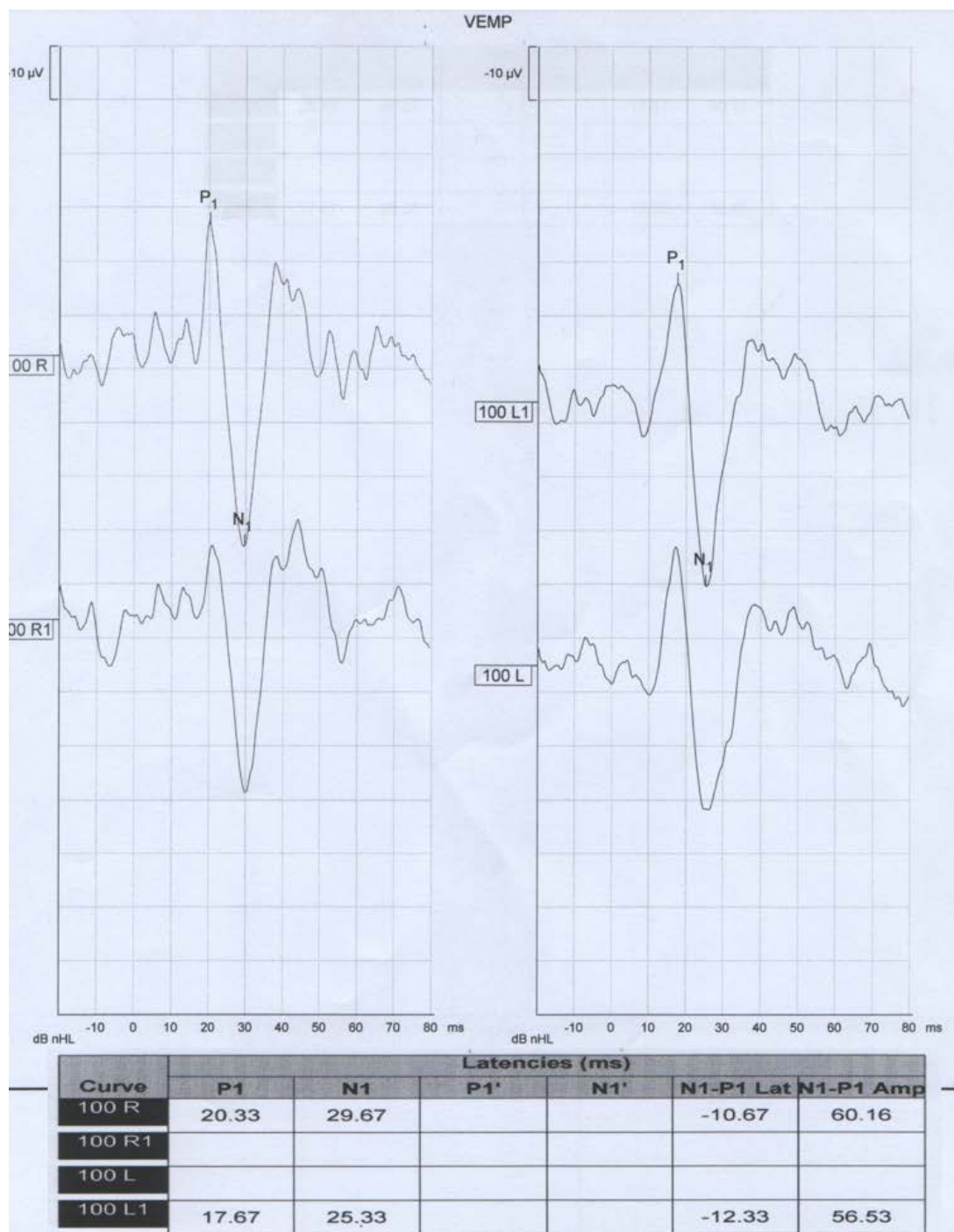


Figure 2. Vestibular evoked myogenic potential (VEMP) of the patient.
 Right = P1: 20.33, N1: 29.67; left = P1: 17.67, N1: 25.33.

diazepam treatment to our patient.

Corticosteroids in vestibular neuritis for anti-inflammatory effect, rapidly and significantly reduces nerve inflammation and improves the recovery of vestibular deficit [5]. Dexamethasone/betamethasone may be given to women at risk of premature birth to promote maturation of the fetus' lungs. In the United

States, pregnancy category of steroids is “C”, on the other hand, pregnancy category is “A” in Australia.

Metoclopramide is commonly used to treat nausea and vomiting in vestibular neuritis. Its pregnancy category is “B” in the United States and “A” in Australia. A large cohort study of babies born to Israeli women exposed to metoclopramide during pregnancy

found no evidence that the drug increases the risk of perinatal mortality [6].

Based on the literature, we applied dexamethasone and metoclopramide treatment for 3 days to our patient by keeping in touch with the obstetrics clinic. We did not observe any clinical or laboratory side effects during follow-up. At the end of medical treatment, we suggested vestibular rehabilitation exercises to the patient, founded by Davis and O'Leary [7], that can be performed easily without any assistance: "Patient must perform a series of head movements horizontally, gradually faster, as if expressing a "no", keeping a fixed gaze on a point ahead. When the maximum frequency of the movement is reached, the patient stops and, 10 seconds later, restarts the procedure, that must be repeated ten times. Next, the series of movements must be done vertically, as if the patient expresses a "Yes" with the head." Then we recommended the modified Cawthorne-Cooksey exercises (first described in 1946 and then modified in 1995) as a home protocol to the patient. These exercises or instrumental rehabilitation training consisting of standing with eyes open or closed on a platform moving, relative to the subjects, in the anteroposterior or mediolateral direction, training sessions for both interventions were twice daily, 30 minutes per session, for 5 days.

CONCLUSION

To conclude, as one of the common causes of vertigo, vestibular neuritis during pregnancy affects the quality of life. First of all, obstetricians and ENT surgeons should make the differential diagnosis and then provide appropriate treatment of vestibular

neuritis in pregnant by taking safety precautions related to any drug.

Informed consent


Written informed consent was obtained from the patient for publication of this case report and any accompanying images.

Conflict of interest

The authors declared that there are no potential conflicts of interest with respect to the research, authorship, and/or publication of this article.

REFERENCES

- [1] Schmidt PM, Flores Fda T, Rossi AG, Silveira AF. Hearing and vestibular complaints during pregnancy. *Braz J Otorhinolaryngol* 2010;76:29-33.
- [2] Nola G, Guastini L, Crippa B, Deiana M, Mora R, Ralli G. Vestibular evoked myogenic potential in vestibular neuritis. *Eur Arch Otorhinolaryngol* 2011;268:1671-7.
- [3] Vlastarakos PV, Nikolopoulos TP, Manolopoulos L, Ferekidis E, Kreatsas G. Treating common ear problems in pregnancy: what is safe? *Eur Arch Otorhinolaryngol* 2008;265:139-45.
- [4] Kjaer D, Horvath-Puhó E, Christensen J, Vestergaard M, Czeizel AE, Sørensen HT, et al. Use of phenytoin, phenobarbital or diazepam during pregnancy and risk of congenital abnormalities: a case-time-control study. *Pharmacoepidemiol Drug Saf* 2007;16:181-8.
- [5] Goudakos JK, Markou KD, Franco-Vidal V, Vital V, Tsaligopoulos M, Darrouzet V. Corticosteroids in the treatment of vestibular neuritis: a systematic review and meta-analysis. *Otol Neurotol* 2010;31:183-9.
- [6] Matok I, Gorodischer R, Koren G, Sheiner E, Wiznitzer A, Levy A. The safety of metoclopramide use in the first trimester of pregnancy. *N Eng J Med* 2009;360:2528-35.
- [7] Davis LL, O'Leary DP. Combined treatment as an effective method of vestibular rehabilitation. *An Otorrinolaringol Mex* 1994;39:19-24.



This is an open access article distributed under the terms of Creative Commons Attribution-NonCommercial-NoDerivatives 4.0 International License.