



Acute Coronary Syndrome Due to Complete Spontaneous Vasospasm of Left Coronary Artery System

Musluhittin Emre Erkuş, Halil Altıparmak, Zekeriya Kaya, Özgür Günebakmaz, Yusuf Sezen, Recep Demirbağ

Harran University Faculty of Medicine, Department of Cardiology, Şanlıurfa, Turkey

ABSTRACT

Coronary artery vasospasm is rare and may appear as focal or diffuse vasospasm throughout the coronary artery tree. We present a case of unstable angina with complete occlusion of the proximal left anterior descending artery and circumflex coronary artery due to severe diffuse coronary vasospasm, as demonstrated on coronary angiography. The patient was successfully treated with intracoronary bolus of nitroglycerin with restoration of flow in left coronary system.

Key Words: Coronary vasospasm; diagnostic coronary angiography

Sol Koroner Arteriyel Sistemin Tam Spazmından Dolayı Gelişen Akut Kroner Sendrom

ÖZET

Koroner arter vazospazmı, koroner arterlerde yaygın ya da bölgesel olarak görülen nadir bir durumdur. Bu olguda, sirkumfleks arter ve sol inen koroner arterin proksimalinde ciddi ve yaygın vazospazmın neden olduğu instabil anginalı bir hastayı sunduk. Hasta, intrakoroner nitrogliserin verilerek sol koroner sistem akımının sağlanmasıyla başarılı bir şekilde tedavi edildi.

Anahtar Kelimeler: Koroner vazospazm; tanısal koroner anjioografi

INTRODUCTION

Coronary artery vasospasm is an important cause of chest pain syndromes and is known as Prinzmetal or variant angina⁽¹⁾. It is more likely to occur in the presence of atherosclerotic lesions. However, vasospasm may also occur in coronary arteries without obstructive lesions⁽²⁾. It may occur spontaneously or be induced by both pharmacological agents and catheter. Spontaneous occurrence of coronary vasospasm during coronary angiography has been well documented in single vessels⁽³⁾. However, multivessel spasm is much less common. We report a rare case of diffuse spontaneous left coronary spasm during diagnostic coronary angiography procedure.

CASE REPORT

A 53-year-old male patient was admitted to the emergency department of our faculty with prolonged substernal chest pain radiating to the left arm. The patient has positive family history of coronary artery disease and smoking. On physical examination, systolic and diastolic blood pressures were 90/60 and heart rate was 80 beats/min. Electrocardiography taken in the emergency department revealed frequent ventricular extrasystoles. There were no abnormalities in cardiac enzymes. The patient was hospitalized with the suspicion of acute coronary syndrome. Coronary angiography was planned for the patient and performed by the Judkins technique. The left main coronary artery was engaged, and its ostium was located as normal in the left sinus of Valsalva. The left main trunk was normal, but only 1-cm proximal part of the left anterior descending (LAD) and left circumflex coronary (LCX) arteries could be observed because of complete spontaneous left system vasospasm (Figure 1A). After IV nitroglycerin administration, there were no atherosclerotic lesions and thrombus in coronary arteries (Figure 1B). Medical treatment of patient was changed from beta-blocker to calcium channel blocker.

Correspondence

Musluhittin Emre Erkuş

E-mail: taha14770@gmail.com

Submitted: 04.08.2014

Accepted: 07.08.2014

© Copyright 2016 by Koşuyolu Heart Journal.
Available on-line at
www.kosuyoluheartjournal.com

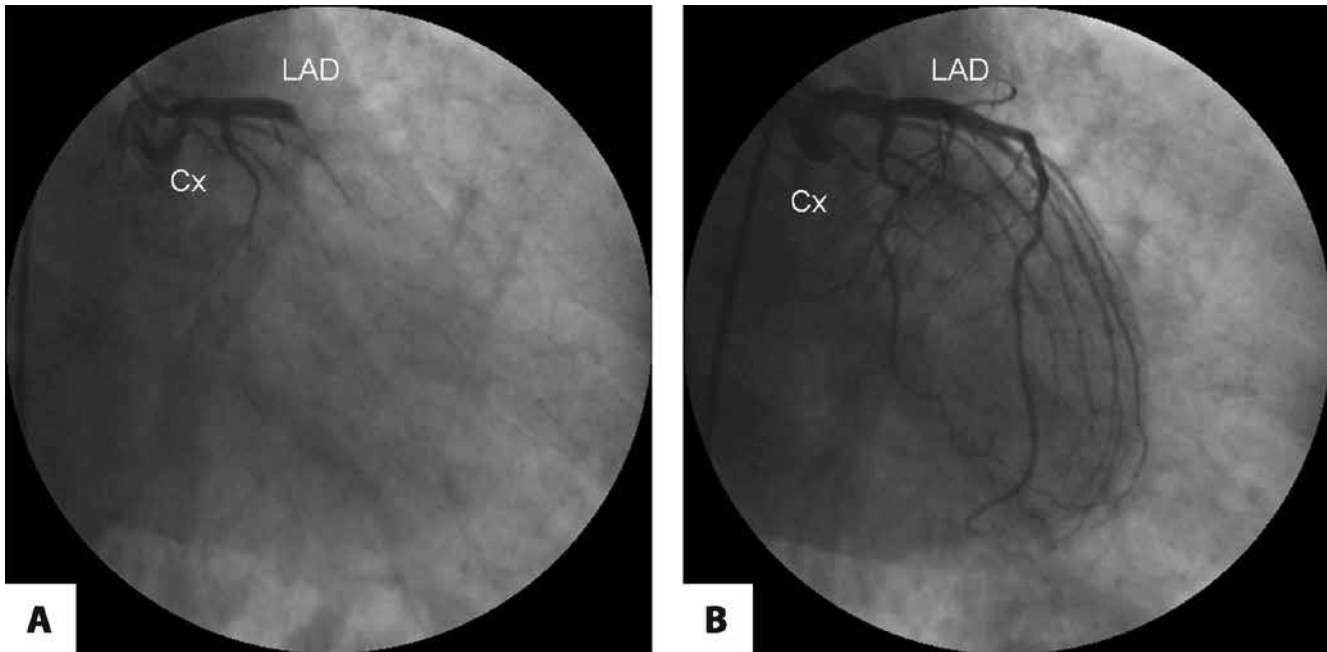


Figure 1. First contrast injection showed total occlusion of the proximal circumflex artery (Cx) and the left anterior descending artery (LAD) (A). Administration of several intracoronary boluses of nitroglycerin led to complete (B) restoration of flow in left coronary artery branches.

DISCUSSION

Coronary vasospasm is a frequent event during diagnostic or therapeutic coronary angiography procedures due to mechanical stimuli in the vessel. It may appear at the ostium, at the lesion site or anywhere in the vessel; it may be limited to a short segment or extend over a very long one and be associated with partial or total vessel occlusion⁽⁴⁾. The pathophysiologic mechanisms are not yet completely understood. Deficiency of endogenous NO activity, enhanced phospholipase C activity, increased markers of oxidative stress and inflammation, certain behavioural traits (e.g., type A personality, panic disorder and severe anxiety) and cigarette smoking are described as being associated with coronary artery vasospasm⁽⁵⁾. In our patient, all coronary artery vessels were normal with regard to atherosclerosis, but vasospasm was present throughout the left coronary system, including LAD and LCX, with near-complete obliteration of the vessel lumens. Family history of coronary artery disease, smoking and emotional stress are leading predisposing factors of coronary vasospasm. While taking detailed medical history of our patient, we realized that he was under emotional stress for a while.

Coronary vasospasm usually lasts for a very short time, and refractoriness to intracoronary nitroglycerin is very rare. If it does not recover with nitroglycerin administration, prolonged occlusion may lead to fatal arrhythmia, ischemia or cardiogenic shock⁽⁶⁾. Here, we reported a case of diffuse vasospasm of proximal left coronary arteries, which caused unstable angina and was resolved promptly by means of direct coronary vasodilators. Because coronary vasospasm was located at the

proximal LAD and LCX, it is likely to be spontaneous rather than catheter-induced. In our patient, due to the absence of detectable thrombus on angiogram, spontaneous spasm could be the cause of clinical presentation.

In conclusion, coronary artery spasm may mislead the physician to perform angioplasty or surgical revascularization. Therefore, in order to avoid malpractice, re-evaluation of lesions with nitroglycerin before angioplasty is recommended. Early recognition of this condition during coronary angiography may prevent cardiac events such as arrhythmia and shock. In addition, in patients with chest pain, presence of emotional stress should be investigated and stress-induced coronary vasospasm should be kept in mind as a cause of chest pain.

REFERENCES

1. Prinzmetal M, Kennamer R, Merliss R. A variant form of angina pectoris. *Am J Med* 1959;27:375-88.
2. Bertrand ME, LaBlanche JM, Tilmant PY, Thieuleux FA, Delforge MR, Carre AG, et al. Frequency of provoked coronary arterial spasm in 1089 consecutive patients undergoing coronary arteriography. *Circulation* 1982;65:1299-306.
3. Bell MR, Lapeyre AC 3rd, Bove AA. Angiographic demonstration of spontaneous diffuse three vessel coronary artery spasm. *J Am Coll Cardiol* 1989;14:523-7.
4. Sahin DY, İçen YK. Diffuse coronary spasm mimicking acute thrombosis after stent implantation. *Anadolu Kardiyol Derg* 2011;11:E29-30.
5. Kinlay S. Coronary artery spasm as a cause of angina. *Circulation* 2014;129:1717-9.
6. Kuçukosmanoglu M, Sincer I, Vuruskan E. Cardiopulmonary arrest caused by diffuse coronary artery spasm due to balloon dilatation: case report. *Türkiye Klinikleri J Cardiovasc Sci* 2013;25:166-70.