



New Generation Bioprosthesis Valve Implantation in Bicuspid Aortic Stenosis

Biküspit Aort Darlığında Yeni Jenerasyon Biyoprotez Kapak İmplantasyonu

Sina Ali, Yakup Alsancak, Serkan Sivri, Mehmet Bilge

Ankara Atatürk Training and Research Hospital, Clinic of Cardiology, Ankara, Turkey

An 81-year-old male with exertional dyspnea (NYHA class 2-3) and presyncope exacerbated within the last year and was admitted to the department of cardiology of our center. He had a past medical history of coronary artery bypass grafting (CABG), chronic obstructive pulmonary disease (COPD) and benign prostatic hypertrophy. Electrocardiogram showed sinus rhythm and signs of left ventricular hypertrophy. Trans-thoracic and trans-oesophageal echocardiographic assessment showed a normal left ventricular systolic function (LVEF: 65%), concentric left ventricular hypertrophy (interventricular septum/posterior wall: 1.3/1.4 cm), severe stenosis, degenerative and intensively calcified bicuspid aortic valve (BAV) (aortic valve area: 0.9 cm², aortic maximum/mean gradient: 64/44 mmHg), moderate tricuspid regurgitation with high systolic pulmonary artery pressure (60 mmHg) and ascending aorta dilatation (AAD) (4.5 cm). The computed tomographic examination revealed an aortic annulus sized 25.3 mm (Figure 1). The patient was evaluated by the heart team, which decided to perform trans-catheter aortic valve implantation (TAVI; STS: 7.2%, logistic EuroSCORE: 21%). After obtaining the patient's written consent, a medium-sized Symetis ACURATE neo TF (SATF) was implanted successfully by trivial paravalvular aortic regurgitation (mean aortic gradient was 8 mmHg) (Figure 2).

In BAVs, the possibility of valve embolisation is high because of concomitant AAD incidences. Also, the elliptic shape of the annulus and the presence of asymmetrical calcification are important factors for excellent results (especially for aortic regurgitation and conductance disturbances) after TAVI. SATF bioprosthesis valve is a new second-generation valve with the following unique features: 1) Flexible stabilisation arches that are responsible for the self-aligning properties of the valve ensuring predictable coaxial alignment; 2) Upper crown, which guarantees stable positioning and supra-annular anchoring of the valve, capping the native leaflets and mitigating the risk of coronary obstruction and paravalvular leak; 3) Unlike other devices, SATF has a very low radial force and facilitates optimal implantation with only a few millimeters protruding in the LVOT during the procedure, leading to lower rates of conductance disturbances and 4) The pericardial skirt and lower crown minimise paravalvular leak. Therefore, SATF may be a good choice in patients with severe bicuspid and calcified aortic stenosis owing to these different and effective features.

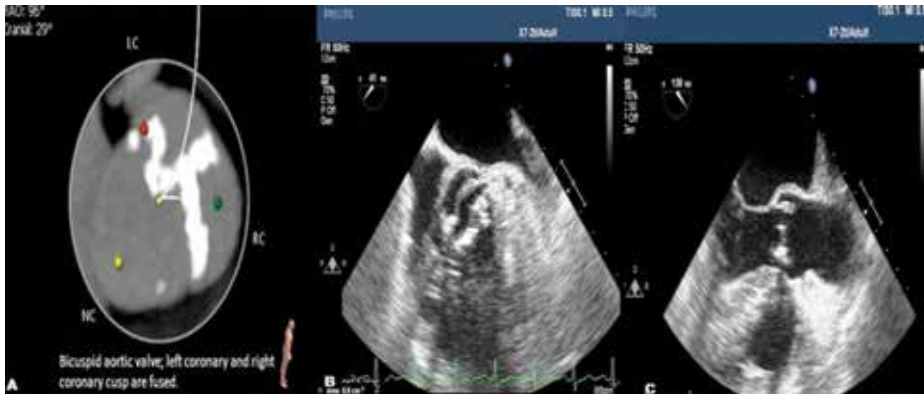

Figure 1. (A) Computed tomography is showing the bicuspid aortic valve and the fusion of left coronary and right coronary cusps, (B) Trans-oesophageal echocardiography demonstrates the bicuspid aortic valve in the short axis, (C) Trans-oesophageal echocardiography demonstrates the bicuspid aortic valve in the long axis.

Correspondence

Serkan Sivri

E-mail: drserkansivri@gmail.com

Submitted: 27.06.2016

Accepted: 03.08.2016

© Copyright 2016 by Koşuyolu Heart Journal.
Available on-line at
www.kosuyoluheartjournal.com

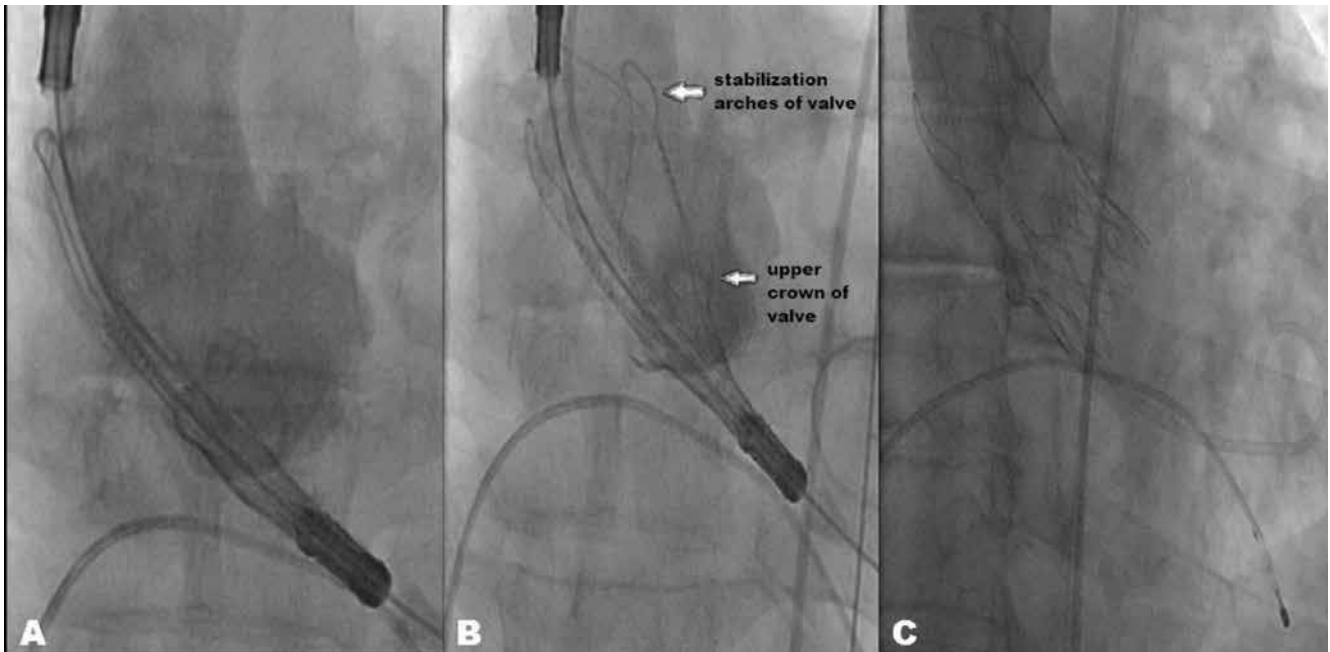


Figure 2. (A) The association between the Symetis ACURATE neo bioprosthesis and aortic annulus, (B) Stabilisation arches of valve and the position of the valve, (C) Final aortography demonstrating trivial aortic regurgitation after the procedure.