

Presentation of a True Aneurysm of the Right Common Femoral Artery

Sağ Ana Femoral Arterin Gerçek Anevrizması Sunumu

Muhammet Onur Hanedan, Mehmet Ali Yürük, Tanıl Özer, Uğur Ziyrek, İlker Mataracı

Ahi Evren Chest Cardiovascular Surgery Training and Research Hospital, Clinic of Cardiology, Trabzon, Turkey



Common femoral artery aneurysms are uncommon and very rarely isolated. Here, we describe a large right femoral artery aneurysm that caused local discomfort and pain. A 60-year-old man was referred to an outpatient clinic of a cardiovascular surgery department. He had a 3-year history of a swelling in the right inguinal region and complained of its increasing size and worsening of pain. An examination of the right groin revealed a painless, pulsatile mass (5-7 cm in size). There was no history of hypertension, connective tissue disorder, Behcet's disease or any intervention in the right groin. Blood pressure was equal in both legs. Complete blood count and other blood test results were within normal limits. He had a smoking history of 25 packs/year. Duplex ultrasound of the mass revealed an aneurysm, measuring 35 × 38 mm, of the right common femoral artery. Computed tomography was performed, which showed a 33.5 mm aneurysm sac in a 5 cm segment (Figure 1). Surgery was performed under spinal anaesthesia. The aneurysm was dissected, and an 8-mm Dacron graft was interposed (Figures 2A and B). The patient was discharged on the postoperative day 2. He had an uneventful recovery, with no complications found at his 1-week postoperative follow-up.

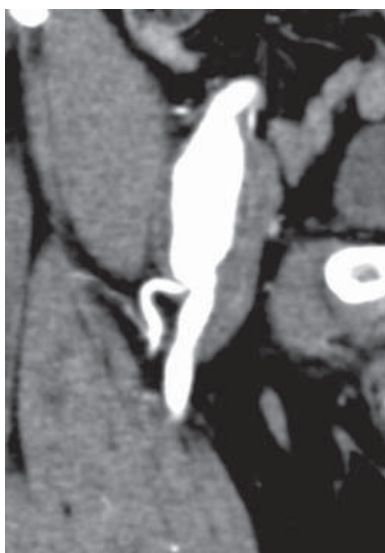

Figure 1. Computed tomography of the aneurysm.

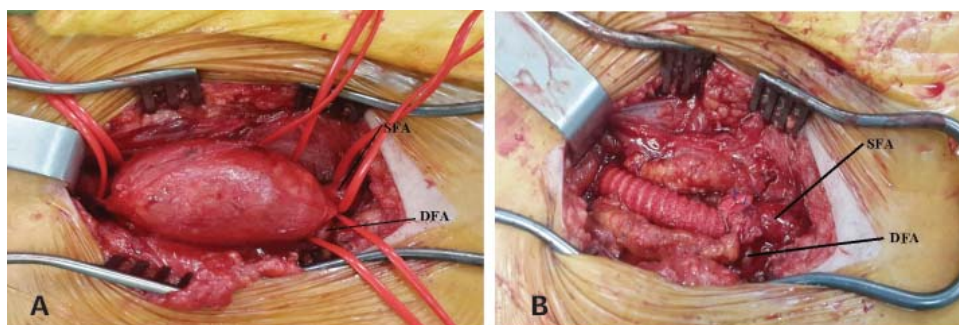


Figure 2. (A) Intraoperative view of the aneurysm, (B) Intraoperative view of the repaired aneurysm (SFA, superficial femoral artery; DFA, deep femoral artery).

Correspondence

Muhammet Onur Hanedan

E-mail: ohanedan@hotmail.com

Submitted: 22.02.2016

Accepted: 23.03.2016

@ Copyright 2016 by Koşuyolu Heart Journal.
Available on-line at
www.kosuyoluheartjournal.com