



A Case of a Ventricular Tachycardia Caused By a Central Venous Port Catheter Embolism

Santral Venöz Port Kateter Embolisine Bağlı Bir Ventriküler Taşikardi Olgusu

Zekeriya Kaya¹, Özgür Günebakmaz¹, Yusuf Sezen¹, Emre Erkuş², Alper Aksoy³

¹ Harran University Faculty of Medicine, Department of Cardiology, Şanlıurfa, Turkey

² Şanlıurfa Balıklıgöl State Hospital, Clinic of Cardiology, Şanlıurfa, Turkey

³ Şanlıurfa Training and Research Hospital, Clinic of Cardiology, Şanlıurfa, Turkey

A 41-year-old male patient was admitted to the emergency department with complaints of palpitations and dizziness. Past medical history revealed that the patient was treated with radiotherapy and 5-fluorouracil via right subclavian vein port due to colon carcinoma. The patient's electrocardiography on admission showed monomorphic sustained ventricular tachycardia (Figure 1). Patient was treated with infusion of amiodarone and the rhythm returned to normal sinus rhythm (Figure 1). Transthoracic echocardiography revealed a swinging mass in the right atrium though the image quality was poor. Fluoroscopy revealed dislodged port catheter extending from the right atrium to the pulmonary artery (Figure 2). Since port catheter was considered as the probable cause of ventricular tachycardia, removal of the port catheter was planned. Port catheter was extracted with snare catheter after insertion of 7 French sheath via the right femoral vein (Figure 3). He was discharged on the day of intervention and was well on first month follow-up control.

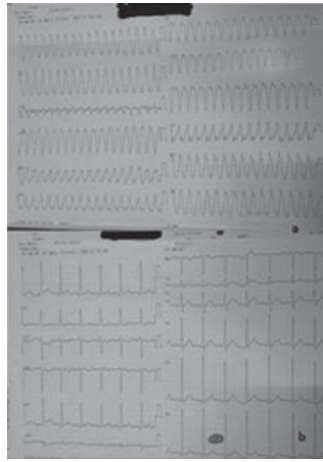

Figure 1. The sample of ECG during application and the sample of ECG after amiodarone infusion.

Although the necessity of removing of part of the port catheter in every case is not yet clear, removal seems to be a logical option due to major complications such as endocarditis, arrhythmias, heart failure, thrombosis, sepsis^(1,2).

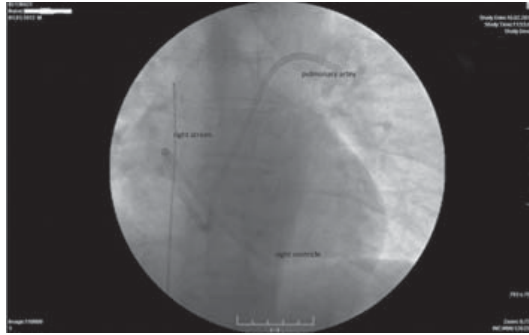


Figure 2. Port catheter extending from the right atrium to the pulmonary artery.

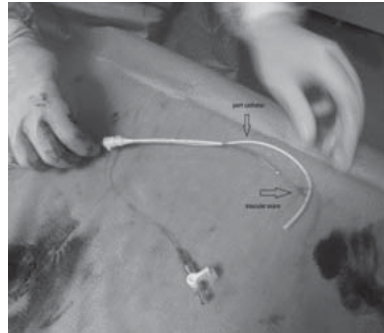


Figure 3. Extracted port catheter and vascular snare.

REFERENCES

1. Liu JC, Tseng HS, Chen CY, Chem MS, Chang CY. Percutaneous retrieval of 20 centrally dislodged Port-A catheter fragments. *Clin Imaging* 2004;28:223-9.
2. Grabenwoeger F, Bardach G, Dock W, Pinterits F. Percutaneous extraction of centrally embolized foreign bodies: A report of 16 cases. *Br J Radiol* 1988;61:1014-8.

Yazışma Adresi

Özgür Günebakmaz

E-posta: drgunebakmaz@yahoo.com

Geliş Tarihi: 02.09.2013

Kabul Tarihi: 03.09.2013

@ Copyright 2015 by Koşuyolu Heart Journal.
Available on-line at
www.kosuyolukalpedergisi.com