

ORIGINAL ARTICLE

Does radiographic success correspond with the clinical outcomes in the treatment of idiopathic scoliosis?

Gözde YAĞCI, Yavuz YAKUT

Purpose: The aim of this study was to determine whether clinical outcomes change according to radiographical curve improvement or progression in females with adolescent idiopathic scoliosis (AIS).

Methods: Seventy-six patients with AIS, between 10 and 16 years, were conservatively treated. The Cobb angle on radiograph, angle of trunk rotation with scoliometer, body asymmetry with Posterior Trunk Symmetry Index (POTSI) and cosmetic trunk deformity with the Walter Reed Visual Assessment Scale (WRVAS) were retrospectively examined in 76 patients before and after four-month conservative treatment. Patients were divided into two groups based on the presence or absence of the radiographic success (change in Cobb angle $\geq 6^\circ$) for Scoliosis Research Society as curve improvement (N=38) or curve progression (N=38) group. Results were compared between two groups.

Results: It was found that thoracic and lumbar Cobb angles and rotations, body symmetry and cosmetic trunk deformity showed improvement in both groups. There was greater improvement in only Lumbar Cobb angle in the curve improvement group than the curve progression group.

Conclusion: This study showed that patients who had radiographical curve progression showed similar improvement in clinical outcomes such as, trunk rotation, body symmetry and cosmetic trunk deformity with patients who had curve improvement with conservative treatment.

Keywords: Scoliosis, Therapeutics, Evaluation studies.

Adölesan idiyopatik skolyoz tedavisinde radyografik başarı ile klinik sonuçlar uyumlu mudur?

Amaç: Bu çalışmanın amacı adölesan idiyopatik skolyozlu (AIS) kızlarda, klinik sonuçların, radyografik olarak eğride düzelme veya kötüleşmeye göre değişip değişmediğini araştırmaktır.

Yöntem: Yaşları 10 ve 16 arasında değişen 76 AIS'li hasta konservatif olarak tedavi edildi. 76 bireyin dört aylık tedavi öncesi ve sonrasını içeren, radyografik Cobb açısı, skolyometre ile gövde rotasyon açısı, Posterior Gövde Simetri Endeksi (*Posterior Trunk Symmetry Index*) ile gövde asimetrisi, Walter Reed Görsel Değerlendirme Ölçeği (*The Walter Reed Visual Assessment Scale*) ile gövde simetrisi verileri retrospektif olarak incelendi. Bireyler, Skolyoz Araştırma Derneği (*Scoliosis Research Society*) tarafından karşılaştırılan radyografik başarının varlığı ve yokluğuna göre eğride iyileşme (N=38) ve kötüleşme (N=38) olarak adlandırılan iki gruba ayrıldı (Cobb açısı $\geq 6^\circ$). Sonuçlar iki grup arasında karşılaştırıldı.

Bulgular: Her iki grupta da bireylerin torasik ve lumbar Cobb ve rotasyon açıları, gövde simetrisi ve kozmetik gövde deformitelerinde iyileşme elde edildi. Sadece lumbar Cobb açısında, eğride iyileşme grubunda eğride kötüleşme grubuna göre daha fazla gelişme görüldü.

Sonuç: Bu çalışma, radyografik olarak eğri progresyonu olan bireyler ile eğrilerinde iyileşme olan bireylerin, gövde rotasyonu, vücut simetrisi ve kozmetik gövde deformitesi gibi klinik değerlendirme sonuçlarında benzerlik gösterdiğini göstermiştir.

Anahtar kelimeler: Skolyoz, Tedavi, Değerlendirme çalışmaları.

Yağci G, Yakut Y. Does radiographic success correspond with the clinical outcomes in the treatment of idiopathic scoliosis? J Exerc Ther Rehabil. 2017;4(2):54-60. Adölesan idiyopatik skolyoz tedavisinde radyografik başarı ile klinik sonuçlar uyumlu mudur?



G Yağci: Hacettepe University, Faculty of Health Sciences, Department of Physiotherapy and Rehabilitation, Ankara, Türkiye.
Y Yakut: Hasan Kalyoncu University, Faculty of Health Sciences, Department of Physiotherapy and Rehabilitation, Gaziantep, Türkiye.
Corresponding author: Gözde Yağci: gosdegr@hotmail.com
ORCID ID: 0000-0002-4603-7162
Received: May 23, 2017.
Accepted: July 31, 2017.

Measurement of curve angle on the coronal plane with the Cobb's method in digital radiography is the gold standard method for measuring curve magnitude as clinically accepted diagnostic measurement method of scoliosis.¹ Change in Cobb's angle with time has been used to determine whether curve progression or improvement occurs. It has also been developed for determining the individual treatment choice (observation, exercise, bracing or surgery) or effectiveness of a bracing or an exercise therapy approach in idiopathic scoliosis.² However, the Cobb's angle itself is limited because it is a single-plane measure of internal spinal deformity.³ This is not often the patient's primary concern or primary indicator of the trunk deformity in scoliosis.⁴

For determining curve progression, radiological confirmation of presence of clinically Cobb angle reduction has been commonly used in scoliosis research area. An increase of at least 5° between radiographs taken from consecutive clinical visits indicates progression of a curve. The Scoliosis Research Society (SRS) criteria for non-operative management consider treatment as a success only if a curve reduction was reported to be over 5 degrees of Cobb's angle in scoliotic patients who are skeletally immature.⁵

But patient outcome, or satisfaction should also important measure of the success of the treatment.⁶ Idiopathic scoliosis is a three-dimensional deformity of the spine and creates changes in the morphology of the spine and the trunk. Therefore, patient evaluation in relation with spinal and trunk deformity is an issue of necessary interest for physiotherapists.⁷ The clinical evaluation of the patient includes parameters such as the assessment of axial trunk rotation in transvers plane, back asymmetry and cosmetic trunk deformity.⁸ Angle of trunk rotation can be measured by using different techniques regarding Pedriolle method or Raimondi ruler in radiography,⁹ and Bunnell scoliometer in forward bending posture.¹⁰ Back asymmetry measurement systems are based on three-dimensional or two-dimensional surface topographic methods. Specific instruments are used, such as Trunk Appearance Scale,¹¹ and Walter Reed Visual Assessment scale¹² for evaluating cosmetic trunk deformity from scoliosis for the

physiotherapist or the patient's perspective in daily practice. These scales are considered to have good capacity to differentiate the severity of the trunk deformity.¹¹

There are some studies, which have investigated the relation between the radiographic and clinical parameters in scoliosis.^{8,13,14} Morrison et al. found weak correlation between Cobb angle and apical vertebral rotation.¹³ Yang et al. reported that none of the radiographic measures showed strong correlation with clinical measures of trunk asymmetry.¹⁴ In a recent review, surface topographic measurements was also considered to have very little correlation to Cobb angle measurements.⁸ The cosmetic improvement of the trunk after any treatment in AIS is a paramount importance to the child under treatment and his/her family.⁶ The trunk asymmetry cannot be seen directly in traditionally used radiography by the physician. The alternative measurements, which provide additional clinical information such as axial trunk rotation, back symmetry, and cosmetic deformity, have not a widespread use in a clinical setting. However, it has been emphasized that the best and worst outcome of the scoliosis treatment are predominantly related to patient factors, not radiographic measures.¹⁵ Furthermore, to the best of our knowledge, no previous studies have examined the relationship between radiographic success and clinical measurement outcomes in the treatment of AIS. Therefore, our study aimed to compare clinical measurement outcomes in patients with radiographic success of the curve and patients with curve improvement in the process of AIS conservative treatment.

METHODS

This is a retrospective study of prospectively obtained materials for a continuous series of patients with adolescent idiopathic scoliosis, who underwent conservative management of scoliosis including exercise or/and bracing intervention between July 2015 and April 2017. The inclusion criteria were as follows: patient age between 10 and 16, scoliosis (double curve or single thoracolumbar curve pattern) exceeding 10° by Cobb angle, complete radiographic and clinical

data. The exclusion criteria were as follows: single lumbar curve pattern, congenital curve, neuromuscular, rheumatologic, renal, cardiovascular, pulmonary or vestibular diseases, spinal tumor, surgical correction, or previously conservative therapy history.

A series of 76 patients met the above criteria. Each patient completed the four-month treatment period. Clinical characteristics of the patients regarding demographic data, medical history, grade, and type, location, and magnitude of the curves were recorded. The SRS assessment criteria of treatment success for individual curve reduction in AIS was reported to be 6 degrees or more Cobb angle from radiographic analysis.⁵ In the present study, individuals were divided into two groups based on the presence or absence of the radiographic success. The first group (N=38) consisted of patients with curve improvement, while the second group (N=38) consisted of patients with curve progression. Clinical outcomes regarding angle of trunk rotation with scoliometer of Bunnell, body asymmetry with Posterior Trunk Symmetry Index (POTSI) and trunk deformity with Walter Reed Visual Assessment Scale (WRVAS) was compared between this two groups. All assessments were measured at baseline and after 4-month treatment period.

Cobb angle is considered the gold standard for determining the magnitude of spinal curve on the frontal-plane radiograph.¹

The angle of trunk rotation (or Bunnell angle) was measured with scoliometer in the Adam's forward-bending position. The scoliometer is an inclinometer that measures the asymmetries between the sides of the trunk in axial rotation degrees.¹⁶ This method has been reported to have high intra-observer reliability.¹⁷

The POTSI includes the sensitive assessment of the frontal-plane asymmetry of trunk deformity as a two-dimensional surface topographic method in scoliosis. The index based on assessing trunk asymmetry with regard to C7 plumb line, shoulder and hip asymmetry based on back surface photograph of patient. The ideal POTSI score is zero, which represents full symmetry of the back surface. Higher scores indicate an increasing asymmetry of the trunk.¹⁸

The WRVAS assesses the patient's

cosmetic trunk deformity with a set of figures representing seven visible aspects of spinal deformity: spinal deformity, rib prominence, lumbar prominence, thoracic deformity, trunk imbalance, shoulder asymmetry, and scapular asymmetry. Each item is scored from 1 to 5, with higher scores reflecting worsening deformity. Results are presented as the sum of the seven items.¹⁹ The WRVAS scale was completed by the physiotherapist, the patient and her/his parent.

The study was approved by the University of Hacettepe Research Ethics Board GO 16/82 on March 22, 2016.

Rehabilitation

For mild curves conservative treatment includes exercise (<20° of Cobb) while conservative treatment of moderate curves (Cobb angle 20°-45°) is combined spinal bracing and exercise approaches in AIS.²⁰ In the present study, custom-made spinal braces were used for the patients in order to correct the lateral deviation and rotational components of the scoliotic deformity. The thoraco-lumbosacral brace based on the symmetric, patient-oriented, rigid, three-dimensional, active concept.²¹ We applied specific exercises (SEAS) that already showed to be useful in adolescent idiopathic scoliosis. SEAS consist of individually adapted exercises based on active self-correction and its stabilization in several functional movements.²²

Statistical analysis

The data was not normally distributed as tested using the Kolmogorov-Smirnov test. Therefore, comparison of the clinical outcomes between the two groups was performed using Mann-Whitney U test. The Wilcoxon Signed Rank Test was used to test changes from baseline within each group. Data were expressed as means (X) and standard deviations (SDs). p values <0.05 were considered statistically significant. Analyses were done with SPSS for Windows, version 11.0 (SPSS Inc., Chicago, IL).

RESULTS

The mean age of 76 patients was 14.0 (1.6) years (range, 10-16). According to the curve pattern classification, there were forty-eight patients with right thoracic left lumbar curves

and 28 patients with single thoracolumbar curves, totally. The mean measurement of the thoracic curve was 29.2° (8.4°) (range, 13°-48°) and the mean measurement of the lumbar curve was 27.0° (9.4°) (range, 11°-50°). Patient characteristics according to the groups were given in Table 1.

There was no statistical significance between the groups in terms of any baseline patient characteristics or outcome measures. Thoracic and lumbar Cobb angles, thoracic and lumbar angle of trunk rotations, body symmetry and cosmetic trunk deformity for the physiotherapist showed improvement in both curve improvement and curve progression groups. Cosmetic trunk deformity from the patient's perspective did not change in any groups. However, cosmetic trunk deformity from the parent's perspective improved in the curve improvement group (Table 2).

Between group comparisons revealed significant difference in lumbar Cobb angles for the post-treatment assessment. Improvement in lumbar Cobb angle was greater in the curve improvement group than the curve progression group (Table 2). In the comparison of mean WRVAS scores of all 76 patients among physiotherapist, patients and their parents, only physiotherapists' scores significantly different from the others at baseline. From physiotherapist perspective, patients had higher scores than patients' and parents' perspective. Patients and parents scores were similar about cosmetic trunk deformity at baseline (Figure 1).

DISCUSSION

Our results indicate that clinical measure outcomes regarding the angle of trunk rotation, back asymmetry and cosmetic trunk deformity improved with four-month conservative treatment regardless of the radiological curve success in patients with AIS. Even patients who had curve progression according to SRS criteria had improvement in clinical parameters.

Several techniques have been proposed to quantitatively assess scoliosis for screening and follow-up purposes. But the Cobb angle is the only widely-accepted objective criteria for the screening, diagnosis, and evaluation of the

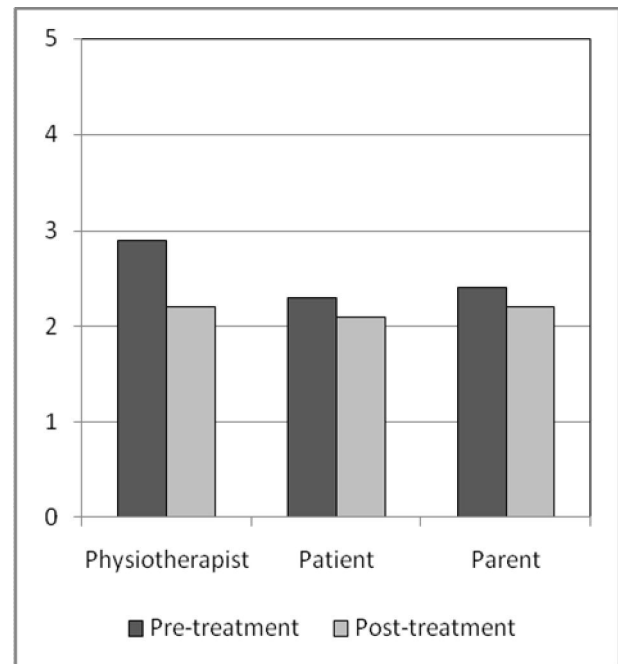


Figure 1. Comparison of physiotherapist, patient, and parent The Walter Reed Visual Assessment Scale scores at pre- and post-treatment.

curve during grow-up process in scoliosis currently available.¹ But also the main clinical tools for assessing trunk morphology in scoliosis are shoulder and hip asymmetry, which can be objectively measured with surface topography using POTSI index,¹⁸ and axial trunk rotation using scoliometer.¹⁶ In this study, both curve improvement and curve progression groups had improvement in trunk symmetry and axial trunk rotation. These results showed that the treatment improved clinical outcomes of trunk morphology in spite of a progression of curve. Clinical measurements, such as axial trunk rotation, POTSI index have shown to have weak correlations with radiographic values, such as Cobb's angle in previous studies.^{23,24} However, Pratt et al. demonstrated higher correlation between greater thoracic-lumbar Cobb's angle and trunk asymmetry.²⁵

From the physiotherapist's perception on body appearance, cosmetic deformity improved both group as independently the radiological success in the study. Similarly, it was previously demonstrated that WRVAS scores does not correlate with the radiological deformity.¹² Wang et al. reported negative correlation between self-image perception as

Table 1. Patient characteristics.

	Curve Improvement (N=38) Mean (SD)	Curve Progression (N=38) Mean (SD)	p
Age (years)	14.1 (1.7)	13.9 (1.4)	0.455
Height (cm)	159.6 (9.4)	158.3 (9.6)	0.330
Body weight (kg)	48.1 (8.8)	48.7 (14.7)	0.875
Body Mass Index (kg/m ²)	18.8 (2.9)	19.1 (4.1)	0.834
Risser grade	2.4 (0.6)	2.4 (0.6)	0.740
	n (%)	n (%)	
Curve pattern			
Right thoracic left lumbar	26 (68)	22 (58)	0.342
Single thoracolumbar	12 (32)	16 (42)	
Intervention			
Exercise	11 (29)	8 (21)	0.427
Brace and exercise	27 (71)	30 (79)	

Table 2. Main outcome measures by group at the pre- and post-treatment assessments.

	Pre-treatment		Post-treatment		Actual mean difference	
	Curve Improvement Mean (SD)	Curve Progression Mean (SD)	Curve Improvement Mean (SD)	Curve Progression Mean (SD)	Curve Improvement Mean (SD)	Curve Progression Mean (SD)
Cobb's angle (°)						
Thoracic	29.6 (9.2)	28.7 (7.4)	24.2 (9.3)	27.1 (7.9)	-5.4 (2.6) ^a	-1.7 (3.0) ^a
Lumbar	25.9 (10.4)	28.4 (8.1)	21.6 (9.6)	26.4 (8.5) ^b	-4.3 (2.4) ^a	-2.1 (1.4) ^a
Rotation (°)						
Thoracic	10.6 (4.7)	10.2 (8.9)	7.7 (4.6)	7.2 (4.3)	-3.0 (2.5) ^a	-2.9 (6.8) ^a
Lumbar	6.5 (2.4)	9.5 (4.6)	3.1 (2.5)	6.9 (5.4)	-3.4 (1.7) ^a	-2.6 (3.8) ^a
POTSI	30.0 (12.5)	32.6 (11.4)	19.6 (10.8)	22.8 (12.9)	-10.4 (8.2) ^a	-9.7 (11.1) ^a
Walter Reed VAS						
Physiotherapist	2.9 (0.6)	2.8 (0.5)	2.2 (0.5)	2.2 (0.5)	-0.8 (0.5) ^a	-0.6 (0.5) ^a
Patient	2.2 (0.6)	2.4 (0.4)	2.1 (0.4)	2.2 (0.3)	-0.1 (0.5)	-0.2 (0.4)
Parent	2.4 (0.6)	2.4 (0.6)	2.1 (0.6)	2.4 (1.3)	-0.3 (0.7) ^a	0.0 (1.4)

^a p<0.05 within group differences. ^b p<0.05 between group differences.

Rotation: Angle of trunk rotation. POTSI: Posterior Trunk Symmetry Index. Walter Reed VAS: Walter Reed Visual Assessment Scale.

determined by SRS-22 questionnaire and main Cobb angle in Chinese female AIS patients.²⁶ In another study, WRVAS scores found to be correlated significantly with curve magnitude and treatment in 182 idiopathic scoliosis patients. In addition they reported that patients and parent had similar scores.¹⁹ The present study does not support the idea that clinical tools, including surface topographic methods may be used with the aim of reducing the need for radiographies, in order to decrease

the exposure to radiations in the growing age.²⁷ As our study demonstrated, clinical measures of deformity correction do not seem to show radiological measures of deformity correction in the follow up of scoliosis patients, which are comparable with those in previous studies.^{12,23,24,26}

From the perspective of patients and parents, feelings about appearance play a considerable role in determining their willingness to undergo treatment and the

extent to which they consider treatment successful.²⁸ In the present study, patient and parent perceive cosmetic trunk deformity similarly, whereas physiotherapist had higher scores than others at baseline. But Sanders et al. reported a high correlation between parents' and children's scores on the WRVAS.¹⁹ Pratt et al. compared parents' and patients' perceptions on cosmetic deformity before and after surgery for AIS.²⁵ They found greater scores for parents than for patients before surgery and decrease in scores 2-year after surgery as compared with preoperative values for both parents and patients. In our study, there was no statistical change observed in patients' perception neither curve improvement nor curve progression group. Even in the curve improvement group, clinical correction combined with the radiological success appears not to be an attractive therapy effect for the patients. Similarly, Matamalas et al. reported that patient expectations regarding improvement with treatment are not directly related to actual clinical imbalance.²⁹ However, White et al. reported a relation between pre-operative Cobb angle, surgical correction amount and self-image of patients following surgical intervention.³⁰ Furthermore, Misterska et al. found better trunk appearance perception for the patient with parallel to surgical correction.³¹ From parent's perspective, there was improvement in cosmetic deformity only for the curve improvement group whereas it did not change in curve progression group. As supported by the Rinella et al,³² our analysis revealed that parent's observations might not accurately portray the patient's experience for self-image or satisfaction with treatment in AIS.

Limitations

The study has the following limitations: The study population had double curve or single thoracolumbar curve pattern scoliosis, had different curve magnitudes of patients and for four-month follow-up period. The study group was limited to female adolescents. The study results may not be generalizable to other curve patterns or for long-time treatment period until skeletal maturity. Despite these limitations, the study had several strengths, including the use of a specific curve pattern sample, similar patients' characteristics at baseline, and relatively good sample size. The

results of this study suggest that clinical outcome data are required when evaluating results of conservative scoliosis treatment.

Conclusion

Results from the present study support the usefulness of the clinical measurements, as well as radiographical assessments, for describing both radiological and clinical scoliotic deformity and for evaluating the effects of treatment in AIS. From the patient's perspective, it seems that the conservative treatment seems not to be capable to improve cosmetic trunk appearance, even if the deformity improved.

Acknowledgement: *Authors want to thank you Dr. Erkan Sümer for reviewing the spine radiographs.*

Conflict of interest: *None.*

Funding: *None.*

REFERENCES

1. Cobb JR. Outline for the study of scoliosis. In AAOS, Instructional Course Lectures Volume 5 Edited by: Edwards JW Ann Arbor. 1948: 261-275.
2. Lonstein JE, Carlson J. The prediction of curve progression in untreated idiopathic scoliosis during growth. *J Bone Joint Surg Am.* 1984;66:1061-1071.
3. Raso VJ, Lou E, Hill DL, et al. Trunk distortion in adolescent idiopathic scoliosis. *J Pediatr Orthop.* 1998;18:222-226.
4. D'andrea LP, Betz RR, Lenke LG, et al. Do radiographic parameters correlate with clinical outcomes in adolescent idiopathic scoliosis? *Spine.* 2000;25:1795-1802.
5. Richards BS, Bernstein RM, D'amato CR, et al. Standardization of criteria for adolescent idiopathic scoliosis brace studies: SRS Committee on Bracing and Nonoperative Management. *Spine.* 2005;30:2068-2075.
6. Vasiliadis E, Grivas TB. Quality of life after conservative treatment of adolescent idiopathic scoliosis. *Stud Health Technol Inform.* 2008;135:409-413.
7. Rigo M. Patient evaluation in idiopathic scoliosis: Radiographic assessment, trunk deformity and back asymmetry. *Physiother*

- Theory Pract. 2011;27:7-25.
8. Patias P, Grivas TB, Kaspiris A, et al. A review of the trunk surface metrics used as Scoliosis and other deformities evaluation indices. *Scoliosis*. 2010;5:12-32.
 9. Weiss HR. Measurement of vertebral rotation: Perdrille versus Raimondi. *Eur Spine J*. 1995;4:34-38.
 10. Upadhyay S, Burwell R, Webb K. Hump changes on forward flexion of the lumbar spine in patients with idiopathic scoliosis: a study using ISIS and the scoliometer in two standard positions. *Spine*. 1988;13:146-151.
 11. Bago J, Sanchez-Raya J, Perez-Grueso FJS, et al. The Trunk Appearance Perception Scale (TAPS): a new tool to evaluate subjective impression of trunk deformity in patients with idiopathic scoliosis. *Scoliosis*. 2010;5:6-15.
 12. Bago J, Climent JM, Pineda S, et al. Further evaluation of the Walter Reed Visual Assessment Scale: correlation with curve pattern and radiological deformity. *Scoliosis*. 2007;2:12-19.
 13. Morrison DG, Chan A, Hill D, et al. Correlation between Cobb angle, spinous process angle (SPA) and apical vertebrae rotation (AVR) on posteroanterior radiographs in adolescent idiopathic scoliosis (AIS). *Eur Spine J*. 2015;24:306-312.
 14. Yang S, Feuchtbaum E, Werner BC, et al. Does anterior shoulder balance in adolescent idiopathic scoliosis correlate with posterior shoulder balance clinically and radiographically? *Eur Spine J*. 2012;21:1978-1983.
 15. Smith JS, Shaffrey CI, Glassman SD, et al. Clinical and radiographic parameters that distinguish between the best and worst outcomes of scoliosis surgery for adults. *Eur Spine J*. 2013;22:402-410.
 16. Bunnell WP. An objective criterion for scoliosis screening. *J Bone Joint Surg Am*. 1984;66:1381-1387.
 17. Coelho DM, Bonagamba GH, Oliveira AS. Scoliometer measurements of patients with idiopathic scoliosis. *Braz J Phys Ther*. 2013;17:179-184.
 18. Inami K, Suzuki N, Ono T, et al. Analysis of posterior trunk symmetry index (POTSI) in scoliosis. Part 2. *Stud Health Technol Inform*. 1999;59:85-88.
 19. Sanders JO, Polly Jr DW, Cats-Baril W, et al. Analysis of patient and parent assessment of deformity in idiopathic scoliosis using the Walter Reed Visual Assessment Scale. *Spine*. 2003;28:2158-2163.
 20. Romano M, Minozzi S, Bettany-Saltikov J, et al. Exercises for adolescent idiopathic scoliosis. *Cochrane Database Syst Rev*. 2012;8:1-31.
 21. Gur G, Dilek B, Ayhan C, et al. Effect of a spinal brace on postural control in different sensory conditions in adolescent idiopathic scoliosis: A preliminary analysis. *Gait Posture*. 2015;41:93-99.
 22. Negrini S, Negrini A, Romano M, et al. A controlled prospective study on the efficacy of SEAS. 02 exercises in preventing progression and bracing in mild idiopathic scoliosis. *Stud Health Technol Inform*. 2006;123:523-526.
 23. Grosso C, Negrini S, Boniolo A, et al. The validity of clinical examination in adolescent spinal deformities. *Stud Health Technol Inform*. 2001;91:123-125.
 24. Kotwicki T, Kinel E, Stryla W, et al. Discrepancy in clinical versus radiological parameters describing deformity due to brace treatment for moderate idiopathic scoliosis. *Scoliosis*. 2007; 2:18-26.
 25. Pratt RK, Burwell RG, Cole AA, et al. Patient and parental perception of adolescent idiopathic scoliosis before and after surgery in comparison with surface and radiographic measurements. *Spine*. 2002;27:1543-1550.
 26. Wang L, Wang Y, Yu B, et al. Relation between self-image score of SRS-22 with deformity measures in female adolescent idiopathic scoliosis patients. *Orthop Traumatol Surg Res*. 2014;100:797-801.
 27. Goldberg CJ, Kaliszer M, Moore DP, et al. Surface topography, Cobb angles, and cosmetic change in scoliosis. *Spine*. 2001;26:E55-E63.
 28. Smith PL, Donaldson S, Hedden D, et al. Parents' and patients' perceptions of postoperative appearance in adolescent idiopathic scoliosis. *Spine*. 2006;31:2367-2374.
 29. Matamalas A, Bagó J, D'Agata E, et al. Does patient perception of shoulder balance correlate with clinical balance? *Eur Spine J*. 2016;25:3560-3567.
 30. White SF, Asher MA, Lai S-M, et al. Patients' perceptions of overall function, pain, and appearance after primary posterior instrumentation and fusion for idiopathic scoliosis. *Spine*. 1999;24:1693-1700.
 31. Misterska E, Glowacki M, Harasymczuk J. Assessment of spinal appearance in female patients with adolescent idiopathic scoliosis treated operatively. *Med Sci Monit*. 2011;17:CR404-410.
 32. Rinella A, Lenke L, Peelle M, et al. Comparison of SRS questionnaire results submitted by both parents and patients in the operative treatment of idiopathic scoliosis. *Spine*. 2004;29:303-313.