

Spontaneous Renal Cholesterol Crystal Embolism In A Patient with Functionally Solitary Kidney

Kenan Celik¹, Abdullah Sumnu², Meltem Gursu², Abdullah Sakin¹, Sami Uzun², Savas Ozturk², Rumez Kazancioglu³

ABSTRACT

Renal cholesterol crystal embolism (also called renal atheroembolism) is a cause of acute kidney injury with increasing frequency. It is usually seen in patients older than 60 years of age with diffuse atherosclerotic disease. Although it develops usually following vascular interventions; it may occur spontaneously. It presents with partial or total occlusion of small arteries due to distal embolization from cholesterol crystals from ruptured atherosclerotic plaques. It is in fact a part of systemic disease called cholesterol crystal embolization disease affecting kidneys, eyes, brain and gastrointestinal system. Livedo reticularis, especially purple discoloration of toes are clues for diagnosis. The pathognomonic finding of renal cholesterol crystal embolism is the cholesterol crystal clefts in renal biopsy specimen. Herein, we present a atypical case of acute kidney injury due to spontaneous cholesterol crystal embolization in a patient with functionally solitary kidney.

Key words: Acute kidney injury, atheroembolic disease, renal cholesterol crystal embolism

Tek Böbrekli Bir Hastada Spontan Renal Kolesterol Kristal Embolisi

ÖZET

Renal kolesterol kristal embolizimi (renal ateroembolizm) akut böbrek hasarının artan nedenlerinden biridir. Genellikle yaygın ateroskleroza olan 60 yaşının üzerindeki hastalarda görülmektedir. Vasküler girişimler sonrasında ortaya çıkabileceği gibi spontan olarak da meydana gelebilir. Rüptüre aterosklerotik plaklardan serbestleşen kolesterol kristallerinin distaldeki küçük arterleri total yada parsiyel olarak tıkanması sonucu ortaya çıkmaktadır. Aslında sistemik bir hastalık olan, böbrekler, gözler, beyin ve gastrointestinal sistemi tutabilen kolesterol kristal embolizimi hastalığının bir parçasıdır. Livedo retikularis ve ayak parmaklarında mor renk değişiklikleri hastalığın ipuçları olabilir. Renal kolesterol kristal emboliziminin patognomonik bulgusu böbrek biyopsisinde kolesterol kleftlerinin gösterilmesidir. Bu yazıda fonksiyonel olarak tek böbrekli bir hastada spontan kolesterol kristal embolisine bağlı gelişen bir akut böbrek hasarı olgusu sunduk.

Anahtar kelimeler: Akut böbrek hasarı, atheroembolik hastalık, renal kolesterol kristal embolisi

INTRODUCTION

Renal cholesterol crystal embolism (RCCE; also called renal atheroembolism) is one of the reasons of acute kidney injury with increasing frequency. It usually occurs in patients older than 60 years of age with diffuse atherosclerotic disease (1). RCCE usually follows vascular interventions like arteriography, angioplasty and manipulation of aorta and other big vessels during vascular surgery (2,3). But some of the cases develop spontaneously (4,5). RCCE is in fact a part of the cholesterol

crystal embolization disease. Cholesterol crystal embolization disease presents with partial or total occlusion of small arteries due to rupture and then embolization of the content of an atherosclerotic plaque (6). It is a multisystemic disease affecting kidneys, eyes, skin, brain and gastrointestinal system. Livedo reticularis, especially purple discoloration of the toes are clues for the diagnosis. The pathognomonic finding of RCCE is the demonstration of crystal clefts in renal biopsy specimen (7). Herein we present a case of acute kidney injury

¹Haseki Training and Research Hospital, Department of Internal Medicine, Istanbul, Turkey, ²Haseki Training and Research Hospital, Department of Nephrology, Istanbul, Turkey, ³Bezmialem Vakıf University, Medical Faculty, Department of Nephrology, Istanbul, Turkey

Received: 09.10.2012, Accepted: 14.12.2013

Correspondence: Kenan Çelik
Haseki Eğitim ve Araştırma Hastanesi, 2. Dahiliye Kliniği, Adivar Caddesi, Aksaray, Fatih, Istanbul, Turkey
Phone: +905306959077 Fax: +90 212 5294463 E-mail: kcn_clk@hotmail.com

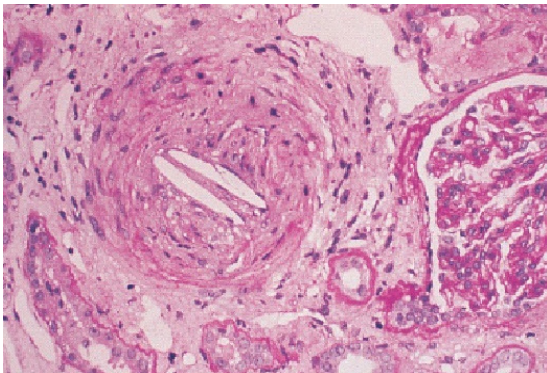


Figure. Cholesterol cleft in a large artery.

secondary to spontaneous RCCE in a patient with hypertension, ischemic heart disease and functionally solitary kidney.

CASE

A fifty-nine years old man admitted to the clinic due to abdominal pain and decreased amount of urine. The abdominal pain which was more prominent on the left side of the abdomen started suddenly four days ago and was a continuous pain. The laboratory tests in another center revealed that urea (140 mg/dl) and creatinin (7.6 mg/dl) levels were elevated. Then he was referred to our clinic where the urinary system ultrasonography revealed the sizes of the left and the right kidneys as 111x73 mm and 76x32 mm, respectively, with the echogenity of both kidneys increased. He was admitted to the nephrology clinic after a trial of parenteral fluid infusion and forced diuresis due to continuing symptoms and oliguria. He had hypertension for three years and had coronary stent implantation after angiography two years ago. He had a history of smoking for ten years and was using lisinopril, hydrochlorothiazide, diltiazem and acetyl salicylic acid at the time of admission. There was no history of nocturia; use of nonsteroid anti-inflammatory agent or any other drug with potential nephrotoxicity; and any clue for diseases that may be associated with dehydration. The physical examination findings were normal except blood pressure of 160/90 mmHg, tenderness on the left upper quadrant of the abdomen and tenderness of the left costovertebral angle. Normal sinus rhythm was observed on electrocardiography. There were aortic calcifications on plain chest graph. Urine analysis revealed

proteinuria that was 1+ with dipstick examination; and many erythrocytes on microscopic examination of the sediment. The pathological biochemical results were as follows: Urea: 150mg/dl; creatinin: 9.1mg/dl; lactate dehydrogenase: 1294IU/ml; parathyroid hormone: 36 pg/ml; leukocyte count: 8900/mm³; hematocrit: 37% and sedimentation rate: 52 mm/hour. The antibody for hepatitis C virus was positive. Doppler ultrasound of the renal vasculature was normal. Antinuclear and anticardiolipin antibodies were negative; and complement levels were within normal limits.

Lisinopril and hydrochlorothiazide combination was stopped due to acute kidney injury. And the dose of diltiazem was increased. Doxazosine and nifedipin were added to the treatment schedule for the control of blood pressure; and atorvastatin which was stopped by the patient was restarted. He had hemodialysis treatment due to oliguria. He had an attack of upper gastrointestinal bleeding requiring transfusion of five units of packed red cells after the second hemodialysis session. Two actively bleeding ulcers were seen in the antrum and minor curvature in endoscopic examinations during which sclerotherapy was performed in the same session; and acetylsalicylic acid was stopped.

After a follow-up period of three weeks with hemodialysis renal biopsy was performed due to lack of recovery of renal functions. Eight of the total 18 glomeruli seen in the biopsy specimen were globally sclerotic. Capillaries were open and the basal membranes had normal thickness in nonsclerotic glomeruli. There was scattered infiltration of the interstitium with mononuclear cells and also fibrosis. There was hyalinosis of the arterioles. A cholesterol crystal cleft was observed in the lumen of a large vessel (Figure). Immunofluorescence examination was normal and there was no staining with Congo dye.

He was diagnosed as spontaneous RCCE superimposed on primary nephrosclerosis. His renal functions did not improve during follow-up and he is still on hemodialysis program three times a week.

DISCUSSION

With the increasing incidence of cardiovascular disease and so, vascular interventions; RCCE became a more frequent reason for acute kidney injury. It usually occurs in patients older than 60 years of age with diffuse atherosclerotic disease (1).The incidence was reported

to be 7.1% in a study examining 259 patients older than 60 years who were biopsied due to acute kidney injury (8). Although RCCE develops usually following vascular interventions like arteriography, angioplasty and manipulation of aorta and other big vessels during vascular surgery; it may occur spontaneously as in the presented case (2-5). Rare cases due to anticoagulant drugs and thrombolytic drugs have been reported (9, 10). The incidence of atheroembolic disease after angiography is not known exactly. It was reported to be 2% in a review examining patients who had renal angiography (11). The incidence of atheroembolism after diagnostic cardiac catheterization was reported as 1.4% among 1786 patients younger than 40 years; and the incidence of acute kidney injury due to renal atheroembolism was reported to be 0.9% (12).

Cholesterol crystal embolization disease is characterized usually by multiple emboli to small arteries. Cyanosis of the toes, livedo reticularis and gastrointestinal symptoms support the diagnosis in suspected cases. Eosinophilia, eosinophiluria and hypocomplementemia are the laboratory findings suggestive of RCCE. The laboratory findings are especially important in patients without recent aortic intervention or extra renal findings like in the presented case (13); but it should be kept in mind that eosinophilia and eosinophiluria may be seen with acute interstitial nephritis and systemic vasculitides. The prevalence of eosinophilia and eosinophiluria have been reported from 14% to 67% in the literature (2, 3). Hypocomplementemia has been reported as 39% in one series (14) while as lower in another study (15). Eosinophilia and hypocomplementemia are expected to resolve within a week if the atheroembolism does not recur (2, 13). There was no hypocomplementemia, eosinophilia or eosinophiluria in our case. This could be related with the delayed admission of the patient to our clinic namely at least four days.

The renal disease associated with cholesterol crystal embolization may present in the form of acute, subacute or chronic disease according to the amount of crystal embolized (2, 3, 15-17). Acute form is prominent deterioration in renal functions 1-2 weeks after the insulting procedure due to massive embolism. The subacute form which is the most common type, presents with progressive decline in renal functions weeks after the triggering event with periods of stable course. The least frequent form is the chronic form which has a clinical presentation similar to ischemic nephropathy

and nephrosclerosis i.e. chronic stable renal failure. The rapidly progressive clinic and the degree of renal failure which required hemodialysis in the presented case is consistent with the acute form of the disease. Although the presence of left loin pain, hematuria and elevated lactate dehydrogenase levels are clues for a possible renal artery thromboembolism; normal findings on renal Doppler ultrasound, lack of arrhythmia and the renal biopsy findings that did not revealed infarct all support the diagnosis of RCCE.

Whatever the clinical presentation is, renal biopsy is mandatory for the diagnosis. Although percutaneous renal biopsy provides small samples of tissue, more than 75% of cases can be diagnosed with this method (18). We detected scattered mononuclear inflammatory cells and fibrosis in the interstitial field and cholesterol cleft in one large artery (Figure). The biconvex needle shaped cleft in the occluded artery is the pathognomonic finding of RCCE (2,19). Perivascular inflammatory reaction involving eosinophils accompany frequently the intraluminal lesions (20). The differential diagnosis involves ischemic acute tubular necrosis and contrast nephropathy besides renal artery embolism and diseases associated with eosinophiluria that was mentioned before. Contrast nephropathy and ischemic acute tubular necrosis are expected to be reversible within 4-21 days of the treatment or removal of the offending factor.

There is no specific treatment for RCCE and prophylactic measures are of prime importance. The primary point is to narrow the indications for angiography and other vascular interventions in patients suspected to have severe atherosclerosis (21, 22). It is advisable to use non-invasive diagnostic methods or to use upper extremities in strongly indicated cases. Antiaggregant and statin treatment for underlying heart disease, control of blood pressure, cessation of smoking and glycemic control in diabetic patients are advised as secondary prophylaxis. Secondary prevention after an insult involves cessation of anticoagulant treatment if it was given (23). The presented patient was not using anticoagulants; and was not given heparin due to the suspected RCCE and the attack of gastrointestinal bleeding during his follow-up. The leading point in supporting care of these patients is the control of blood pressure. Uncontrolled accelerated hypertension is frequent in the course of RCCE (14, 17, 24). We needed to add drugs to control blood pressure also. Although the evidence is not strong enough, statins are recommended due to their plaque stabiliz-

ing effect (25, 26). Other components of the supportive therapy are nutritional support and dialysis when necessary. Although there are reports showing the benefit of steroid therapy (22, 27), we did not give steroid to our patient due to positive hepatitis C serology, recent gastrointestinal bleeding and the chronic changes in the biopsy specimen.

Unfortunately, the prognosis is not good and reflects the severity of the underlying vascular disease (2, 28). In a series of 354 patients; after two years of follow-up 33% of patients reached end stage renal failure while 28% of them died (3). In conclusion; RCCE should be thought as part of the differential diagnosis in elderly patients with atherosclerosis presenting with acute kidney injury in spite of lack of a triggering vascular intervention and diagnostic physical and laboratory findings.

REFERENCES

1. Scolari F, Bracchi M, Valzorio B, et al. Cholesterol atheromatous embolism: an increasingly recognized cause of acute renal failure. *Nephrol Dial Transplant* 1996; 11 (8): 1607-12
2. Thadhani RI, Camargo CA, Jr Xavier RJ, Fang LS. Atheroembolic renal failure after invasive procedures. Natural history based on 52 histologically proven cases. *Medicine (Baltimore)* 1995; 74: 350
3. Scolari F, Ravani P, Gaggi R, et al. The challenge of diagnosing atheroembolic renal disease: clinical features and prognostic factors. *Circulation* 2007; 116: 298
4. Baumann DS, McGraw D, Rubin BG, et al. An institutional experience with arterial atheroembolism. *Ann Vasc Surg* 1994; 8: 258
5. Scolari F, Ravani P, Pola A, et al. Predictors of renal and patient outcomes in atheroembolic renal disease: a prospective study. *J Am Soc Nephrol* 2003; 14: 1584
6. Tunick PA, Kronzon I. Atheroembolism. In: *Vascular Medicine. A Companion to Braunwald's Heart Disease*. Creager, M, Dzau, VJ, Loscalzo, J (Eds), Saunders (Elsevier), 2006
7. Smith MC, Ghose MK, Henry AR. The clinical spectrum of renal cholesterol embolization. *Am J Med* 1981;71:174-80
8. Fine MJ, Kapoor W, Falanga V. Cholesterol crystal embolization: a review of 221 cases in the English literature. *Angiology* 1987; 38 (10): 769
9. Hyman BT, Landas SK, Ashman RF, Schelper RL, Robinson RA. Warfarin-related purple toes syndrome and cholesterol microembolization. *Am J Med* 1987; 82 (6): 1233-7
10. Gupta BK, Spinowitz BS, Charytan C, Wahl SJ. Cholesterol crystal embolization-associated renal failure after therapy with recombinant tissue-type plasminogen activator. *Am J Kidney Dis* 1993; 21 (6): 659-62
11. Rudnick MR, Berns JS, Cohen RM, Goldfarb S. Nephrotoxic

risks of renal angiography: Contrast-media associated nephrotoxicity and atheroembolism-a critical review. *Am J Kidney Dis* 1994; 24: 713

12. Fukumoto Y, Tsutsui H, Tsuchihashi M, et al. The incidence and risk factors of cholesterol embolization syndrome, a complication of cardiac catheterization: a prospective study. *J Am Coll Cardiol* 2003; 42: 211
13. Wilson DM, Salazer TL, Farkouh ME. Eosinophiluria in atheroembolic renal disease. *Am J Med* 1991; 91: 186
14. Lye WC, Cheah JS, Sinniah R: Renal cholesterol embolic disease. Case report and review of the literature. *Am J Nephrol* 1993;13:489-93
15. Scolari F, Tardanico R, Zani R, et al. Cholesterol crystal embolism: A recognizable cause of renal disease. *Am J Kidney Dis* 2000;36:1089
16. Colt HG, Begg RJ, Saporito JJ, et al. Cholesterol emboli after cardiac catheterization. Eight cases and a review of the literature. *Medicine (Baltimore)* 1988; 67: 389
17. Dalakos TG, Streeten DHP, Jones D, Obeid A. "Malignant" hypertension resulting from atheromatous embolization predominantly of one kidney. *Am J Med* 1974; 57: 135
18. Smith MC, Ghose MK, Henry AR. The clinical spectrum of renal cholesterol embolization. *Am J Med* 1981; 71 (1): 174
19. Meyrier A, Buchet P, Simon P, et al. Atheromatous renal disease. *Am J Med* 1988; 85: 139
20. Richards AM, Eliot RS, Kanjuh VI, Bloemendaal RD, Edwards JE. Cholesterol embolism: A multiple-system disease masquerading as polyarteritis nodosa. *Am J Cardiol* 1965; 15: 696
21. Zuccala` A, Zucchelli P. A renal disease frequently found postmortem, but rarely diagnosed in vivo. *Nephrol Dial Transplant* 1997; 12: 1762-7
22. Belenfant X, Meyrier A, Jacquot C: Supportive treatment improves survival in multi visceral cholesterol crystal embolism. *Am J Kidney Dis* 1999; 33: 840-50
23. Bruns FJ, Segel DP, Adler S. Control of cholesterol embolization by discontinuation of anticoagulant therapy. *Am J MedSci* 1978; 275: 105-8
24. Kassirer J. Atheroembolic renal disease. *N Engl J Med* 1969; 280: 812-8
25. Woolfson RG, Lachmann H. Improvement in renal cholesterol emboli syndrome after simvastatin. *Lancet* 1998; 351: 1331-2
26. Waters D: Plaque stabilization: A mechanism for the beneficial effect of lipid-lowering therapies in angiographic studies. *Prog Cardiovasc Dis* 1994; 37: 107-20
27. Dahlberg PJ, Frecentese DF, Cogbill TH. Cholesterol embolism: Experience with 22 histologically proven cases. *Surgery* 1989; 105: 737-46
28. Mannesse CK, Klankestijn PJ, Man in't Veld AJ, Schalekamp MA. Renal failure and cholesterol crystal embolization: A report of 4 surviving cases and a review of the literature. *Clin Nephrol* 1991; 36: 240