

Huge Intestine in a Diabetic Elderly

Ömer Başar¹, Yaşar Tuna¹, Fuat Ekiz², Halil Erbiş³

A 82 year old man admitted to the hospital with abdominal distension and obstipation for two days. His past medical history revealed diabetes mellitus for 10 years but he denied anti-diabetic using. Six months before, he had been hospitalized with diagnosis of sub-ileus in another center and a colonoscopy was performed showing dilated intestinal loops with normal mucosa. Upper gastrointestinal endoscopy and intestinal barium radiography were within normal limits. On physical examination abdominal sounds were silent on auscultation and abdominal distension was present without sings of peritoneal irritation. Counter blood count and biochemical tests including renal function tests and liver enzymes were all normal other than serum glucose (217 mg/dl). X-ray of the abdomen revealed a huge dilated stomach (Figure 1). A nasogastric tube was inserted and oral intake was stopped. Two days later, repeated X-ray showed a huge dilatation of the colon (Figure 2). He was started parenteral nutrition, blood glucose was regulated with insulin and after starting parenteral neostigmine infusion abdominal distension regressed, he defecated and the dilated colon and stomach returned to normal in the control X-ray of the abdomen. The patient refused to be investigated for further examination with the diagnosis of diabetic autonomic neuropathy or intestinal pseudo-obstruction before discharging and he was lost to follow-up. In conclusion, clinicians should be aware of such debile patients who have a history of diabetes mellitus in differential diagnosis of intestinal obstruction (1).

REFERENCE

1. Fukudo S, Kuwano H, Miwa H. Management and pathophysiology of functional gastrointestinal disorders. *Digestion* 2012;85:85-9.

¹Akdeniz University School of Medicine, Department of Gastroenterology, Ankara, Turkey, ²Dişkapı Yıldırım Beyazıt Education and Research Hospital, Department of Gastroenterology, Ankara, Turkey, ³Pamukkale University School of Medicine, Department of Gastroenterology, Denizli, Turkey

Received: 14.07.2012, Accepted: 18.09.2012

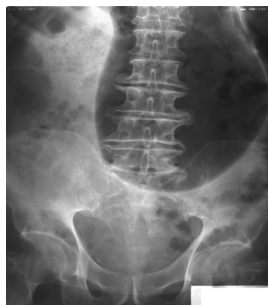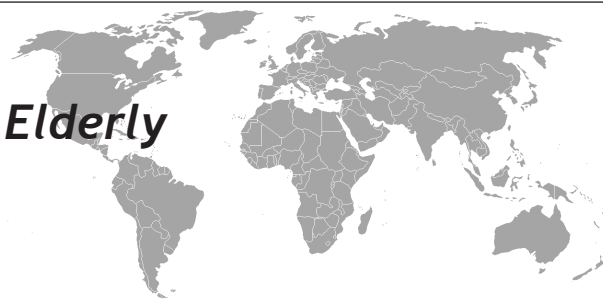


Figure 1. X-ray of the abdomen revealed a huge dilated stomach.

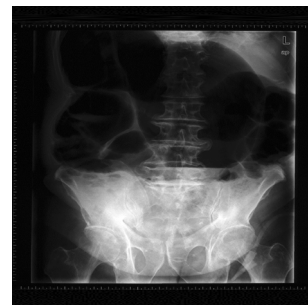

Figure 2. A nasogastric tube was inserted and oral intake was stopped. Two days later, repeated X-ray showed a huge dilatation of the colon

Correspondence: Ömer Başar, M. D.
Karargahtepe mah, Çamaltı sokak 41/3, 06120, Keçiören, Ankara, Turkey
E-mail: basaromer@hotmail.com Telephone: +90-312-5962911