

Pleurodesis for Refractory Left-Sided Pleural Effusion Due to Cardiomyopathy in a Patient with Right-Sided Destroyed Lung

Sezai Çelik, Cüneyt Aydemir, Ömer Işık

ABSTRACT

Benign pleural effusions are rarely treated with pleurodesis. We report a case of left-sided pleurodesis in a patient with right-sided destroyed lung. A 83-year-old man with right-sided destroyed lung was hospitalized because of recurrent left-sided massive pleural effusion due to cardiomyopathy. The patient was treated with left pleurodesis. He was then discharged from hospital and given diuretics therapy. At the one-year follow-up examinations, dyspnea and effusion had not recorded.

Key words: Cardiomyopathy, pleural effusion, pleurodesis.

Sağ Harap Akciğerli Bir Hastada Kardiyomiyopati Nedeni ile Gelişen Dirençli Plevra Efüzyonu için Plöredezis

ÖZET

Benign plevral efüzyonlar nadiren plöredez ile tedavi edilirler. Sağ destroyed akciğeri olan 83 yaşındaki hastada dilate kardiyomiyopatiye bağlı tekrarlayan sol plevral efüzyon plöredez yapılarak başarıyla tedavi edildi. Hasta diüretik tedavi ile evine taburcu edildi. Bir yıllık takibinde ise hastada nefes darlığı ve efüzyon tespit edilmedi.

Anahtar kelimeler: Kardiyomiyopati, plevra efüzyonu, plöredezis

INTRODUCTION

Pleural effusion is a medical condition with a significant source of morbidity and commonly seen in patients with congestive heart failure (1-3). Although pleurodesis has been studied widely accepted mode of treatment for malignant pleural effusion, (4,5) pleurodesis in nonmalignant cases of pleural effusion is less commonly performed and reported (6-8). In this report, we present a case of right-sided destroyed lung and recurrent left-sided massive pleural effusion due to cardiomyopathy who was treated with pleurodesis.

CASE

In September 2010, a 83-year-old man presented at our

hospital with a five-day history of progressively worsening dyspnea. He had been treated with intensive diuretic and positive inotropic therapy in intensive care unit five times, and the left pleural cavity had been evacuated by thoracentesis 12 times in the last four months. He had right destroyed lung because of pneumonia 40 years ago and heart failure three years ago. Examination of pleural effusion fluid revealed an absolute benign nature. The patient was a cachectic white man who was in serious respiratory distress with tachypnea of 40 breaths/min. Breath sounds were not present in the right lung, but heard in left upper lung. Heart sounds were heard in right hemithorax. Medical Research Council (MRC) dyspnea scale was 5. The patient's initial chest radiograph was interpreted as right atelectasis and left

Medicana hospitals, Department of Thoracic Surgery, Çamlıca, İstanbul, Turkey

Correspondence: Sezai Çelik

Medicana hospitals, Department of Thoracic Surgery, Çamlıca, İstanbul, Turkey

E-mail: heybeli@superonline.com

Received: 04.08.2012, Accepted: 05.02.2013

extensive pleural effusion (Figure 1). Two-dimensional echocardiogram showed an enlarged left ventricle and the ejection-fraction was 30%. Pulmonary artery pressure was 30 mmHg. Evaluative bronchoscopy showed inflammatory endobronchial changes but no bronchial strictures. Computed tomography scan of the chest with contrast revealed that in association with mediastinal shift and loss of total aeration in the right lung due to fibrosis, trachea and heart were deviated in right hemithorax and there was massive effusion in the left hemithorax. Since patient was symptomatic, resistant to all medical treatments, and had decreased quality of life, pleurodesis was planned. Patient was informed and gave consent for the procedure. During follow-up in intensive care unit, a PleurocanR catheter (B. Braun Melsungen AG, Germany) was inserted in the left hemithorax under local anesthesia with 10 cc 2% prilocaine and 1800 cc serous fluid was removed and complete re-expansion of the lung was obtained. Asbestos-free talc (4 g) were suspended in 50 mL of saline solution (0.9%) with 20 mL of 2% prilocaine and injected via the intercostal catheter into the pleural space. An additional 20 mL of saline solution was used to flush the catheter. The catheter was then closed, and the patient was asked to change position every 10 to 15 min to allow adequate distribution of talc. The catheter was removed 24 hours after complete rexpansion of the lung. The procedure was tolerated well except slight pleuritic chest pain. Patient was observed for 36 hours and discharged from hospital. The patient is now under follow-up for one year without recurrence. The lung is in full expansion (Figure 1) MRC dyspnea scale is 2.

DISCUSSION

The most common cause of transudative pleural effusion is congestive heart failure (9). In patients with congestive heart failure, pulmonary venous hypertension causes increased production of pleural fluid as an ultrafiltrate from the capillaries in the parietal pleura and decreased reabsorption of fluid into the capillaries of the visceral pleura, both leading to in pleural effusion. Although the incidence of heart failure is high and over half of these patients will develop pleural effusions during the course of their illness, there is no consensus on the treatment of recurrent benign pleural effusion (6-8). Here, we present a case of recurrent left-sided massive pleural effusion due to dilated cardiomyopathy

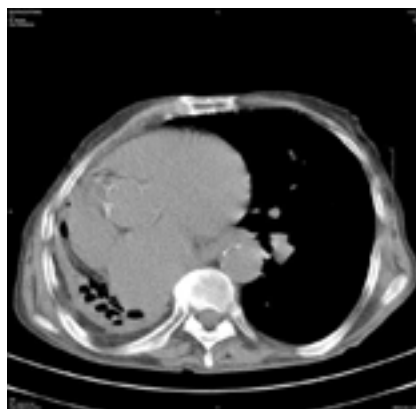


Figure 1. Chest computed tomography without contrast in 12-month of pleurodesis shows that in addition to right-sided destroyed lung, full expansion of left lung and slight pleural thickening in costodiaphragmatic angle

who was treated with pleurodesis. The patient was over 80 years of age, had destroyed lung and heart failure. In spite of complicating condition and age of the patient, we applied talc pleurodesis and no recurrence of pleural effusion or any side effect was recorded in the following year. There is limited number of studies on pleurodesis in patients with benign pleural effusion due to congestive heart failure, and conflicting results have been reported in these studies. In 1969, Spicer and Fisher successfully applied silver nitrate pleurodesis in a patient with recurrent pleural effusion. However, in 1983 Davidoff et al. (7) performed pleurodesis in two patients with recurrent right pleural effusion due to congestive heart failure. In the first patient, right pleurodesis with tetracycline resulted in adhesions and cessation of accumulation of fluid, however, this was followed by the appearance of left pleural effusion and the dyspnea did not improve. They performed right pleurodesis with quinacrine hydrochloride in the second patient. Although right effusion did not recur, a large pleural effusion appeared on the left side and repeated pleurocentesis was necessary during 18-month follow-up. On the other hand, in a partly prospective analysis, Glazer et al. (8) found that talc pleurodesis is effective without causing effusion in contralateral lung in 16 patients with nonmalignant pleural effusion. In the present report, we presented a patient with destroyed lung in right hemithorax leading to serious cardiac and me-

diastinal shift which was associated with recurrent left-sided massive pleural effusion. We effectively applied talc pleurodesis in this patient. No clinical or radiologic recurrence or any other complication was recored in one-year follow-up.

This is the first reported case of right destroyed lung and recurrent pleural effusion successfully treated with talc pleurodesis in English literature. The patients with benign recurrent pleural effusion complicated with other conditions should be evaluated carefully with invasive and non-invasive tools, and medical treatment and follow-up should be determined accordingly.

REFERENCES

1. Ahmad Z, Krishnadas R, Froeschle P. Pleural effusion: diagnosis and management. *J Perioper Pract* 2009;19:242-7.
2. Ahmad K, Gandhi MS, Smith WC, Weber KT. Bilateral pleural effusions in congestive heart failure. *Am J Med Sci* 2008;335:484-8.
3. Porcel JM. Establishing a diagnosis of pleural effusion due to heart failure. *Respirology* 2009;14:471-3.
4. Zahid I, Routledge T, Bille A, Scarci M. What is the best treatment for malignant pleural effusions? *Interact Cardiovasc Thorac Surg* 2011;12:818-23.
5. Trotter D, Aly A, Siu L, Knight S. Video-assisted thoracoscopic (VATS) pleurodesis for malignant effusion: an Australian teaching hospital's experience. *Heart Lung Circ* 2005;14:93-7.
6. Spicer AJ, Fisher JA. Recurring pleural effusion in congestive heart failure treated by pleurodesis. *J Ir Med Assoc* 1969;62:177-8.
7. Davidoff D, Naparstek Y, Eliakim M. The use of pleurodesis for intractable pleural effusion due to congestive heart failure. *Postgrad Med J* 1983;59:330-1.
8. Glazer M, Berkman N, Lafair JS, Kramer MR. Successful talc slurry pleurodesis in patients with nonmalignant pleural effusion. *Chest* 2000;117:1404-9.
9. Kinasewitz GT. Transudative effusions. *Eur Respir J* 1997;10:714-8.