

# Imaging Features of Isolated Unilateral Pulmonary Artery Agenesis

Abdussamet Batur<sup>1</sup>, Kemal Ödev<sup>1</sup>, Sevgi Pekcan<sup>2</sup>

## ABSTRACT

To highlight the variation in imaging and clinical manifestations of four cases of isolated unilateral absence of pulmonary artery presented in varied ages. Four patients with unilateral pulmonary artery agenesis were referred to our institution They underwent a series of investigations, including chest radiography, computed tomography and magnetic resonance imaging. Two of the four patients had absence of the right main pulmonary artery, while the remaining two patients had absence of the left main pulmonary artery. All patients showed a restrictive defect on pulmonary function tests. Radiography, CT and MRI confirmed the anatomy and the presence of multiple collaterals. Isolated unilateral pulmonary artery agenesis has a non-specific presentation. Awareness of this condition can lead to earlier diagnosis, with cross-sectional imaging making an important contribution.

**Key words:** Pulmonary artery agenesis, radiologic findings, clinical features

## İzole Pulmoner Arter Agenesisinin Görüntüleme Özellikleri

### ÖZET

Farklı yaş ve farklı klinik bulgularla başvuran izole tek taraflı pulmoner arter agenezili dört olgunun radyolojik bulgularını sunmak. İzole taraflı pulmoner arter agenezisi tanımlı dört hastanın klinik bilgileri ile birlikte direkt grafi, bilgisayarlı tomografi (BT) ve manyetik rezonans görüntüleme (MRG) bulguları değerlendirildi. İki olguda sağ pulmoner arter yokluğu, diğer iki olguda ise sol pulmoner arter yokluğu izlendi. Tüm hastaların solunum fonksiyon testlerinin hafif düzeyde restriktif paternle uyumlu olduğu görüldü. Direkt grafi, BT ve MRG tetkiklerinde akciğerlerin anatomik yapısı ve gelişen kollateral yapılar görüntülendi. İzole tek taraflı pulmoner arter agenezisi olan olgular spesifik olmayan semptomlarla başvururlar. Dikkatli bir yaklaşımla bu hastalarda erken tanıya gidilebilir. Görüntüleme yöntemleri oldukça yararlı bilgiler sağlamaktadır.

**Anahtar kelimeler:** Pulmoner arter agenezisi, radyolojik bulgular, klinik özellikler

## INTRODUCTION

Isolated unilateral absence of pulmonary artery (UAPA) is observed at a rate of 1/200.000. It is a rare congenital anomaly occurring due to the lack of development of sixth aortic arch (1). In 37% of patients the left pulmonary artery was absent while the right was absent in 63% of patients (2). As some patients may remain asymptomatic, advanced pulmonary hypertension or congestive heart failure may occur with some of them. Patients usually present with recurrent respiratory infections,

dyspnea or hemoptysis (3). We describe here four cases of isolated unilateral absence of pulmonary artery with their clinical findings.

## CASE 1

A 18 year old girl admitted due to bruising fingers and lips. She was treated for lung infection but her complaints did not decline. Her personal history did not have anything worth noting. Except rhonchus in the

Necmettin Erbakan University, Meram School of Medicine, Department of Radiology<sup>1</sup> and Pediatric Chest Diseases<sup>2</sup>, Konya

Received: 30.10.2012, Accepted: 17.12.2012

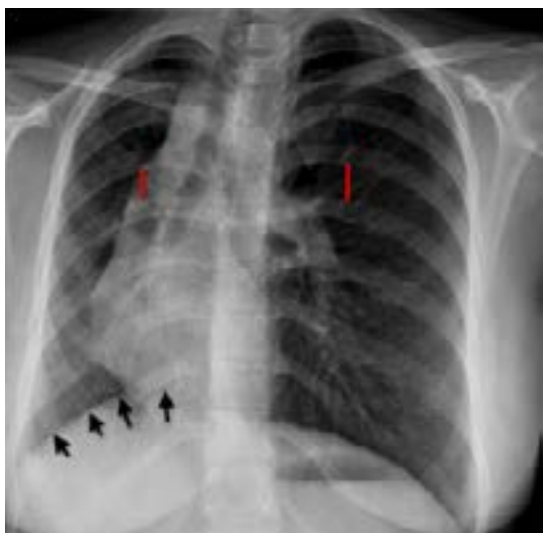Correspondence: Dr. Abdussamet Batur

Necmettin Erbakan University, Meram School of Medicine, Department of Radiology, Konya,

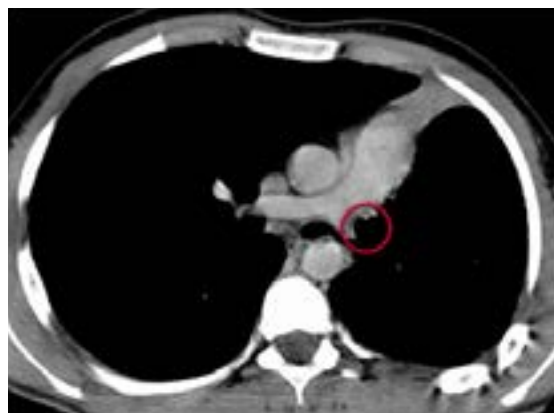right lung and a FEF 25-75 decrease suggesting small airways stenosis, there was no abnormality on her physical examination and laboratory findings. Echocardiography excluded cardiac and vascular anomalies. In the posterior-anterior (PA) lung x-ray of the patient, the volume of the right hemithorax was observed to be decreased, the mediastinum was deviated to the right and ipsilateral hemidiaphragm was elevated. The left pulmonary artery was significant while the right pulmonary artery was observed to be absent. Intercostal bone spaces were small on the right hemithorax (Figure 1).

### CASE 2

A 15 year old boy, has been followed up for IgA deficiency, admitted to the hospital with recurrent cough. His physical examination, laboratory findings and imaging findings were thought to be stemmed from pneumonia caused by IgA deficiency. In the respiratory function tests, FEV1/FVC ratio was found compatible with mild restrictive pattern. Computed tomography (CT) scan revealed the absence of the left pulmonary artery (Figure 2).



**Figure 1.** Radiography demonstrates decreased right hemithorax volume, the deviated mediastinum to the right, ipsilateral hemidiaphragm elevation (short arrows), significant left pulmonary artery (thick arrow), absence of right pulmonary artery and small intercostal bone spaces on the right hemithorax (sticks).



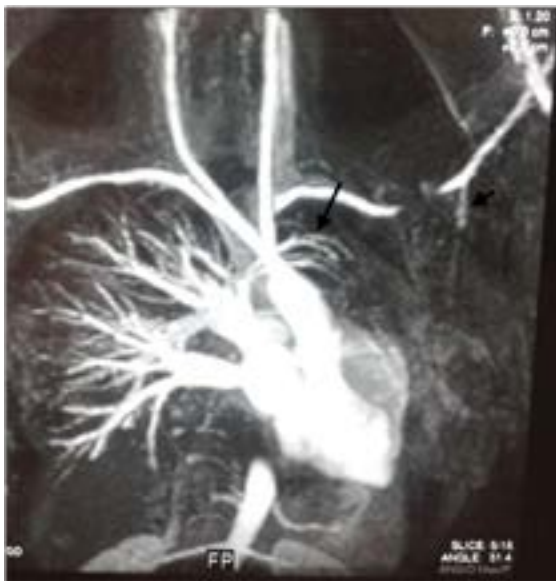**Figure 2.** Computed tomography demonstrates the absence of the left pulmonary artery (in circle).

### CASE 3

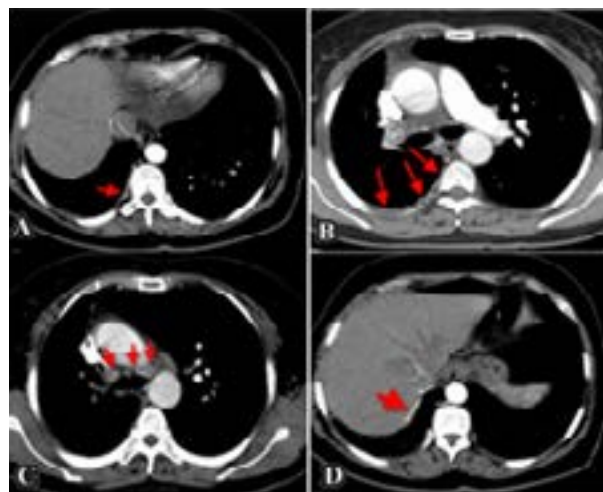
Our third case was a 26 year old male admitted with intermittent fatigue, malaise and shortness of breath upon exertion continued for eleven years and mild hemoptysis that started a month ago. On inspection, patient's left hemithorax's participation in respiration was limited and it was smaller than the right hemithorax. Other physical examination and laboratory findings were within normal limit. The respiratory function tests were compatible with restrictive pattern. Magnetic resonance angiography (MRA) showed the absence of left pulmonary artery and revealed the left subclavian artery with the branches of the right pulmonary artery feeding hypoplastic left lung (Figure 3).

### CASE 4

A 52 year old woman admitted with shortness of breath on exertion continued for ten years. Coughing, chest fullness and chest pain occurred since last month. On physical examination, her right hemithorax's participation in respiration was limited and the right hemithorax was smaller than left. CT scans revealed the absence of right pulmonary artery with collaterals from bronchial, intercostals, left pulmonary artery and subdiaphragmatic arteries (Figure 4A, B, C, D).



**Figure 3.** Magnetic resonance angiography demonstrates the absence of left pulmonary artery and the collaterals originating from left subclavian artery (short arrow) and right pulmonary artery (long arrow).



**Figure 4A, B, C, D.** Computed tomography demonstrates the absence of right pulmonary artery with collaterals from bronchial (short arrow), intercostals (long arrows), left pulmonary artery (short arrows) and subdiaphragmatic arteries (thick arrow), respectively.

## DISCUSSION

Unilateral absence of pulmonary artery is a very rare congenital abnormality and is frequently associated with other cardiovascular anomalies such as septal defects, right aortic arch, tetralogy of Fallot and persistence of ductus arteriosus (4). Some reports state that 30% of patients are asymptomatic and are diagnosed by imaging modalities obtained for other reasons. As in our 4th patient, she was asymptomatic until the age of 42. It is reported that patients who are not accompanied by cardiovascular anomalies are remained asymptomatic (3). Although cardiology consultation did not observe such anomalies, all of our cases had nonspecific symptoms and this led to a considerable delay between the onset of symptoms and the final diagnosis. When symptomatic, patients with isolated UAPA commonly experience dyspnea on exertion, recurrent respiratory infections and decrease in exercise tolerance. Although the infections are usually mild, they may have devastating effects, such as necrotizing pneumonia, leading to pneumonectomy. It has been suggested that alveolar hypocapnia causing bronchoconstriction, and impaired mucociliary clearance may contribute to the high inci-

dence of infections in patients with UAPA. Hemoptysis occurs in about 20% of cases and can be self-limiting for many years, but may also lead to massive pulmonary hemorrhage and death. Hemoptysis was seen only in the 3th case and it was mild and self-limiting. Bleeding develops due to dilated systemic collaterals such as bronchial, intercostals, subclavian or subdiaphragmatic arteries (3). Systemic circulation can cause right to left shunt and heart failure can be seen due to shunt in the elderly (1). Physical examination may reveal decreased breath sounds, a shrunken affected hemithorax, scoliosis, and displacement of the cardiac apex. Pulmonary function tests (PFT) can show no significant changes, or mild restrictive defect can be seen (5). Delineated physical examination and chest radiography findings, and PFTs showing mild restrictive changes due to a decrease in lung volume were observed in all our cases. The radiography is the first imaging modality to be used in the diagnosis of unilateral absence of the pulmonary artery. The chest radiograph findings consist of ipsilateral hemidiaphragm elevation, loss of the hilar shadow on the affected side, ipsilateral cardiac and mediastinal displacement, contralateral lung hyperinflation and a small hemithorax (6). Pulmonary arteriography, which

can detect cardiac functions and congenital anomalies, is the gold standard for the diagnosis of UAPA (5). Computed tomography (CT) can reveal the absence of the pulmonary artery, presence of bronchiectasis and collaterals (4).

Swyer-James-MacLeod (SJM) syndrome should be considered in the differential diagnosis of pulmonary artery agenesis. Perfusion scintigraphy or pulmonary angiography can be used for the differentiation. The pulmonary artery is hypoplastic in patients with SJM syndrome and ipsilateral lung perfusion is absent. On the other hand, pulmonary artery can not be observed in patients with UAPA, but peripherally perfusion can be seen via collaterals (1). Asymptomatic patients do not require therapy. Treatment is applied in case of infection or hemoptysis. Selective embolization of the bronchial and non-bronchial systemic arteries is an indicated procedure for the management of massive hemoptysis in patients who can not tolerate surgery. Patients with pulmonary hypertension are treated with digital and diuretics. Pneumonectomy of the affected side can be done in presence of recurrent pulmonary infection or massive hemoptysis (4,5). UAPA may be suspected by the presence of recurrent respiratory infections, pulmonary hypertension or hemoptysis. The diagnosis can be made by chest radiography. The presence of bronchiectasis and collateral arteries can be discerned by CT scanning and MRI.

## REFERENCES

1. Okutan O, Ugan H, Kaya H, et al. Isolated Unilateral Pulmonary Artery Agenesis. *Turkish Cardiovasc Thorax Surg J* 2010;18(1): 67-70.
2. Bouros D, Pare P, Panagou P, Tsintiris K, Siafakas N. The varied manifestation of pulmonary artery agenesis in adulthood. *Chest* 1995; 108: 670-6.
3. Ten Harkel AD, Blom NA, Ottenkamp J. Isolated unilateral absence of a pulmonary artery: A case report and review of the literature. *Chest* 2002; 122: 1471-7.
4. Mello Junior WT, Nogueira JRC, Santos M, França WJP. Isolated absence of the right pulmonary artery as a cause of massive hemoptysis. *Interact Cardiovasc Thoracic Surg* 2008; 7: 1183-5.
5. Bilgiç İ, Uçan ES, Krall WR, Ploy-Song-Sang Y. Unilateral pulmonary artery aplasia presenting with chest pain and pleural effusion. *South Med J* 1980; 73: 233-6.
6. Lin YM, Liang KW, Ting CT. Unilateral pulmonary artery-agenesis with presentation of hemoptysis: a case report. *Chung Hua I Hsueh Tsa Chih (Taipei)* 1999; 62:644-7