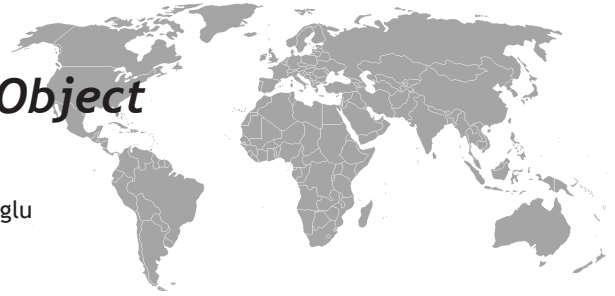


Cervical Foraminal Foreign Object



Olcay Eser, Alpay Haktanır, Mehmet Boyacı, Ergun Karavelioglu

ABSTRACT

We report a rare case in which a metallic foreign object migrated to cervical intervertebral foramina. Only two cases have been reported. Plain films and Computed Tomography of the cervical spine showed a foraminal metallic object

Key words: Cervical intervertebral foramina, foreign body, metallic object

Servikal Foraminal Yabancı Cisim

ÖZET

Bu makalede Servikal intervertebral foramene migrasyon gösteren bir yabancı cisim olgusunu rapor ettik. Sadece 2 olgu rapor edilmiştir. Servikal omurganın Röntgen ve Bilgisayarlı Tomografisinde foraminal yabancı cisim görülmektedir.

Anahtar kelimeler: Servikal intervertebral foramene, yabancı cisim, metalik obje

INTRODUCTION

Penetrating spinal cord injuries due to cutter tools, stab wounds and firearms have been described before. Also dislocation and migration of spinal devices and broken spinal catheters have been reported (1,2). Neurological deficits may accompany the injury in many cases. The presence of intraspinal foreign bodies in patients with few or no symptoms are rare and only two cases of penetrating and migration of foreign body in the cervical intervertebral foramen have been reported (3-4). In this manuscript, a foreign body at C3-4 intervertebral foramen at a patient with no neurological deficit have been reported.

CASE

A 45 year old woman presented with right arm pain with 3 months duration. The patient reported that 3 months before, an explosion occurred while sitting near a fire. After explosion a bleeding happened at neck and severe pain occurred. At physical examination there was no scar at her neck. Neurological examination revealed mild hypoesthesia of the right arm without any weakness. A 7x2 mm metallic object was observed at C3-4 level on the cervical plain radiograph (Figure 1). A cervical spine computed tomography showed a foreign body lying across the C3-4 intervertebral foramen (Figure 2). After Gabapentine 1800 mgr/day treatment, the severe pain rapidly disappeared and operation did not perform. After follow up 6 months with gabapentine treatment, the patient has no neurological deficit and pain.

¹Kocatepe University School of Medicine, Department of neurosurgery, Afyonkarahisar, Turkey

Received: 04.12.2010, Accepted: 31.05.2011

Correspondence: Bolvadin Dr.H.I.Ozsoy State Hospital, Emirdag Street Number:82 Bolvadin/ Afyonkarahisar Postal Code: 03300
Fax: +902726126302, Tel:+905054546055
E-mail: ergunkara@hotmail.com

DISCUSSION

The migration and penetration of foreign bodies into the spinal cord are rare for patients with few or no symptoms. The clinical picture of intraspinal foreign bodies may include sensory motor deficits, cerebrospinal fluid (CSF) fistulas, meningitis, and subarachnoid hemorrhage. Progressive neurological deficit in these cases are often irreversible. When a progressive neurological deficit is present, it is mandatory to apply surgical intervention to remove any fragment remaining in the spinal canal (5,6). The purpose of surgical treatment is to decompress the spinal cord, remove the foreign object and avoid cerebrospinal fluid leakage (7). However, if neurological deficit is absent, then the removal of the fragment becomes controversial; the general opinion is to perform surgical treatment. If a CSF fistula is present, it must be restored surgically due to the risk of an infection. The case which Silvestro et al reported had a trauma while playing soccer game 5 years ago (3). Then he progressively presented with pain, numbness and mild hypoesthesia in the cervical region with right hand fingers scored 4/5 on Medical Research Council (MRC) scale (3). Silvestro et al performed bilateral C7 laminectomy for progressive neurological deficit (3). Another case which Xuhua et al reported had a trauma 6 days ago (4). He presented with neck pain, numbness, mild hypoesthesia in the cervical region and his deltoid and biceps brachii were weakened with a score of 3/4 on the MRC scale (4). Xuhua et al performed anterolateral decompression of the C5 nerve

root (4). Both cases, in the literature, which have sensory - motor deficits have been performed surgery. Although, removal of the foreign body is an appropriate choice to avoid acute symptomatic effects or delayed complications, we did not perform surgery because there was no neurological deficits in our case and her right arm pain responded to Gabapentine rapidly. As a conclusion Gabapentine could be the first choice in patients with intraspinal foreign object if there is no neurological deficit.

REFERENCES

1. Abumi K, Anbo H, Kaneda K. Migration of an acupuncture needle into the medulla oblongata. *Eur Spine J* 1996;5: 137-9.
2. Staats PS, Stinson MS, Lee RR. Lumbar stenosis complicating retained epidural catheter tip. *Anesthesiology* 1995;83: 1115-18.
3. Silvestro C, Cocito L, Pisani R. Delayed effects of a migrated foreign body (sewing needle) in the cervical spine: a case report. *Spine* 2001;26: 578-9.
4. Xuhua LU, Aimin CHEN, Deyu CHEN, Wen YUAN. Removal of a foreign metallic object from the cervical intervertebral foramina. *J Orthop Sci* 2009; 14: 672-4
5. Thakur RC, Khosla VK, Kak VK. Non-missile penetrating injuries of the spine. *Acta Neurochir (Wien)* 1991;113:144-8.
6. Wang MY, Hoh DJ, Leary SP, Griffith P, McComb JG. High rates of neurological improvement following severe traumatic pediatric spinal cord injury. *Spine* 2004;29: 1493-7.
7. Gulamhuseinwala N, Terris J. Evolving presentation of spinal canal penetrating injury. *Injury* 2004; 35: 948-9.

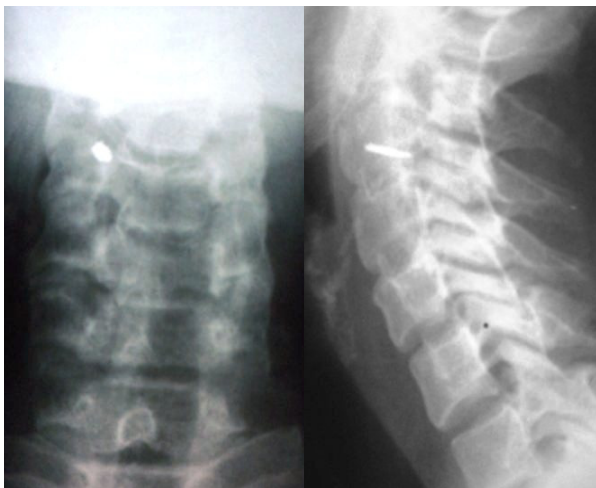


Figure 1. A 7x2 mm metallic object was observed at C3-4 level on the cervical plain radiograph

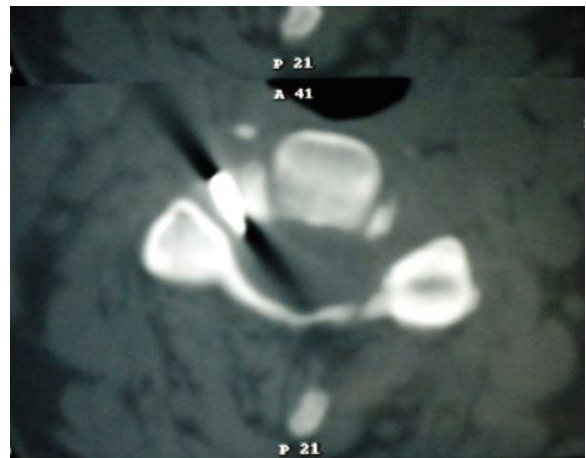


Figure 2. A cervical spine computed tomography showed a foreign body lying across the C3-4 intervertebral foramen