

Xanthogranulomatous Pyelonephritis Presented with Spontaneous Kidney Rupture in a Young Woman

Bülent Altınoluk¹, Hamide Sayar², Mesut Özkaya³, Tayfun Sahinkanat¹, Onder Malkoc¹

ABSTRACT

Xanthogranulomatous pyelonephritis (XGP) is an uncommon and aggressive form of inflammation of the renal parenchyma particularly resulting in diffuse renal destruction. A previously healthy 25-year-old woman was admitted to our clinic with right flank pain of sudden onset, nausea and high fever. Computed tomography revealed a mass (12 x 7 cm in diameter) around the right kidney with extension to pelvis and paravertebral space. Flank incision was made urgently and a very large perirenal haematoma and abscess formation were found caused by the rupture located at the posterior side of the right kidney. A right nephrectomy was performed and abscess material was evacuated from the perirenal area. XGP was diagnosed by histopathologic examination of the resected kidney. Although XGP regularly demonstrates a gradual progression and presents with nonspecific symptoms, the situation may appear with complications as in our case. Our patient presented with renal rupture and perirenal abscess extending to the pelvis and paravertebral space. To the best of our knowledge, this is the first report of XGP presenting with spontaneous renal rupture in the English literature.

Key words: Xanthogranulomatous pyelonephritis, kidney rupture, spontaneous, nephrectomy, renal abscess

Genç Bir Kadında Spontan Böbrek Rüptürü ile Seyreden Ksantogranülatöz pyelonefrit

ÖZET

Ksantogranülatöz pyelonefrit (XGP), renal parankimin nadir görülen ve agresif seyreden, özellikle diffüz renal yıkım ile sonuçlanan enflamasyondur. Daha önceden sağlıklı olan 25 yaşında kadın hasta kliniğimize, ani başlangıçlı sağ flank ağrısı, bulantı ve yüksek ateş ile başvurdu. Bilgisayarlı tomografi sağ böbrek etrafında, pelvis ve paravertebral alana uzanım gösteren 12 x 7 cm çapında bir kitle izlenimi gösterdi. Bunun üzerine acil olarak flank insizyon yapıldı ve sağ böbreğin posterior yüzünde lokalize rüptürden kaynaklanan oldukça büyük perirenal hematoma ve abse formasyonu bulundu. Sağ nefrektomi yapıldı ve perirenal alandan abse materyali boşaltıldı. XGP tanısı, çıkarılan böbreğin histopatolojik incelemesiyle konuldu. XGP, progresyon gösteren ve nonspesifik semptomlarla seyreden bir durum olmasına rağmen, bizim vakamızda olduğu gibi komplikasyon ile de ortaya çıkabilir. Hastamız renal rüptür ve paravertebral alana ve pelvise uzanım gösteren perirenal abse ile başvurdu. Bizim bilgimize göre, bu olgu literatürde spontan renal rüptür ile başvuran ilk XGP olgusudur.

Anahtar kelimeler: Ksantogranülatöz pyelonefrit, böbrek rüptürü, spontan, nefrektomi, renal abse

INTRODUCTION

Xanthogranulomatous pyelonephritis (XGP) is an unusual and aggressive form of chronic bacterial infection of the renal parenchyma characterized by accumulation of lipid

laden foamy macrophages and destruction of the renal parenchyma, mostly associated with obstruction, calculi and urinary tract infection (1).

Spontaneous rupture of the renal parenchyma is a rare

¹Kahramanmaraş Sütçü İmam University Medical Faculty, Department of Urology, Kahramanmaraş, Turkey, ²Kahramanmaraş Sütçü İmam University Medical Faculty, Department of Pathology, Kahramanmaraş, Turkey, ³Kahramanmaraş Sütçü İmam University Medical Faculty, Department of Internal Medicine, Kahramanmaraş, Turkey

Correspondence: Altınoluk Bulent,
Kahramanmaraş Sütçü İmam University Medical Faculty, Department of Urology,
Kahramanmaraş, Turkey
Tel: 090 505 952 36 22 Pbx: 090 344 221 23 71
E-mail: drbulenta@yahoo.com

Received: 31.05.2010, Accepted: 10.01.2011

condition and almost always occurs in a previously diseased kidney. Associated pathological findings include hydronephrosis, calculus obstruction, tumors and infection.

We report a case of XGP which presents with spontaneous rupture of the renal parenchyma resulting in perirenal abscess and hematoma formation in a young woman.

CASE

A 25-year-old woman with no previous history of metabolic and renal disease or recent trauma was admitted to emergency department with a right flank pain of sudden onset, nausea and high fever. About 15 days prior to admission, the patient experienced an episode of urinary tract infection and was treated with 1 week of oral ciprofloxacin in another hospital. At presentation, the patient looked severely ill and had intense tenderness and swellings at right flank. Her body temperature was 37.8°C, blood pressure 90/55 mm Hg, pulse rate 125/min and respiratory rate 28 breaths/min. Laboratory data were as follows: hemoglobin 6.3 g/dL, white blood cell count 16.7/μL (88% polymorphs), and erythrocyte sedimentation rate 74 mm per hour. Urinalysis revealed only microscopic hematuria. Other laboratory tests were normal. Abdominal ultrasonography and computed tomography

(CT) showed a hypoechoic 12 x 7 cm mass around the right kidney with extension to the pelvis and paravertebral space which can be interpreted as retroperitoneal abscess (Figure 1). For this reason, the kidney was explored urgently through a flank incision and revealed a very large perirenal haematoma, abscess and renal rupture. About 400 ml of abscess material was evacuated from the perirenal area. *Proteus mirabilis* grew in the culture of the retroperitoneal abscess material, even though blood and urine cultures were negative. A right nephrectomy was performed because of non-functioning kidney and the patient's recovery was uneventful. The patient was discharged on the 7th day postoperatively. Macroscopic examination revealed total disruption of renal parenchyma and yellow colored nodular masses in major calyx. Perforation area was seen on the posterior aspect of the removed kidney (Figure 2). Histopathologic examination of the resected specimen revealed destruction of the normal renal parenchyma and replacement by an inflammatory infiltrate composed of foamy (lipid-containing) macrophages, giant cells, polymorphonuclear cells, lymphocytes, plasma cells, granulomatous reaction and fibrosis. (Figure 3) The pathological diagnosis was xanthogranulomatous pyelonephritis. No evidence of tuberculoid granulomas or renal tumor was observed.

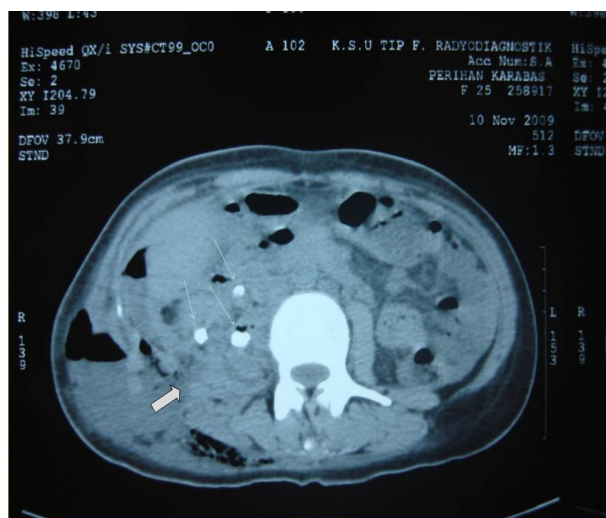

Figure 1. Abdominopelvic CT scan revealed a non-functional right kidney with a large perinephric hematoma and abscess extended to the paravertebral space on the right side (wide arrow). Stones are seen in the right kidney and retroperitoneal space (thin arrow).

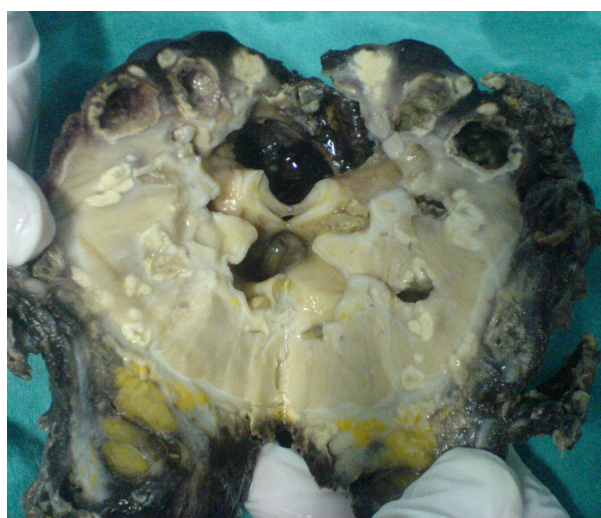

Figure 2. Destruction of renal parenchyma and yellow colored nodular masses in major calyx. Perforation area was seen on the posterior aspect of the removed kidney.

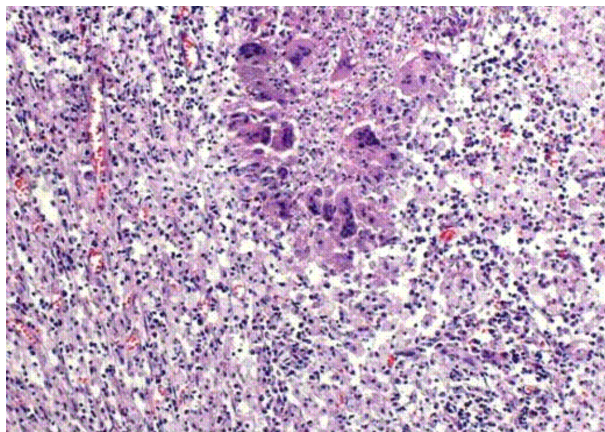


Figure 3. Microscopic examination showing lymphoplasmocytic infiltration, large foamy (lipid-containing) macrophages and multinuclear giant cells and central necrosis. (HE, x100)

DISCUSSION

Xanthogranulomatous pyelonephritis (XGP) is a slowly progressive, chronic kidney infection. The main factors involved in the pathogenesis of XGP are chronic obstruction, infection and nephrolithiasis (2). The disease was first described by Schlagenhauser over 90 years ago (3). It begins within the pelvis and calyces and subsequently extends into and destroys renal parenchyma and adjacent tissues. (4) According to previously published data, the entity is uncommon and is found in only about 0.6% of histologically evaluated cases with renal inflammation (1,3).

The situation has various clinical nonspecific symptoms and signs. Lower urinary tract symptoms, fever and chills, flank pain, tenderness, and palpable mass are the symptoms commonly observed. The medical history is often positive for UTIs and urologic instrumentation (3, 5). The initial clinical manifestation of such a rupture ranges from mild flank discomfort to unremitting pain associated with an acute abdomen, as was seen in our patient (6). Although our patient was a non-diabetic 25-year-old woman, the disease is classically seen in the fifth to seventh decade diabetic women in the presence of nonfunctioning kidneys, urolithiasis and urinary tract infection particularly with *Proteus mirabilis* (3). The most common offending organisms are *Proteus mirabilis*, *Escherichia coli*, *Klebsiella pneumonia* and *Streptococcus faecalis* (7). One third of patients have sterile urine, and the infectious organism can be detected only by tissue culture.

Whereas, we cultured the organism in the abscess material in our patient. This could be attributed to either urinary tract obstruction preventing contaminated urine from reaching the bladder or to the antibiotic treatment given before the patient's admission (7).

Computed tomography gives the necessary information, especially by identifying the extent of renal involvement and spread to adjacent organs. (7) Nowadays, CT is still considered as the gold standard method in the preoperative radiological evaluation of XGP. CT examination of the retroperitoneal space is also the most important diagnostic modality in defining spontaneous kidney rupture. The findings consistent with retroperitoneal bleeding of renal origin in CT comprise a high attenuation mass contained within the renal capsule with extravasations into the perirenal space (8). Since the patient was admitted to our hospital after renal rupture, we didn't see preoperatively the findings of XGP; we only detected the rupture findings on CT scan. Complicated cases of XGP are rare and mostly appear as case reports in the literature. Coexistence of cutaneous fistula, renal replacement lipomatosis, renocolonic fistula, staghorn disease in children and psoas abscess formation has been reported (9).

Our patient presented with an unusual complication, renal rupture. After a diligent search of Urology literature, no previous reports of XGP presenting with spontaneous renal rupture were identified. The management of traumatic kidney rupture is determined by the hemorrhage size, the clinical findings and the underlying pathology. Patients with signs of hemorrhagic shock, or significant anemia and a large palpable mass on the affected side, and whose CT findings confirm possible renal rupture and perirenal hemorrhage should undergo immediate operation (10). The preferred treatment for diffuse XGP is surgery and consists of nephrectomy with resection of all other involved tissues (9).

XGP is not quickly progressive and like much renal pathology, presents with nonspecific symptoms. Especially when there is no previous diagnosis, as in our case, the diagnosis may be equivocal. Also the situation may appear with complications. But our case was admitted with a complication which was not reported in the English literature. Our patient had XGP without a prior history of any urinary symptoms and presented with an unusual complication, spontaneous renal rupture. The diagnosis of XGP should be kept in mind, in patients presented with renal rupture and perirenal abscess formation.

REFERENCES

1. Malek RS, Elder JS. Xanthogranulomatous pyelonephritis: a critical analysis of 26 cases and of the literature. *J Urol* 1978; 119: 589-93.
2. Gregg CR, Rogers TE, Munford RS. Xanthogranulomatous pyelonephritis. *Curr Clin Top Infect Dis* 1999; 19:287-304.
3. Schlagenhauser F. *Über eigentümliche Staphylmykosen der Nieren und der pararenalen Bindegewebes*. Frankfurt Z Pathol 1916; 139-48.
4. Schaffer AJ, Schaffer EM. Infections of the urinary tract. In: Wein AJ, Kavoussi AR, Novick AC, Partin AW, Peters CA eds. *Campbell-Walsh Urology 9th edition*.: WB Saunders, Philadelphia, p 223-303, 2007.
5. Afgan F, Mumtaz S, Ather M. Preoperative Diagnosis of Xanthogranulomatous Pyelonephritis. *Urol J* 2007; 4:169-73SZ.
6. Ashebu SD, Elshebiny YH, Dahniya MH. Spontaneous rupture of the renal pelvis. *Australasian Radiology* 2000; 44:125-7.
7. Ho CI, Wen YK, Chen ML. Xanthogranulomatous Pyelonephritis Successfully Treated with Antibiotics Only. *J Chin Med Assoc* 2008; 71:643-5.
8. Belkin BA, Vine HS. Spontaneous renal rupture: evaluation by computerized tomography. *J Urol* 1987; 138: 120-2.
9. Al-GhazoMA, GhalayiniIF, Matalkall. Xanthogranulomatous Pyelonephritis: Analysis of 18 Cases. *Asian J Surg* 2006; 29: 257-61.
10. Szentgyorgyi E, Kondas J, Varga SZ. Spontaneous Rupture of the Kidney: A Report on 5 Cases. *Int Urol Nephrol* 1994; 26: 133-40.