

An Unusual Cause of Maternal Respiratory Distress in Postoperative-Postpartum Period: Diaphragmatic Hernia

Ahmet Cantug Caliskan¹, Serkan Bodur², Hakan Aytan¹, Ismet Gun³, Berat Acu⁴

ABSTRACT

Diaphragmatic hernia complicating pregnancy is rare but it is associated with high complicated outcomes, particularly if surgical intervention is delayed. We report a case of diaphragmatic hernia noticed after caesarean delivery in a pregnant 27-year-old women with a history of uneventful first pregnancy. We report this case to alert obstetricians to the possibility of this rare surgical emergency during pregnancy and peripartum period.

Key words: Diaphragmatic hernia, pregnancy, respiratory distress, surgical emergency

Postoperatif-Postpartum Dönemde Maternal Solunum Sıkıntısının Nadir Bir Nedeni Olarak Diayfargama Hernisi

ÖZET

Diafragma hernileri gebelikleri çok nadiren komplike etmelerine rağmen özellikle cerrahi müdahalede ve tanıda gecikmelerin yaşanması halinde çok ciddi sonuçlar doğura bilirler. İlk gebeliğini sorunsuz olarak geçirmiş, 27 yaşındaki bir gebede sezaryen doğum sonrasında tanı alan bir diafragma herni olgusunu sunuyoruz. Bu vaka sunumu ile nadir rastlanılan bu cerrahi acil duruma kadın hastalıkları ve doğum uzmanlarının dikkatini çekmeyi amaçladık.

Anahtar kelimeler: Cerrahi aciller, diafragma hernisi, gebelik, solunum sıkıntısı.

INTRODUCTION

Maternal diaphragmatic hernia is an extremely rare and unusual but carrying life threatening emergency condition. It is because of congenital diaphragmatic defect or an undetected traumatic rupture of diaphragma. The clinical symptoms are variable with acute onset and radiological signs of diagnosis and management of patients are often difficult and problematic. Second and third trimesters of pregnancy, labor and post-cesarean state can induce the diaphragmatic rupture because of increased intrabdominal pressure. Once rupture occurs it presents a true life-threatening emergency (1). We

present a case of acute respiratory distress due to diaphragmatic rupture during post-operative and post-partum period of a second cesarean section in a pregnant 27 year-old women with a previously unrecognized diaphragmatic hernia or defect due to either congenital or traumatic.

CASE

A 27 year-old pregnant was admitted to our obstetrics department at her 24 weeks of gestation. It was her second pregnancy and her first delivery was performed

¹Gaziosmanpasa University Faculty of Medicine Department of Obstetrics and Gynecology, Tokat, Turkey, ²Maresal Cakmak Military Hospital, Department of Obstetrics and Gynecology, Erzurum, Turkey, ³GATA Haydarpasa Training Hospital, Department of Obstetrics and Gynecology, İstanbul, Turkey, ⁴Gaziosmanpasa University Faculty of Medicine Department of Radiology, Tokat, Turkey.

Correspondence: Serkan Bodur MD.
Address: Maresal Cakmak Military Hospital, Dept. of Obstetrics and Gynecology, 25100, Yenisehir, Erzurum, Turkey
Phone: +905336379313, Fax: +904423172263
e-mail Address: serkan_bodur@yahoo.com

by caesarean section. She was reporting an uneventful previous and current pregnancy course. We pursued the patient three times at 24, 32 and 36th weeks of gestation. There was no problem about her physical and laboratory examination until delivery. At the 38th gestational week, uterine contractions were stated on non-stress test and 3200g, male fetus was made to deliver by caesarean section. She experienced an uneventful operation and general anesthesia period.

The day after operation, patient was suffered from acute onset severe chest and epigastric pain with respiratory distress. Blood pressure was 110/73 mmHg, pulse was 96 beats/min, respiration was 30 breaths/min, temperature was 37.4°C, oxygen saturation was 94% on 6 L O₂ via nasal cannula. Breath sounds were absent on the left side of the thorax. A chest radiography showed unexplained air-fluid levels at the left side of the thorax. The gastric air bubble was high. This was recognized as bronchiectasia. (Figure 1) The clinical presentation was not suggestive about any disease. The diagnosis of diaphragmatic rupture was made by barium enema orientated computed tomography. (Figure 2) We referred our patient to thoracic surgeons and they repaired the diaphragmatic rupture by using mesh.

We present this case to emphasize the importance of this rare cause of post-operative and post-partum emergency. High index of clinical suspicion with early urgent surgical intervention could be life saving particularly when the signs of respiratory compromise and intestinal obstruction were noticed at early post partum period.

DISCUSSION

Diaphragmatic hernias may be seen in adulthood due to late manifestation of congenital diaphragmatic defect or an undetected traumatic rupture of diaphragm. Congenital diaphragmatic hernia is a rare anomaly that often results in antenatal herniation of fetal abdominal content into thoracic cavity. In late presenting congenital diaphragmatic hernias, the extent of herniation of abdominal viscera into the thorax may vary, leading to acute or intermittent symptoms. Previous normal chest radiography was reported in number of cases suggesting that in such cases the defect is long standing, but the viscera are confined by the hernial sac or obdurate by a solid organ. This varying amount of abdominal visceral herniation may lead to acute or intermittent symptoms. The

patient becomes symptomatic when actual herniation takes place later in life because of rupture of hernial sac.

Diaphragmatic injury is common in patients with sustained chest trauma. Blunt and penetrating traumas are common etiologic factors in traumatic diaphragmatic hernias (1-3). If rupture of the diaphragm is not diagnosed at the time of trauma, chronic diaphragmatic hernia may result. The diagnosis may be missed initially. Abdominal structures may later herniate and it may be manifested with nonspecific chest or abdominal symptoms. The diagnosis is usually made on the basis of radiologic findings. The course of the disease was divided into three phases (4). The acute phase occurs immediately after injury. The interval phase presents with asymptomatic or chronic nonspecific symptoms. The obstructive phase occurs when the abdominal contents become strangulated.

Either congenital or traumatic; pain and epigastric discomfort are the main symptom of diaphragmatic hernias. Pain is usually felt in the lower abdomen and epigastrium. Aggravation by having large meals, taking food, effervescent drinks and relieving by belching are characteristics of pain. This characteristic pain pattern can be confusing during pregnancy because of high frequency of pregnancy related gastrointestinal symptoms such as heartburn, nausea, vomiting and malaise (7). But failure of dietary changes, antacids and antispasmodics especially during late pregnancy must alert the obstetrician to consider the gastrointestinal pathologies like diaphragmatic hernias. In our patient we did not notice an unusual gastrointestinal symptom during late pregnancy.

These mild symptoms of latent phase may change dramatically without any apparent warning. Severe and continuous pain, breathlessness and signs of intestinal obstruction may occur in this late stage of diaphragmatic hernias. In this stage, bowel sounds may also be audible in the chest and signs of mediastinal shift may also be noticed. Our patient was presented dominantly with respiratory symptoms and we could not detect breath sounds on the left side of the thorax.

To correct diagnosis, radiographical findings are essential. There are suggestive findings on chest radiography including gas bubbles or air-fluid levels and pleural effusion. If the hernia is suspected, an appropriate barium study should be performed. There are a number of case reports in the literature where late presenting diaphragmatic hernias have been misdiagnosed as pneumothorax and patients have undergone unnecessary emergency

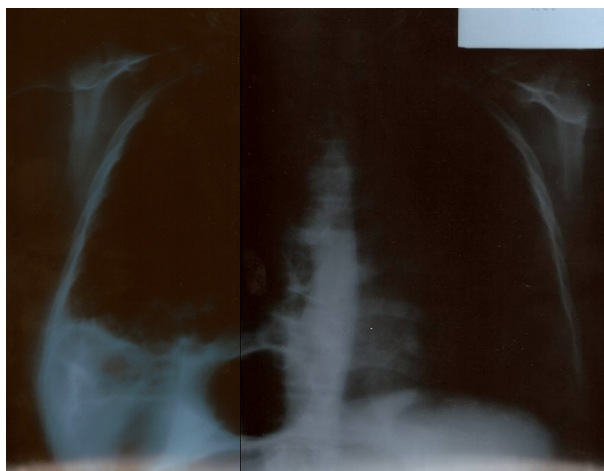


Figure 1. Unexplained air-fluid levels in chest radiography.

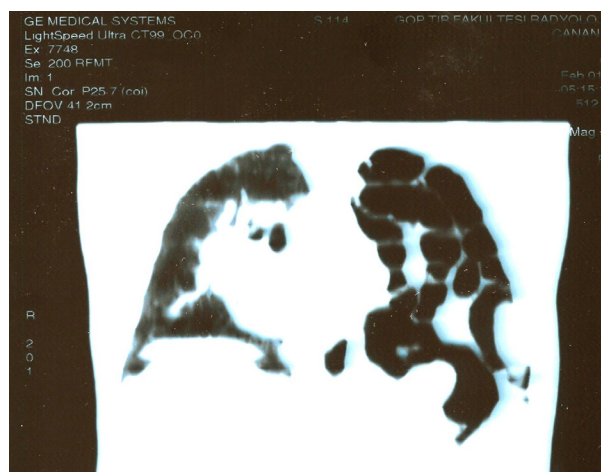


Figure 2. Barium enema orientated computed tomography of the patient.

thoracocentesis (4, 6). Although the clinical presentation in our case was not suggestive about any disease, it was misdiagnosed as bronchiectasia according to chest X-ray. Barium enema orientated computed tomography revealed herniated bowel loops in thoracic cavity. The other diagnostic tools available for diagnosis of diaphragmatic hernia are; nasogastric tube placement, ultrasonography, magnetic resonance imaging and gastrointestinal contrast studies.

In our case, we have found that the clinical course of either congenital late presenting or traumatic diaphragmatic hernias may similar. Chest X-ray findings often are not specific to make correct diagnosis. More invasive imaging interventions, such as barium enema orientated computed tomography, may be helpful to establish the diagnosis.

Once the diagnosis is made, treatment requires operation at any stage of disease. Perioperative mortality of surgery is under 10% when it is performed during the latent stage (7). If an emergency surgery is needed in the late stage the perioperative mortality rises to 20-80% (7). Conservative management of disease is contraindicated especially in cases with pregnancy (7) so that prompt diagnosis of disease during latent stage is essential. According to Eglinton T and et al. (8) there is 36 previously reported cases of diaphragmatic hernias identified in pregnancy. There is a consensus that a surgical emergency and operative management is necessary irrespective of fetal maturity when hernias diagnosed in the late stage. But elective management of asymptomatic

hernias is controversial (8). In traditional approach it is recommended that immediate repair is essential for symptomatic patients because further delay may result in maternal and fetal death (9). Kurznel and Naunheim (10) recommended cesarean delivery after lung maturity is achieved for asymptomatic patients. They do not offer vaginal delivery under any circumstance because of increased intrabdominal pressure during spontaneous vaginal delivery. Genc et al. (11) offered gastric decompression in late stage patients before and during transportation to tertiary care center. According to Dumont (12) active labor should be avoided and if an unexpected labor occurs, forceps application must be performed. In his case he reported an aggravation of an operated hernia during pregnancy. According to him, it is possible that some diaphragmatic hernias could be aggravated without any symptom after an uncomplicated previous pregnancy as seen in our case.

We report this case to alert obstetricians to the possibility of this rare surgical emergency during pregnancy. Delay in diagnosis can result in both fetal and maternal mortality in up to half of cases (10). It must be kept in mind that the failure of antacids, antispasmodics and dietary changes to relieve gastrointestinal symptoms during advanced pregnancy should alert obstetrician to suspect gastrointestinal pathology. If signs of respiratory distress or obstruction occur unexpectedly during pregnancy or peripartum period, obstetricians must be point out the possibility of diaphragmatic hernia.

REFERENCES

1. Brown GL, Richardson JD. Traumatic diaphragmatic hernia: a continuing challenge. *Ann Thoracic Surg.* 1985;39:170-3
2. Carter BN, Giuseffi J, Felson B. Traumatic diaphragmatic hernia. *AJR.* 1951;65: 56-72
3. Coren ME, Rosenthal M, Bush A. Congenital diaphragmatic hernia misdiagnosed as tension pneumothorax. *Pediatr Pulmonol* 1997;24:119-21
4. Ball T, McCrory R, Smith JO, Clements JL. Traumatic diaphragmatic hernia: errors in diagnosis. *AJR* 1982;138:633-7
5. Gimovsky ML, Schrifin BS. Incarcerated foramen of Bochdalek hernia during pregnancy. A case report. *J Repr Med* 1983;28:156-8
6. Cosacov C, Krausz L, Freund U. Emergencies in delayed diaphragmatic herniation due to blunt trauma. *Injury* 1984;15:370-1
7. Payne JH, Yellin AE. Traumatic diaphragmatic hernia. *Arch Surg* 1982; 117:18-24
8. Eglinton T, Coulter GN, Bagshaw P, Cross L. Diaphragmatic hernias complicating pregnancy. *ANZ J Surg* 2006; 76:553-7
9. Kaloo PD, Studd R, Child A. Postpartum diagnosis of maternal diaphragmatic hernia. *Aust N Z J Obstet Gynaecol* 2001;41:461-63
10. Kurzel RB, Naunheim KS, Schwartz RA. Repair of symptomatic diaphragmatic hernia during pregnancy. *Obstet Gynecol* 1988;71:869-71
11. Genc MR, Clancy TE, Ferzoco SJ, Norwitz E. Maternal congenital diaphragmatic hernia complicating pregnancy. *Obstet Gynecol* 2003;102:1194-96
12. Dumont M. Diaphragmatic hernia and pregnancy. *J Gynecol Obstet Biol Reprod* 1990;19:395-9