



Liver Cyst Hydatid Fistulated Into Duodenum

Ahmet Okuş¹, Serden Ay¹, Cansu Karakaş², Mustafa Çarpraz³, Mehmet Ali Eryılmaz¹

¹Konya Training and Research Hospital, General Surgery, Konya, Turkey.

²Amasya Sabuncuoğlu State Hospital, Pathology, Amasya, Turkey.

³Amasya Sabuncuoğlu State Hospital, Internal medicine, Amasya, Turkey.

Eur J Gen Med 2012;9 (Suppl 1):53-55

Received: 26.12.2011

Accepted: 27.12.2011

Abstract

Hydatid cyst of liver is a disease usually seen in endemic regions. While it is very small at the beginning, cyst diameter increases approximately 1-3 cm per year. Among known complications of hydatid disease, pressure to the adjacent organs due to the cyst growth, perforation into peritoneal cavity or bile tract are most notable. However, its fistulization into gastrointestinal tract is very rare. A 80-year-old male patient presented with the complaints of abdominal pain, fever and deterioration in general physical condition. It was determined that the patient was diagnosed with hydatid cyst of liver about 15 years ago but refused treatment. Imaging revealed a 20x15 cm multiseptal cystic lesion filled with air in the right lobe of liver. Patient was admitted to OR and exploration revealed that cyst had fistulized into the duodenum. The fistulization of liver hydatid cyst into the duodenum is very rare. We believe that the size of cyst and the delay in treatment caused the cystoduodenal fistula.

Key Words: Echinococcosis, hepatic, intestinal fistula, duodenum cyst

Duedenum İçine Fistülize olan Karaciğer Kist Hidatiği

Özet

Kist Hydatid çeşitli komplikasyonlara sebep olabilen ve non invaziv ultrasonik çalışmalarla tespit edilebilen bir hastalıktır. İnsanlarla kist hydatid genellikle Ekinokoküs granülosus ile oluşmaktadır. daha az olarak Ekinokoküs multilokularis etken olmaktadır. 12 yaşında kız hasta 12 gün önce salıncaktan düşmüş. Akut batın bulguları ile acil ameliyata alındı. Explorasyonda batında dev kistik lezyon tespit edildi. Bu kistin serbest kist hidatid olduğu düşünüldü. bu gelişim normal kist hydatid gelişim patolojisine uymamaktadır.

Anahtar kelimeler: Hidatik hastalığı, travma, patofizyoloji

Correspondence: Serden Ay, M.D. Konya Training and Research Hospital, General Surgery, Konya, Turkey
Phone: 905309363356, Fax: 903323236723
E-mail: serdenay@yahoo.com

INTRODUCTION

Echinococcus Granulosus is a parasitic organism that cause Hydatid disease in humans. While it matures into it's worm form in canine Gastrointestinal tract, in human and sheep GIS tract it cannot evolve into the mature form, rather by leaving the bowels and immigrating to other organs (usually liver) evolves to the well known cyst form. Hydatid cyst is often asymptomatic and it is usually diagnosed incidentally during imaging. Hydatid cyst of liver has two significant complications: The cyst could fistulize into the biliary tract or and the cyst could rupture into the peritoneal cavity. These complications are observed in one third of the cases (1, 2). Fistulization of hydatid cyst into the gastrointestinal tract is rarely encountered (3).

CASE

A 80-year-old male patient admitted to the KEAH Emergency Department ER with complaints of abdominal pain, fever and fatigue. He had these complaints for about 20 days and due to the loss of appetite his oral food intake was considerably decreased and his general physical condition had deteriorated. Although he had no systemic disease, his history revealed that he had been diagnosed with liver hydatid cyst 15 years ago and refused treatment. During his physical examination, a rigid, painful 20x15 cm mass completely occupying the right upper quadrant of the abdomen was palpated. Laboratory examination revealed WBC: 5.2x 10⁹/L, HGB: 8.8g/dL, HCT: 27.1%, ALP: 480 IU/L, AST: 36 IU/L, ALT: 34 IU/L, albumin: 1.8g/dL, and CRP: 160. Ultrasonographic images demonstrated a 20x15 cm cyst in the right lobe of liver with daughter vesicles and intense air echoes. There was also mild amount of free fluid (reactionary) in the abdomen. MRI revealed a cystic formation in the right lobe of liver extending to the hilus level and dislocating the vascular structures to the medial. It was a relatively thick-walled Type 3 hydatid cyst with daughter vesicles and thin septas (Figure 1). The patient was hospitalized and upon improving his general condition (HGB: 10.0, HCT: 30.3) admitted to OR on the 2nd day of hospitalization. During exploration, the hydatid cyst originating from the right lobe of liver was observed. It had adhesions to the adjacent organs (gall bladder, duodenum, stomach) and the omentum. After the infected cyst drained and we observed that the cyst had fistulized into the duodenum (Figure 1). The 1x1.5

cm. duodenum defect was repaired with silk sutures and an omentum patch was placed. Cyst wall was excised partially and capitonized. On postoperative 3rd day, low-flow bile fistula (250cc/24h.) was formed. The fistula was closed on the postoperative 9th day. Patient was discharged with full recovery on the postoperative 14th day. No problem had occurred during the over the 6-month follow-up.

DISCUSSION

Hydatid cyst is encountered endemically in North America, South Africa, and Central Asia and in some parts of China, and Eastern Turkey due to the uncontrolled canine population (literature). In humans, it is most frequently located in the liver (50-75%). In general, it is solitary (72%). The cyst is composed of 3 layers; the innermost one-cell thick germinative membrane and the laminar membrane covering it belong to the cyst and the outer 3rd layer, adventitia, is composed of the fibrous tissue of the host. The patients are mostly asymptomatic and usually diagnosed incidentally during imaging. In symptomatic patients, the most common symptoms are abdominal pain and a mass in the abdomen (1, 2). As the cyst grows into the parenchyma of the liver, its wall gets thinner due to the increasing internal pressure. As a consequence, the cyst could often rupture into the biliary system and rarely into the peritoneal cavity. Rupture into the biliary system is 9%-30% in large series and may cause jaundice and cholangitis. Drainage of the biliary tract with ERCP might be required. Peritoneal perforation, which might cause life-threatening anaphylactic reaction (1-12.5%), is observed in 10-16% of the patients (trauma plays an important role) and requires immediate surgical intervention (2). In patients with complicated liver hydatid cysts, morbidity and hospitalization increase. Important factors for the rupture of the cyst into biliary tract and peritoneal cavity are diameter and the age of the cyst (2). The fistulization of the cyst into the gastrointestinal tract is very rare (0.15%) and in literature, it is only encountered in a few case reports (3, 4, 5). Detection of air in the cyst should alert the physician for the gastrointestinal fistula formation (3, 4, 5). Most of the cases in the literature had air in the cyst as this case. Furthermore, it can be hypothesized that in this case the diameter of the cyst and the delay the treatment (15 years) are the causes of fistulization.

Although surgical treatment is still the indisputable

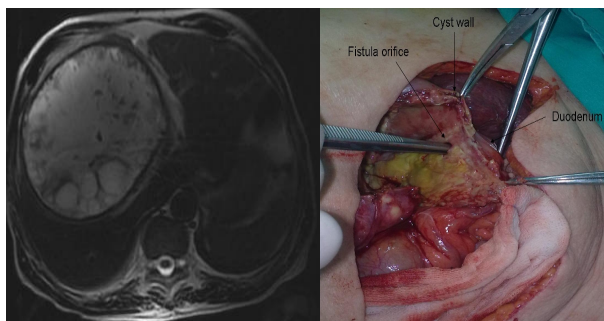


Figure 1. MR image of the cyst and intraoperative image of the cyst

choice, interventional radiological treatment has been widely used in recent years. Besides conservative surgical treatments such as partial cystectomy or drainage, radical surgical procedures such as pericystectomy or hepatic resection can also be performed. In general view, no major surgery is required for a benign pathology. However, radical surgery can be performed in selected complicated cases (6). Preoperative and postoperative albendazole treatment is effective in preventing recurrence, and the recurrence rate after all surgical treatment alternatives is less than 10% (7).

In conclusion, delayed diagnosis and treatment of liver hydatid cyst lead to complications. In this case, a patient with liver hydatid cyst fistulized into the duodenum was presented and the importance of the age and the diameter of the cyst in the development of the complication were emphasized.

REFERENCES

1. Altıntaş N. Cystic and alveolar echinococcosis in Turkey. *Ann Trop Med Parasitol* 1998; 92: 637-642
2. Akcan A, Sozuer E, Akyıldız H, Ozturk A, Atalay A, Yılmaz Z. Predisposing factors and surgical outcome of complicated liver hydatid cysts. *World J Gastroenterol* 2010;16: 3040-8
3. Noguera M, Alvarez-Castells A, Castelle E, Gifre L, Andreu J, Quiroga S. Spontaneous duodenal fistula due to hepatic hydatid cyst. *Abdom Imaging* 1993;18:234-6
4. Noura K, Hila H, Bedioui H, et al. Rupture of hydatid cyst of the liver into the duodenum. A case report. *Tunis Med* 2007;85:979-81
5. Patankar T, Prasad S, Rohondia OS, Mohite JD, James P, Radhakrishnan R. Fistulization of hepatic hydatid cyst into duodenum. *Indian J Gastroenterol* 1998;17:152
6. Botrugno I, Gruttadauria S, Li Petri S, et al. Complex hydatid cysts of the liver: a single center's evolving approach to surgical treatment. *Am Surg* 2010;76:1011-5
7. Secchi MA, Pettinari R, Mercapide C, et al. Surgical management of liver hydatidosis: a multicentre series of 1412 patients. *Liver Int* 2010;30:85-93.