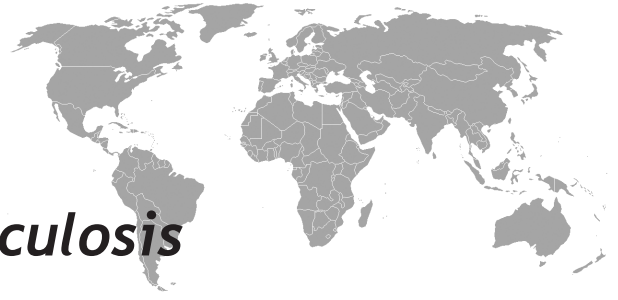



Primary Thyroid Tuberculosis

Murat Kapan¹, Mehmet Toksöz², Şule Dönmez Bakır³, Bilge Çağatay Yazar⁴, Mehmet Sıddık Evsen⁵, Yaşar Bozkurt⁶, Metehan Gümüş¹

¹Dicle University Medical Faculty, Department of General Surgery, Diyarbakır, Turkey.

²Yeni Yaşam Hospital, Department of Radiology, Diyarbakır, Turkey

³Diyarbakır Training and Research Hospital, Department of Pathology, Diyarbakır, Turkey.

⁴Kadirli Public Hospital, Department of General Surgery, Osmaniye, Turkey.

⁵Dicle University Medical Faculty, Department of Gynecology-Obstetrics, Diyarbakır, Turkey.

⁶Dicle University Medical Faculty, Department of Urology, Diyarbakır, Turkey.

Eur J Gen Med 2011;8(4):357-360

Received: 24.05.2010

Accepted: 05.06.2010

Correspondence: Dr. Murat Kapan
Dicle Üniversite Tıp Fakültesi Genel Cerrahi Kliniği 21100-Diyarbakır
Tel: 094122576410-0 412 2289294/2053
E-mail: drmuratkapan@yahoo.com

ABSTRACT

Thyroid tuberculosis is a very rare entity and its diagnosis is based on the histopathological findings. In this report, we presented a 57 year-old woman with palpable neck mass that finally diagnosed as thyroid tuberculosis. Ultrasonography showed bilaterally enlarged thyroid lobes with multiple hypoechogenic heterogenous solid nodules. Except elevated erythrocyte sedimentation rate, all of other laboratory test results including those of thyroid functions were within normal limits. Computed tomography of thorax revealed no abnormality. Intraoperatively purulent hard and irregular masses were seen. Due to suspicion of malignancy, bilateral total thyroidectomy was performed. Histopathological examination confirmed the diagnosis of tuberculosis. The patient received 6 months of antituberculous therapy and put on continuous thyroid hormone replacement.

Key words: Tuberculosis, thyroid gland, extrapulmonary, treatment

Primer Tiroid Tüberkülozu

Tiroid tüberkülozu çok nadir görülür ve tanısı histopatolojik bulgulara dayanır. Bu makalede, 57 yaşında boyunda palpabl kitlesi olup tüberküloz tanısı konulan kadın hasta sunuldu. Ultrasonografide bilateral büyümüş tiroid lobları ve içerisinde çok sayıda heterojen hipoekojenik solid nodüller saptandı. Artmış eritrosit sedimantasyon hızı dışında, tiroid fonksiyonları da dahil olmak üzere diğer tüm laboratuvar test sonuçları normal sınırlarda idi. Bilgisayarlı toraks tomografisinde hiçbir anormallik saptanmadı. Operasyon sırasında pürülan sert ve düzensiz kitleler görüldü. Malignite şüphesi nedeniyle, bilateral total tiroidektomi yapıldı. Histopatolojik incelemede tüberküloz tanısı konuldu. Hastaya 6 ay antitüberküloz tedavi ve sürekli tiroid hormon replasman tedavisi verildi.

Anahtar kelimeler: Tüberküloz, tiroid bezi, akciğer dışı, tedavi

INTRODUCTION

Thyroid gland's infections are uncommon because of its high resistance to infection. In spite of this fact, tuberculosis of thyroid gland can be rarely seen with an incidence of 0.1% - 0.4% (1-3). The clinicians rarely take thyroid tuberculosis into consideration in the different disease of goiter or midline neck swelling and thyroid tuberculosis often mimicking carcinoma (4,5). Tuberculosis of thyroid can be seen in the various histopathological forms, like multiple thyroidal granulomata, goiter with caseification, cold abscess, chronic fibrosing thyroiditis and acute abscess (1-3,6,7). Diagnosis is based on histological study and demonstration of multiple coalesced and caseated epithelioid cell granulomas along with giant cells (1,8). In this paper, we reported a 57 years old woman with primary tuberculosis of thyroid gland in the light of literature.

CASE

A 57 year-old woman presented with a 6 months history of palpable neck mass. There was no history or family history of tuberculosis. On physical examination, a palpable mass, 2 cm in diameter, in the left lobe and another palpable mass, 1,5 cm diameter, in the right lobe of the thyroid gland was detected. There was no palpable lymphadenopathy. The pulse rate was 86/min, blood pressure 110/80 mmHg and fever was 36.8 °C. All vital signs, as well as results of blood and urine analysis and chest X-ray were normal. Her total leucocyte count was 8.600/mm³ with 49.3% neutrophils. ESR was 59 mm/hour (0 - 20 mm/hour). The thyroid function tests were as follows: sensitive thyroid stimulating hormone (TSH) 1.29 (0.27-4.2) µIU/mL, free T3 5.78 (2.8-7.1) pmol/L, free T4 17.6 (12-22) pmol/L, therefore she was euthyroid. The examination of indirect laryngoscopy was normal. Ultrasonography showed bilateral enlarged thyroid lobes and bilateral multiple hypoechoic, heterogeneous solid nodules. There was no regional lymph node and no abnormality in thoracic CT examination in the lung parenchyma and mediastinum. Based on the physical examination, ultrasonography, the patient underwent surgery. Intraoperatively, we noticed that the lesion was purulent, hard, irregular and adherent to the cricoid cartilages. There were some regional lymph nodes. So we thought that it might be an abscess or malignancy. In frozen section examination; the piece of lymph node reported as reactional. But suspicious of malignancy forced us to make bilateral total thyroidectomy.

The culture of purulent discharge was remained sterile. Histopathological examination of the tissue, which measured in greatest diameter 6×5×3 cm right lobe and 5×3×3 cm left lobe, revealed granulomatous necrosis including caseification which consisted epithelioid histiocytes, lymphocytes, fibroblasts and Langhans cells, confirming the diagnosis of tuberculosis. Postoperative second day, the patient had the symptoms of hypocalcaemia and twelfth day a purulent discharge from incision. The discharge was regressed with drainage and antibiotic treatment. We replaced hypocalcemia with calcium carbonate 2500 mg daily and the patient underwent thyroid hormone replacement therapy. After one month; the laboratory findings were as follows; calcium 8.6 (8.4-10.5) mg/dL, phosphor 4.14 (2.6-5.9) mg/dL, parathormone (PTH) 36.6 (15-65) pg/mL. Hypocalcemia was regressed. After the histopathological diagnosis; the patient received anti-tuberculosis therapy with daily doses of 600 mg isoniazid (H), 450 mg Rifampicin (R) and 1500 mg Pyrazinamide (Z) for 2-months and followed four months with 600 mg isoniazid (H), 450 mg Rifampicin (R) (2HRZ\4HR). No side effect or complication was seen.

DISCUSSION

Tuberculosis of the thyroid gland is a rare disease with an incidence of about 0.1%-0.4% (1-3). This can be based on the resistance of thyroid gland to the infections which attributed to a number of factors, as follows; a prosperous lymphatic and vascular supply, well developed capsule, high iodine contents of the gland and bactericidal effect of the colloid and iodine (2,4,6,9,10).

Tuberculosis of the thyroid gland can be primary or secondary and occurs in association with tuberculous infection of the other tissues or organs (6). Frequently secondary extension is seen due to hematogenous dissemination or direct extension from an active laryngeal or nodal focus (6,9,11). In present case, the patient had primary tuberculosis of thyroid gland. No other focus of tuberculosis was found by imaging studies.

In thyroid tuberculosis, duration of presenting symptoms varies from 2 weeks to one year and there is no relationship with age or sex (12). The most common symptoms are fatigue, fever, and night sweating and weight loss. The pressure symptoms, like dysphagia, dyspnea and dysphonia may be present (2,6,12,13).

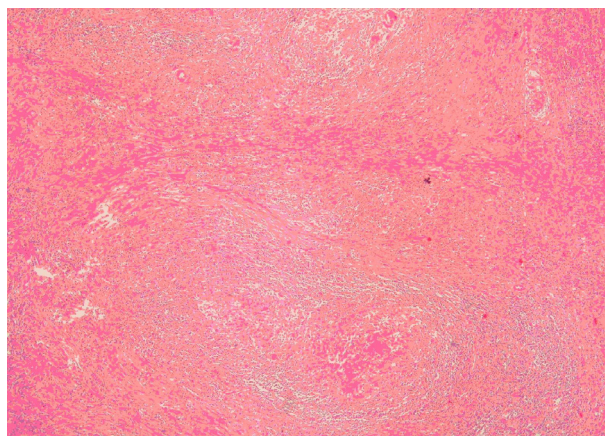


Figure 1. H&E x100 Thyroid gland with granulomatosis including caseification necrosis, epithelioid histiocytes, lymphocytes, fibroblasts and Langhans cells

A high ESR and CRP values may be present (14). Thyroid function test results are usually normal, but sometimes thyrotoxicosis and myxoedema may be present (6,15). In our patient, there were no hypo- or hyperthyroidic symptoms. Thyroid function test results and CRP value were within normal limits. Only, ESR was 59 (0-20) mm/hour. A peripheral low density abscess with regional lymphadenopathy is demonstrated on CT scan and a heterogeneous, hypoechoic mass is seen on ultrasonogram (8). In our patient, ultrasonography showed bilateral enlarged thyroid lobes and bilateral multiple hypoechoic, heterogeneous solid nodules. There was no regional lymph node.

Thyroid tuberculosis is improbably to be suspected clinically because of its rarity and sometimes it is difficult to diagnose preoperatively or during surgery. So, the diagnosis of thyroid tuberculosis is usually based on fine needle aspiration biopsy and the histopathological examination of surgically removed thyroid tissue (6,15,16). When suspected from thyroid tuberculosis, Zeil-Nielson staining for acid fast bacilli, fine needle aspiration biopsy and enzyme amplification (polymerase chain reaction) from the aspirated material are useful tools for diagnosis and should be done (3). Fine needle aspiration biopsy is a simple, rapid and cheap useful diagnostic technique. The diagnosis rate of the thyroid tuberculosis by fine needle aspiration biopsy is 0.6%-1.15% among the thyroid lesions in endemic regions. However, the diagnosis cannot completely remove the necessity

of surgery (6). Demonstration of acid fast bacilli within thyroid tissue, a necrotic or abscessed gland and demonstration of tuberculous foci outside are the criterions which were described in 1939 (8). But nowadays it is stated that acid fast bacilli are not always found, therefore multiple coalesced and caseated epithelioid cell granulomas along with Langhans giant cells and peripheral lymphocytic infiltration are considered the diagnosis of thyroid tuberculosis (8,10). In our patient, we didn't get suspicious about thyroid tuberculosis and the patient underwent surgery. Intraoperatively, we noticed that the lesion was purulent, hard, irregular and adherent to the cricoid cartilages and with the suspicious of malignancy, bilateral thyroid lobes was removed totally. Histopathological examination of the tissue revealed granulomatosis necrosis, including caseification, which consisted epithelioid histiocytes, lymphocytes, fibroblasts and langhans cells, confirming the diagnosis of tuberculosis.

Antituberculosis therapy and removing the affected parts of thyroid gland surgically are the most common treatment modalities for thyroid tuberculosis. The other method is drainage through repeated puncture in combination with antituberculosis therapy (8,16). Recently it has been suggested that antituberculous drugs alone could be effective (10). Anti-tuberculosis treatment includes; 6 months therapy impending 2 months intensive phase and followed by 4 months continuation phase. Our patient received anti-tuberculosis (2HRZ/4HR) therapy according to the Revised National Tuberculosis Control Programme of India after surgery (17).

In conclusion, tuberculosis of thyroid is a rare disease entity. It should be kept in mind when a thyroid disorder and a history of tuberculosis are present. The diagnosis of thyroid tuberculosis is based on fine needle aspiration biopsy and histopathological examination. Surgical and antituberculous therapies are recommended for treatment of thyroid tuberculosis.

REFERENCES

1. Girgin S, Gedik E, Büyükbayram H. Asymptomatic thyroid tuberculosis in a multinodular goitre patient: a case report. *Acta Chir Belg* 2007;107:457-9
2. Bilgin G, Hasanoğlu A, Çakır B, Tümer H, Ustun H, Kudemir A. Tuberculosis of thyroid with cord paralysis: A report of a case. *Med J Kocatepe* 2005;6:67-9
3. Ghosh A, Saha S, Bhattacharya B, Chattopadhyay S. Primary tuberculosis of thyroid gland: a rare case report.

- Am J Otolaryngol-Head Neck Med Surg* 2007;28:267-70
4. Dawka S, Jayakumar J, Ghosh A. Primary tuberculosis of the thyroid gland. *Kathmandu University Med J* 2007;5:405-7
 5. Oklah A, Al-Kaisi N. Thyroid tuberculosis: a case report. *JRMS* 2005;12:60-2
 6. Bulbuloglu E, Ciralik H, Okur E, Ozdemir G, Ezberci F, Cetinkaya A. Tuberculosis of the thyroid gland: review of the literature. *World J Surg.* 2006;30:149-55.
 7. Kang M, Ojilu V, Khandelwal N, Bhansali A. Tuberculous abscess of the thyroid gland: a report of two cases. *J Clin Ultrasound* 2006—DOI 10.1002/jcu
 8. Andrius Simkus. Thyroid tuberculosis. *Medicina* 2004;40:201-4
 9. Mpikashe P, Sathekge MM, Mokgoro NP. Tuberculosis of the thyroid gland: a case report. *SA Fam Pract* 2004;46:19-20
 10. Terzidis K, Tourli P, Kiapekou E, Alevizaki M. Thyroid tuberculosis. *Hormones* 2007;5:75-9
 11. Sharma AB, Kumar LD, Sharma HD, Debnath K, Naorem S. Primary tuberculosis of the thyroid gland - a rarity. *J Indian Acad Clin Med* 2006;7:363-4
 12. Pandit AA, Joshi AS, Ogale SB, Sheode JH. Tuberculosis of thyroid gland. *Ind J Tub* 1997;44:205-7
 13. Razmpa A, Sharifian H, Sadeghi Hasanabadi M, Ilami A, Shahinfar SH. Clinical and paraclinical aspect of thyroid tuberculosis. *Acta Medica Iranica* 2007;45:389-94
 14. Fica S, Barbu C, Sirbu A, Terzea D, Clatici V, Loachim D, Lonescu M. Rare form of tuberculosis presented as thyroid mass. *Acta Endocrinologica (Buc.)* 2005;1:481-7
 15. Hashemi SH, Nadi E. Thyroid tuberculosis presenting as a cystic nodule. *Iran J Med Sci* 2006;31:53-5
 16. Safarpor F, Hedayeti Omami MH, Mohammadi F, Hoda S, Safarpor D. Thyroid tuberculosis. *Iran Red Crescent Med J* 2007;9:161-3
 17. Tewari M, Shukla HS. Breast tuberculosis: diagnosis, clinical features and management. *Indian J Med Res* 2005;122:103-110