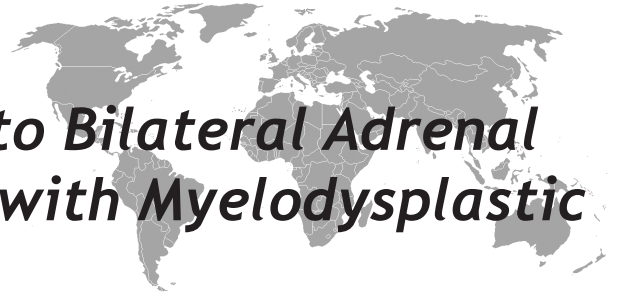


Addison's Disease Due to Bilateral Adrenal Infarction in a Patient with Myelodysplastic Syndrome



Helen A Lockett¹, Clive Hamilton-Wood², Bijay Vaidya¹

Royal Devon and Exeter Hospital, Departments of Endocrinology¹ and Radiology², Exeter EX2 5DW, UK

Eur J Gen Med 2011;8(1):72-4

Received: 12.11.2009

Accepted: 18.12.2009

ABSTRACT

We present an unusual case of Addison's disease due to bilateral adrenal infarction in a patient with myelodysplasia. To our knowledge, bilateral adrenal infarction in association with myelodysplasia has not been reported previously.

Key words: Adrenal, Addison's disease-Infarction-Myelodysplasia

Miyelodisplastik Sendromlu Bir Hastada İki Taraflı Adrenal İnfarktüs Nedeniyle Gelişen Addison Hastalığı

Biz miyelodisplastik sendromlu bir hastada iki taraflı adrenal infarktüs nedeniyle gelişen addison hastalığını sunduk. Bilgilerimize göre böyle bir vaka daha önceden sunulmamıştır.

Anahtar kelimeler: Adrenal, Addison hastalığı, infarktüs, miyrlodisplazi

Correspondence: Dr B Vaidya, Department of Endocrinology, Royal Devon & Exeter Hospital, Barrack Road, Exeter EX2 5DW, UK. Tel: 01392 403082. Fax: 01392 402270. E-mail: bijay.vaidya@pms.ac.uk

INTRODUCTION

Addison's disease (primary adrenal insufficiency) is an uncommon disorder of the adrenal cortex resulting in reduced production of glucocorticoid and mineralocorticoid. In western countries, 80-90% of Addison's disease is caused by autoimmunity (1). Other important causes include infections, bilateral adrenalectomy, malignant infiltration, bilateral infarction or haemorrhage, and genetic (including adrenoleucodystrophy and congenital adrenal hypoplasia). We report a rare case of Addison's disease caused by bilateral adrenal infarction associated with myelodysplasia.

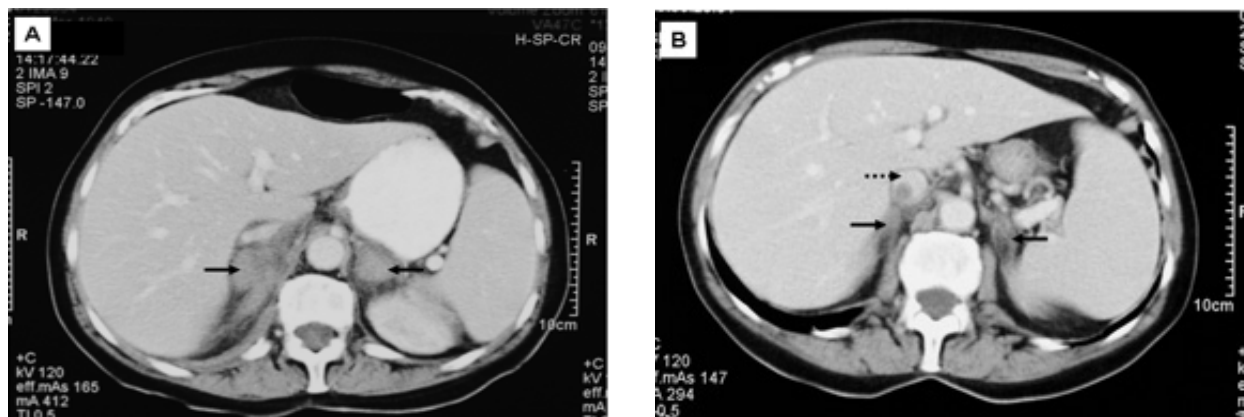


Figure 1. (A) CT scan at presentation showing bilateral adrenal masses (solid arrows). (B) Follow-up CT scan at 6 weeks showing a decrease in the size of the adrenal masses (solid arrows) and a thrombosis within the inferior vena cava (interrupted arrow).

CASE

A 63-year-old lady was admitted with a ten day history of abdominal pain, nausea and vomiting. She was diagnosed with myelodysplasia eleven years previously, and required regular blood transfusions. To prevent excess body iron store, she was also on chelating agent deferoxamine. At presentation, she was afebrile, heart rate was 72 beats/minute in sinus rhythm, and blood pressure was 153/85mmHg. Her abdomen was soft, mildly distended and diffusely tender.

Investigations showed haemoglobin of 10.2g/dL, white cell count $15 \times 10^9/L$ and platelet count $356 \times 10^9/L$. Electrolytes, renal and liver function tests, and serum amylase were normal. Serum ferritin level was 1383 $\mu\text{g/L}$ (reference range 15-200). An abdominal radiograph showed dilatation of a segment of large bowel. Therefore, a CT scan of abdomen was performed, which excluded bowel obstruction but showed bilateral adrenal enlargement (right 3x3.8cm, left 3.1x2.5cm) and a splenic infarction (Figure 1, panel A). A short synacthen test confirmed adrenal insufficiency with basal and stimulated (30 minutes after synacthen) serum cortisol levels of 40nmol/L and 42nmol/L, respectively (normal stimulated cortisol, >550nmol/L). Adrenocorticotrophic hormone was not measured; however, plasma renin was high at 39.2mU/l (reference range 2-30), consistent with primary adrenal insufficiency. She was commenced on hydrocortisone, fludrocortisone and warfarin.

A follow-up CT scan at 6 weeks showed a decrease in the size of adrenal masses consistent with bilateral adrenal infarction, and also revealed a thrombosis within the inferior vena cava (Figure 1, panel B). Screening of adrenal and other autoantibodies was negative. Serum 17-OH progesterone was normal. Investigations for the cause of hypercoagulable state, including Factor V Leiden mutation, prothrombin 20210a variant, cardiolipin antibody and lupus anticoagulant returned negative. Flow cytometry showed a normal expression of CD59 on red blood cells, excluding paroxysmal nocturnal haemoglobinuria. Subsequent serial CT scans over the following months showed progressive atrophy of the adrenal glands. During the next year, her myelodysplasia transformed into acute myeloid leukaemia.

DISCUSSION

Bilateral adrenal infarction is a rare cause of Addison's disease, and usually presents in association with anti-phospholipid syndrome (2). The progressive shrinkage of the adrenal masses, together with the associated splenic infarction and thrombosis within the inferior vena cava, supports the diagnosis of bilateral adrenal infarction in our case. Furthermore, the exclusion of anti-phospholipid syndrome and other common causes of hypercoagulable state suggest that bilateral adrenal infarction in this case is related to myelodysplasia. In view of repeated blood transfusions, secondary haema-

chromatosis is another possible cause of primary adrenal insufficiency in our case. However, the rapid and progressive shrinkage of the adrenal masses are not consistent with this diagnosis.

Platelet dysfunction is common in myelodysplasia resulting in an increased risk of bleeding (3). However, about 8% patients with myelodysplasia have platelet hyperactivity, and are susceptible to thrombosis (4). It is noteworthy that within a year of developing bilateral adrenal infarction, myelodysplasia in our patient was transformed to acute myeloid leukaemia. As haematological malignancies may result in a hypercoagulable state (5), it is also possible that hypercoagulability associated with the pre-leukaemic state predisposed our patient to develop bilateral adrenal infarction. The findings of splenic infarcts and thrombosis within the inferior vena cava in addition to bilateral adrenal infarct in our patient suggested a generalised hypercoagulable state, and the patient was treated with long-term warfarin.

In summary, we present an unusual case of Addison's disease due to bilateral adrenal infarction. We hypothesize that hypercoagulable state associated with myelo-

dysplasia contributed to the development of bilateral adrenal infarction. To our knowledge, bilateral adrenal infarction in association with myelodysplasia has not been reported previously.

REFERENCES

1. Arlt W, Allolio B. Adrenal insufficiency. *Lancet* 2003; 361:1881-93.
2. Espinosa G, Santos E, Cervera R, et al. Adrenal involvement in the antiphospholipid syndrome: clinical and immunologic characteristics of 86 patients. *Medicine (Baltimore)* 2003; 82:106-18.
3. Mittelman M, Zeidman A. Platelet function in the myelodysplastic syndromes. *Int J Hematol* 2000; 71:95-8.
4. Manoharan A, Brighton T, Gemmell R, Lopez K, Moran S, Kyle P. Platelet dysfunction in myelodysplastic syndromes: a clinicopathological study. *Int J Hematol* 2002; 76:272-8.
5. Kwaan HC, Vicuna B. Incidence and pathogenesis of thrombosis in hematologic malignancies. *Semin Thromb Hemost* 2007;33:303-12.