



Juvenile Nasopharyngeal Angiofibroma

Mehmet Fatih Garça¹, Sevil Ari Yuca², Köksal Yuca³

¹İpekyolu Public Hospital, Department of Otolaryngology, Van

²Women Maternity and Children's Hospital, Department of Pediatrics, Van, Turkey

³Yüzüncüyıl University, Department of Otolaryngology, Van, Turkey

Eur J Gen Med 2010;7(4):419-425

Received: 12.02.2010

Accepted: 09.03.2010

ABSTRACT

Review of the literature was performed to define the optimal treatment of patients with juvenile nasopharyngeal angiofibroma (JNA). The prognosis for this disease is extremely good if diagnosed well in time and if the tumor has not extended intracranially. Preoperative selective arterial embolization has decreased intraoperative blood loss and facilitated resection of larger tumors. Transnasal endoscopic resection preserves both the anatomy and physiology of the nose, requires less rehabilitation days after surgery, and is highly successful for selected patients. Radiation therapy is generally reserved for larger and/or unresectable tumors but has severe complications. Radiosurgery has several advantages over surgery or classic radiation therapy. However, further experiences and studies are required to confirm the usefulness of radiosurgery on JNA.

Key words: Juvenile nasopharyngeal angiofibroma, histopathology-embolization, treatment, radiosurgery

Correspondence: Dr Mehmet Fatih Garça;
İpekyolu Devlet Hastanesi KBB Servisi,
Van/Turkey
Phone: 904322179398, Fax: 904322176370
E-mail: fatihgarca@hotmail.com

INTRODUCTION

Juvenile nasopharyngeal angiofibroma (JNA) represents 0.05% to 0.5% of all head and neck tumors but is the common tumor of nasopharynx (1,2). It affects almost exclusively male adolescents. The median age at diagnosis is 15 years (2-4). Histological benign appearance is often counterbalanced by a potentially malignant clinical course, due to severe epistaxis, involvement of endocranial structures with occasional surgical difficulties and complications, and a high incidence of recurrence.

Patients usually present at late stage of the disease that arises from either the lateral wall or the roof of the nasopharynx especially the sphenopalatine foramen (1,3-5). The blood supply is most commonly from the internal maxillary artery. Histologically tumor blood vessels typically lack smooth muscle and elastic fibres (3,5,6). Severe epistaxes accompanied by progressive nasal obstruction are the classical symptoms of juvenile angiofibromas at the time of presentation.

There are a variety of staging criteria developed when evaluating JNAs which include those developed by Radkowski, Fisch, Andrews, Onerci and Sessions (2,5,7-11). Its classical treatment is surgery; however there are cases in which may indicate radiotherapy or even hormone therapy and gamma knife surgery (GKS) (2).

Currently it is advisable to perform a selective tumoral embolization prior to proceeding with any of the techniques known in order to facilitate surgical access (5,7-10). Advances in technology and improvements in endonasal technique enable the use of nasal endoscopic surgery to remove some tumors that would traditionally have been extracted by using an open surgical approach.

Histopathology

Histologically angiofibroma is always composed of an intricate mixture of blood vessels and fibrous stroma. The JNA characteristic manifestation in the male sex and young people, in a period of great hormonal influence has raised suspicion about the role of sexual hormones in its pathogenesis (3-4,11-13).

Microscopically, there are plump fibroblasts, ovoid to spindle shaped, with a generous amount of connective tissue. In the compact stroma are blood vessels of different sizes and shapes lined by plump endothelial cells but with little or no smooth muscle or elastic fibers (5-6,11) (Figure 1). This lack of muscle undoubtedly contributes

Table 1. JNA Symptoms

Other Common Symptoms

Swelling Of The Cheek

Hearing Loss

Dacrocystitis

Rhinorrhea

Hard And Soft Palate Deformity

Hyposmia Or Anosmia

Advanced Lesions May Causes

Proptosis

Diplopia

Visual Loss

Facial Pain And/Or Headache

Cranial Neuropathy

Trismus

to the tumor's capacity for massive hemorrhage following minimal manipulation.

The spontaneous regression in a few patients and the malign transformation in very rare cases altogether suggest the existence of complex genetic mechanisms in its pathogenesis (14). The high JNA vascularization, confirmed by immunohistochemistry, is directly related to the angiogenic growth factor (vascular endothelial growth factor (VEGF)) associated with the proliferation and high vascular density of the tumor regions (5,15). It has been found localized on both endothelial and stromal cells. However, neither the proliferative index nor VEGF expression seem to bear any relation whatsoever to the stage of the JNA; in other words, its degree of aggressiveness (5,13).

Disorders in protooncogene MYC expression are a cause for alteration in the proliferation, growth and cellular metabolism, and are associated to a large range of malignity (12). Transformation of fibroblasts into endothelial cells caused by the angiogenic capacity of the c-MYC protein building up an immature vascular network appears possible in JNAs. C-MYC may be connected with more aggressive growing phenotypes in the JNA (3,5,12). Insulin-like growth factor II (IGFII) has been found with increased expression in 53% of the tumor tissues of patients with JNA. An IGFII overexpression was detected at important levels (16) associated with the loss of the cellular cycle control. It might be associated with a tendency to recurrence and poorer prognosis (5). Adenomatous Polyposis Coli (APC) gene, on chromosome 5q, produces a tumor suppressor protein (3,5,12,14). Familial adenomatous polyposis (FAP) is associated with mutations of the APC gene. JNA have also been reported to develop 25 times more fre-

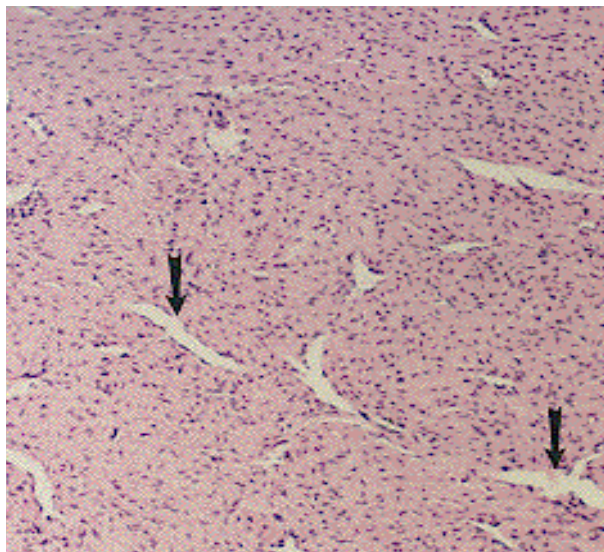


Figure 1. Angiofibroma; Staghorn-shaped blood vessels (arrows) with endothelial cells but no smooth muscle are compressed by fibrous tissue

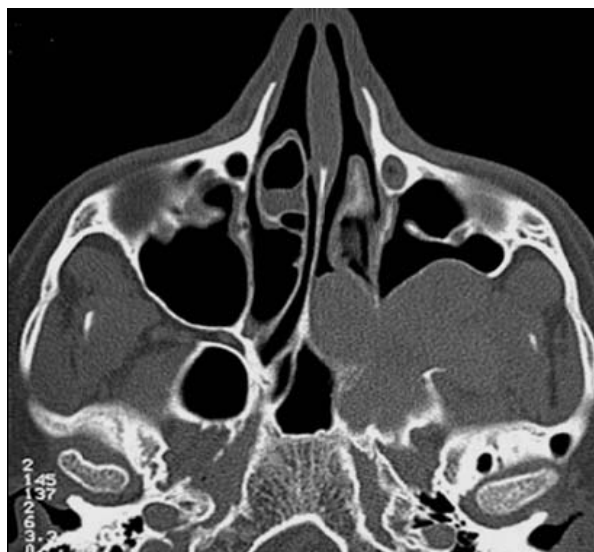

Figure 2. Axial CT; The posterior wall of the maxillary sinus has been bowed anteriorly (arrowed)

quently in patients with FAP (3,5,14). This gene regulates the beta-catenin pathway which influences cell to cell adhesion. Mutations of beta-catenin have been found in sporadic and recurrent JNA (13).

Presentation

As always, patient history and physical examination are of paramount importance in initiating patient evaluation. The diagnosis of angiofibroma may be overlooked initially despite the heightened awareness of its existence in male adolescents. JNAs classically present with unilateral nasal obstruction, epistaxis and nasopharyngeal mass in adolescent males (1,4-5,11,15). In most, there is a delay of at least six or seven months between the onset of symptoms and presentation (5). Other symptoms and physical examination findings are shown on Table 1, 2.

Table 2. JNA Physical Examination

Physical examination
Male adolescent
Mucopurulent secretions in the nasal cavity
Soft palate is often displaced inferiorly
Pink or reddish mass
Smooth lobulated mass in the nasopharynx

The JNA must be differentiated from several other lesions commonly occurring in the nose and nasopharynx (Table 3). The tumor lacks a capsule and spreads submucosally (1,3-5,11,14). It tends to extend along natural foramina and fissures not invading bone but often eroding it by pressure atrophy. Transnasal biopsy is not necessary and can provoke brisk hemorrhage. Modern imaging techniques of CT and MR Scans are the most important tools for the diagnosis of JNA (8). CT diagnosis is made on coronal sections by the presence of a soft tissue mass in the posterior nasal cavity combined with enlargement of the sphenopalatine foramen and erosion of its posterior bony margin. Demonstration of the anterior bowing of the posterior maxillary wall due to the presence of a mass in the pterygomaxillary space on axial CT slices known as the Holman-Miller sign, is characteristic finding

Table 3. Other Lesions Of Nose And Nasopharynx

Differentiated diagnosis in nose and nasopharynx
Hemangioma
Choanal polyp
Nasopharyngeal carcinoma
Angiomatous polyp
Nasopharyngeal cyst
Hemangiopericytoma
Rhabdomyosarcoma
Chordoma

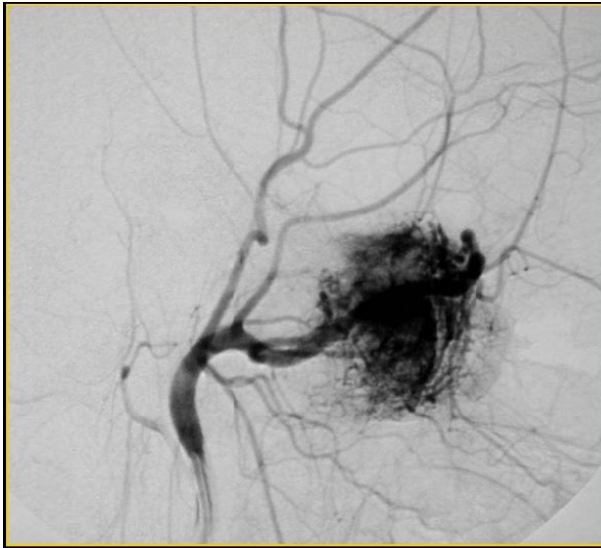


Figure 3. Angiogram; Blood supply of the tumor from the internal maxillary artery. Before embolization

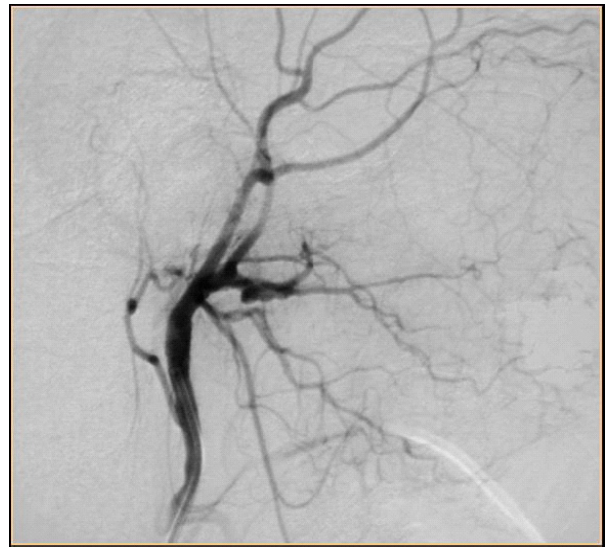

Figure 4. After embolization of the internal maxillary artery.

of JNA (1,5,11) (Figure 2). Early postoperative CT is reliable in detecting or excluding residual disease in patients with JNA (2,24). MRI provides additional assessment of the tumor's interface with adjacent soft tissue and is particularly valuable in evaluating intracranial and cavernous sinus extension.

Staging

Authors have classified JNA on the basis of its location and extension (17). There are many classification described although none is universally accepted (7-8). There are a variety of staging criteria developed for evaluating JNAs which include those developed by Radkowski, Fisch, Andrews, Chandler, Johns, Onerci and Sessions (1,4-5,7-11) although none is universally accepted. In several staging systems that of Andrews (1989) is the most robust and practical for exclusively endoscopic surgery for JNAs¹⁷. Another staging system is Radkowski (1996) that is the most recently developed staging system and appears most commonly in recent literature on JNAs (11).

Treatment

Surgery is the gold standard of treatment for JNA. Treatment options for JNAs include chemotherapy, hormone administration, radiation therapy, embolization. Today, these modalities are used only as occasional complementary treatment (1,4,7-9,18-19).

Hormone therapy

Hormonal stimulation appears to play an important role with regards to growth of JNAs (11). It has been proposed due to the androgen receptors associated with JNAs in an attempt to decrease tumor size and vascularity (21). Anti-androgenic agents like flutamide may reduce the growth rate of the JNA in vitro³, and in a small series of patients given flutamide, tumor shrinkage of up to 44 percent was reported by Gates et al (20). Estrogen has been shown to decrease size and vascularity of the tumor, but has feminizing side effects, variable response, and risk of cardiovascular complications (11). Androgen receptor, other steroid receptors have already been detected (3,21) however, neither changes are found in the sexual hormones serum levels nor changes in the JNA patients sexual maturity.

Radiotherapy

The use of radiotherapy for the primary treatment of angiofibroma has been advocated in recent publications. External beam radiation is generally reserved for larger and/or unresectable tumors and tumors that are life threatening due to their location (2,11,19). Studies by Briant et al. and Cummings et al. both reported an 80% control rate with moderate dose primary radiotherapy (30 to 35 Gy given in 15 fractions over a 3 week period) (5,23). Additional other authors have reported good re-

sults after radiotherapy for surgically inaccessible intracranial extension or for recurrences following a primary procedure (11,25). Long-term severe complications of radiation therapy are encountered including growth retardation, panhypopituitarism, temporal lobe necrosis, cataract, and radiation keratopathy (2,5,23). Also others reported remote secondary malignancy of the head and neck such as thyroid carcinoma and sarcomas of bone-soft tissue (23) a serious adverse effect of radiation therapy on JNA. Intensity-modulated radiation therapy as known radiosurgery, has been tried for the management of extensive and recurrent JNA (25). Management of JNA by gamma knife surgery (GKS) (2), also known as radiosurgery, has rarely been tried. Dare et al. (26) recently reported two cases of successful GKS application in JNA as a booster treatment for residual tumor after surgical resection. It is not as invasive as surgery that is almost free of acute complications in surgery including massive hemorrhage (2). Besides it is completed in a single-session of a day treatment with no need to prolonged hospital stay.

Embolization

JNA consists of proliferating, irregular vascular channels within a fibrous stroma. Tumor blood vessels typically lack smooth muscle and elastic fibers, this feature contributing to its reputation for sustained bleeding. Some authors consider preoperative embolization or ligation of the major feeding vessels for decreasing the vascularity of the tumor (5,9-10,17,19,27,32). Blood supply is most commonly from the internal maxillary artery, but may also be supplied by the external carotid artery, the internal carotid artery, the common carotid artery, or the ascending pharyngeal artery. Preoperative selective arterial embolization of feeding vessels from the external carotid artery has significantly decreased intraoperative blood loss and facilitated resection of larger tumors (Figure 3, 4) and rendered intraoperative or postoperative blood transfusions unnecessary (18).

Most of the authors use resorbable particles such as gel-foam or dextran microspheres or short duration non-absorbable such as Ivalon, ITC contour or Terbal, polyvinyl-alcohol particles, which last longer and are more efficient (11). The ideal time between tumor embolization and the surgical procedure should be around 24 to 72 hours (27). Many papers also point out the benefits of preoperative arterial embolization in controlling intraoperative bleeding (1,4-5,9-10,27), reducing it by as much as fifty per-

cent, thus allowing the full excision of the tumor (9-10, lower relapse rates and neurological complications (28), and reduced surgery duration. However some authors consider preoperative embolization to provide no benefit, or even to increase the risk of recurrence (22). Complication of preoperative embolization rates may be as high as 20% (29). Such complications may include occlusion of the central retinal artery and consequent temporary blindness, oronasal fistula due to tissue necrosis, occlusion of the middle cerebral artery followed by stroke, and occlusion of the ophthalmic artery (10,27,29).

Surgery

Liston (1841), performed the first successful resection of an angiofibroma on a 21-year-old man from Gibraltar (5). The treatment of choice in the vast majority of patients is surgical resection. Surgical techniques for JNAs include open surgical approach and endoscopic surgery or combined those techniques depending on the stage of the tumor. Several factors are critical when choosing the surgical technique for JNA; adequate exposure of the tumor, ability to control bleeding, prevention of postoperative facial deformity and avoidance of interference with growth of the face (8,18-19).

Open Surgical Approach

Open surgical approaches are transoral, transfacial, and combined craniofacial approaches (5) (more specifically transpalatal, transantral, transnasal, lateral rhinotomy, midfacial degloving, LeFort 1 osteotomy, and infratemporal fossa approach). Lateral rhinotomy approach has the advantage of access to the nose, maxillary antrum, ethmoids and nasopharynx, pterygopalatine fossa (8). However it leaves an external scar and removal of nasal and facial bones in prepubertal boys could lead to facial asymmetry (8). Persistent nasal crusting, facial paresthesia, lacrimal apparatus injuries are also seen in this approach. Midfacial degloving approach provides good exposure to the maxillary antrum, nose, pterygopalatine fossa and infratemporal fossa. There will be no deforming scar on face because of the use of a sub labial incision, but needs extensive removal of bones from the anterior, posterior, medial and lateral walls of maxillary antrum (8). Transpalatine approach provides access to the nasopharynx, sphenoid, sphenopalatine foramen and posterior nares. It avoids external scar and does not affect the facial growth but oronasal fistula is a more common side

effect (8). This approach was selected in the majority of patients with advanced disease by Cansiz et al (30). Open approaches are favored by some surgeons and remain indicated for larger JNAs (11). Additionally all open approaches can be supplemented by the use of endoscopes.

Endoscopic Surgery

Improvements in endonasal technique and knowledge of the intranasal anatomy enable the use of nasal endoscopic surgery to remove some JNA tumors. The decision to perform JNA resection endoscopically should be based on the experience and skill of the surgeon as well as the extent of the tumor (7-10,17). Endoscopic sinonasal surgery and embolize these tumors preoperatively is to allow atraumatic dissection, minimizing bleeding and more precise tumor resection, thus minimizing the possibility of residual tumor (9,17,28). Patient selection for endoscopic resection is of paramount importance for a successful outcome. It has been suggested that tumors involving the ethmoid, maxillary, or sphenoid sinus, the sphenopalatine foramen, nasopharynx, pterygomaxillary fossa and have limited extension into the infratemporal fossa are amenable to endoscopic resection (9-10,17,27-28). Onerci et al. reported no recurrence for tumors extension into infratemporal fossa (7,31).

Endoscopic surgery has a great advantage because it preserves both the anatomy and physiology of the nose, requires less rehabilitation days after surgery, requiring less days of hospitalization and is less subject to hospital infections (8). The "push-pull" technique involves an incision of about 1 inch in the upper bucco-gingival sulcus, one more step in the evolution of endoscopic surgery for JNA (17,32). It is now possible to excise tumors with large lateral extensions in the infratemporal and parapharyngeal regions without resorting to an open approach.

Despite technological and surgical advances the recurrence rates have been reported between 30 and 50% (5,11), most symptomatic recurrences occurring during the first 12 months after primary treatment (11). Unfortunately, recurrent tumors are often reactivated residual tumors (5,24-25). The primary factor affecting recurrence was found to be the tumor stage at the time of diagnosis (11). The younger the patient the more likely that future recurrence will develop. Not surprisingly, recurrence is more likely in patients with advanced disease.

Summary

JNA is a particularly important disease in otolaryngological practice. It is a rare, vascular, benign tumor with high recurrence, and typically affects adolescent boys. The prognosis for this disease is extremely good if diagnosed well in time and if has not extended intracranially. Preoperative angiography and embolization minimize the intraoperative blood loss and the current shift in the treatment to endoscopic excision in selected lesions reduces perioperative morbidity. Additionally, endoscopic technique can be used in conjunction with open approaches to improve visualization. In view of the very high incidence of recurrent disease, prolonged clinical and radiological monitoring is necessary for all these patients. Primary radiation should be used when the morbidity of surgical resection is unacceptable. With regard to delayed complications, radiosurgery has less chance of risk than conventional radiation therapy theoretically. Further experiences and studies are required to confirm the usefulness of radiosurgery on JNA.

REFERENCES

1. Gohar Ms, Rashid D, Ahmed B. Common presenting symptoms diagnosis and management of angiofibroma - a study of twenty cases. *Pak J Med Sci* 2004; 20:377-80
2. Park CK, Kim DG, Paek SH, Chung HT, Jung HW. Recurrent juvenile nasopharyngeal angiofibroma treated with gamma knife surgery. *J Korean Med Sci* 2006;21:773-7
3. Andrade NA, Andrade JSC, Silva PDM, Oliveira VB, Andrade BB. Nasopharyngeal angiofibroma: review of the genetic and molecular aspects. *Intl. Arch. Otorhinolaryngol., São Paulo* 2008;12:442-9
4. Mendenhall WM, Werning JW, Hinerman RW, Amdur RJ, Villaret DB. Juvenile nasopharyngeal angiofibroma: Review article. *J HK Coll Radiol* 2003;6:15-9
5. Gleeson M. Juvenile angiofibroma. In Gilbert RW, Gleeson M, Scott-Brown WG. *Scott-Brown's Otorhinolaryngology Head and Neck Surgery*. Hodder Arnold 2008;187:2237-45
6. Wenig BM. Angiofibroma (juvenile nasopharyngeal angiofibroma) In: *Atlas Of Head And Neck Pathology* 2008.
7. Onerci M, Oğretmenoğlu O, Yücel T. Juvenile nasopharyngeal angiofibroma: a revised staging system. *Rhinology* 2006;44:39-45
8. Ahmed Z, Mutiullah S, Rahim D, Marfani MS. Juvenile nasopharyngeal angiofibroma: Stage and surgical approach. *Jlumhs* 2009;8:37-40
9. Ferreira LM, Gomes EF, Azevedo JF, Souza JR, Araújo R, Rios AS. Endoscopic surgery of nasopharyngeal angiofibroma. *Rev Bras Otorrinolaringol* 2006;72:475-80.
10. Andrade NA, Pinto JA, Nóbrega Mde O, Aguiar JE, Aguiar

- TF, Vinhaes ES. Exclusively endoscopic surgery for juvenile nasopharyngeal angiofibroma. *Otolaryngol Head Neck Surg* 2007;137: 492-6.
11. Quinn FB, Ryan MW, Ulualp S. Juvenile Nasopharyngeal Angiofibroma. Source: Grand Rounds Presentation, UTMB Department of Otolaryngology Head and Neck Surgery. Date: January 3, 2007
 12. Schick B, Wemmert S, Jung V, Steudel WI, Montenarh M, Urbschat S. Genetic heterogeneity of the MYC oncogene in advanced juvenile angiofibromas. *Cancer Genet Cytogenet* 2006;164:25-31
 13. Abraham SC, Montgomery EA, Giardiello FM, Wu TT. Frequent b-catenin mutations in juvenile nasopharyngeal angiofibromas. Copyright © American Society for Investigative Pathology. *Am J Pathol* 2001;158(3):
 14. Makek MS, Fisch U, Andrews JC. Malignant transformation of a nasopharyngeal angiofibroma. *Laryngoscope*. 1989; 99:1088-1092
 15. Brieger J, Wierzbička M, Sokolov M, Roth Y, Szyfyer W, Mann WJ. Vessel density, proliferation, and immunolocalization of vascular endothelial growth factor in juvenile nasopharyngeal angiofibromas. *Arch Otolaryngol Head Neck Surg*. 2004; 130: 727-731
 16. Coutinho-Camillo M, Brentani MM, Butugan O, Torloni H, Nagai MA. Relaxation of imprinting of IGFII gene in juvenile nasopharyngeal angiofibromas. *Diagn Mol Pathol*. 2003; 12:57-62
 17. Hackman T, Snyderman CH, Carrau R, Vescan A, Kassam A. Juvenile nasopharyngeal angiofibroma: The expanded endonasal approach. *Am J Rhinol Allergy*. 2009 Jan-Feb; 23(1): 95-9
 18. Mann WJ, Jecker P, Amedee RG. Juvenile angiofibromas: changing surgical concept over the last 20 years. *Laryngoscope*. 2004;114: 291-3
 19. Tang IP, Shashinder S, Gopala Krishnan G, Narayanan P. Juvenile nasopharyngeal angiofibroma in a tertiary centre: Ten-year experience. *Singapore Med J*. 2009 Mar; 50 (3): 261-4.
 20. Gates GA, Rice DH, Koopmann CF, Schuller DE. Flutemide-induced regression of angiofibromas. *Laryngoscope*. 1992; 102: 641-4
 21. Hagen R, Romalo G, Schwab B, Hoppe F, Schweikert HU. Juvenile nasopharyngeal angiofibroma: androgen receptors and their significance for tumor growth. *Laryngoscope*. 1994, 104: 1125-29
 22. Fonseca AS, Vinhaes E, Boaventura V, Andrade NA, Dias LA, Medeiros V, Coifman F. Surgical treatment of non-embolized patients with nasoangiofibroma. *Braz J Otorhinolaryngol*. 2008; 74: 583-7.
 23. Park KS, Lee YG, Park HS, Kim JB. Radiation-induced osteosarcoma: report of a case. *J Korean Assoc Maxillofac Plast Reconstr Surg*. 1998; 20: 379-82
 24. Kania RE, Sauvaget E, Guichard JP, Chapot R, Huy PT, Herman P. Early postoperative ct scanning for juvenile nasopharyngeal angiofibroma: detection of residual disease. *AJNR Am J Neuroradiol*. 2005; 26: 82-8
 25. Kuppersmith RB, Teh BS, Donovan DT, Mai WY, Chiu JK, Woo Y, Butler EB. The use of intensity modulated radiotherapy for the treatment of extensive and recurrent juvenile angiofibroma. *Int J Pediatr Otorhinolaryngol*. 2000; 52: 261-8
 26. Dare AO, Gibbons KJ, Proulx GM, Fenstermaker RA. Resection followed by radiosurgery for advanced juvenile nasopharyngeal angiofibroma: report of two cases. *Neurosurgery*. 2003; 52: 1207-11
 27. Nicolai P, Berlucchi M, Tomenzoli D et al. Endoscopic surgery for juvenile angiofibroma: when and how. *Laryngoscope*. 2003; 113: 775-82
 28. Roger G, Tran Ba Huy P, Froehlich P, Van Den Abbeele T, Klossek JM, Serrano E, Garabedian EM, Herman P. Exclusively endoscopic removal of juvenile nasopharyngeal angiofibroma: trends and limits. *Arch Otolaryngol Head Neck Surg*. 2002;128: 928-35
 29. Atalar M, Solak O, Müderris S. Juvenile nasopharyngeal angiofibroma: Radiologic evaluation and pre-operative embolization. *KBB-Forum*. 2006; 5: 58-61
 30. Cansız H, Güvenç MG, Sekercioğlu N. Surgical approaches to juvenile nasopharyngeal angiofibroma. *J Craniomaxillofac Surg*. 2006; 34: 3-8
 31. Önerci TM, Yücel OT, Öğretmenoğlu O. Endoscopic surgery in treatment of juvenile nasopharyngeal angiofibroma. *Int J Pediatr Otorhinolaryngol* 2003; 67: 1219-25
 32. Bradoo RA, Joshi AA, Pahtan FA, Kalel KP. The push-pull technique in the management of giant JNAs. *Bombay Hospital Journal*, Vol. 50, No. 2, 2008