

# FORMALDEHYDE-INDUCED DAMAGE IN LUNGS AND EFFECTS OF CAFFEIC ACID PHENETHYL ESTER: A LIGHT MICROSCOPIC STUDY

Aslı Özdem Türkoğlu<sup>1</sup>, Mustafa Sarsılmaz<sup>1</sup>, Neriman Çolakoğlu<sup>2</sup>,  
İsmail Zararsız<sup>1</sup>, Tuncay Kuloğlu<sup>2</sup>, Hıdır Pekmez<sup>3</sup>, Ufuk Taş<sup>1</sup>

Firat University, Faculty of Medicine, Departments of Anatomy<sup>1</sup> and Histology and Embryology<sup>2</sup>, and Firat University, School of Health Sciences<sup>3</sup>, Elazığ, Turkey

**Aim:** The aim of this study was to investigate the toxicity of formaldehyde on lung and protective effects of caffeic acid phenethyl ester against these toxic effects.

**Methods:** For this purpose, 21 male Wistar rats were divided into three groups. The rats in Group I comprised the controls, while the rats in Group II were injected with formaldehyde (FA). The rats in Group III received CAPE daily while exposed to formaldehyde. After the treatment, lungs tissues were evaluated by microscopic examination.

**Results:** In the microscopic examination of FA group, fatty and cellular infiltration in the pulmonary interstitium and thickening in the bronchiolar wall were evident. Dilatation and congestion were prominent in the alveolar septal vessels. In FA+CAPE group, dilatation of interalveolar septal vessels was less observed than FA group. Bronchial wall structures are similar with control.

**Conclusion:** It was thought that FA exposure leads to inflammation and injury in lungs. CAPE shows protective and anti inflammatory activity against these adverse effects.

**Key words:** Formaldehyde, caffeic acid phenethyl ester, lung.

*Eur J Gen Med 2008;5(3):152-156*

## INTRODUCTION

Formaldehyde is used as a sterilizing agent, disinfectant and preservative in many occupational areas and at home (1). Motor vehicle exhaust, the burning of gas, oil, coal, wood, rubbish and photochemical smog are some environmental sources for formaldehyde. It is colorless gas has a pungent odor and is irritating to the mucous membranes of the nose, throat and eyes (2). The toxicity of formaldehyde is of concern to all who work closely with it. Embalmers, anatomists, technicians and medical, dental or veterinary students are among the people who have high exposure to formaldehyde (3). Formaldehyde poses many potentially detrimental effects to body systems. Many animal studies showed that exposure to formaldehyde cause serious harm on the respiratory system. The primary target for FA-induced toxicity in both rodents and monkeys are the respiratory nasal epithelium (4). Long-term formaldehyde inhalation at a dose of 15 ppm was induced squamous cell carcinomas in the nasal cavities of rats

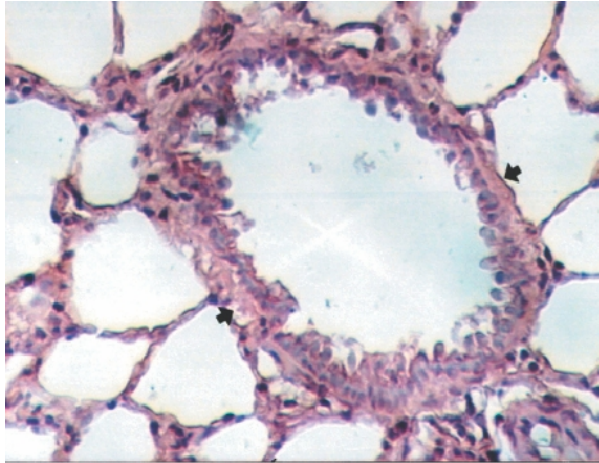
and mice (5). Carpet factory workers who occupationally exposed to formaldehyde were presented loss of respiratory function (6).

CAPE is one of the active constituents of the propolis, a substance with a sharp and pleasant odor that is found in the plant extracts accumulated by bees (7). It has been used in the treatment of many diseases by folk medicine (8, 9). CAPE has antioxidant, antibacterial, anti-inflammatory, and antiviral effects. It also presents immune stimulator, anti mitogenic carcinostatic, anti atherosclerotic, anti proliferative, anti apoptotic characteristics (10).

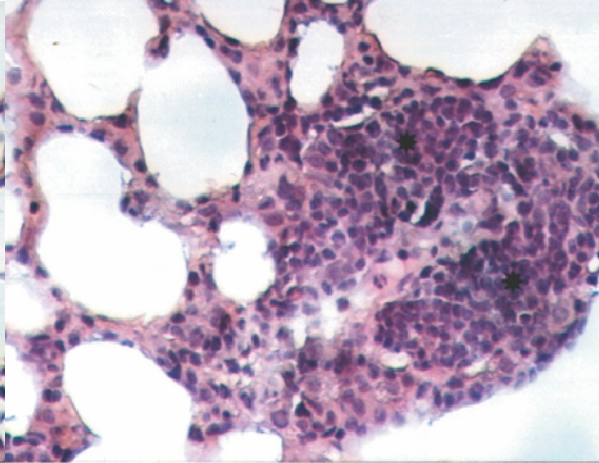
## MATERIAL AND METHODS

Adult male Wistar albino rats (weighing 200–250 g) obtained from Firat University Medical Faculty Experimental Research Unit were randomly divided into three groups with seven animals per group. All animals received human care in compliance with the European Community Guidelines on the care and

*Correspondence:* Prof. Dr. Mustafa Sarsılmaz,  
Firat University, Faculty of Medicine, Department of  
Anatomy, 23119 Elazığ, Turkey.  
Tel: 904242370000 (ext: 4651), Fax: 904242379138  
E-Mail: msarsilmaz@firat.edu.tr



**Figure 1.** Normal bronchiole (arrows) was observed in the control group. Hematoxylin Eosin x 20



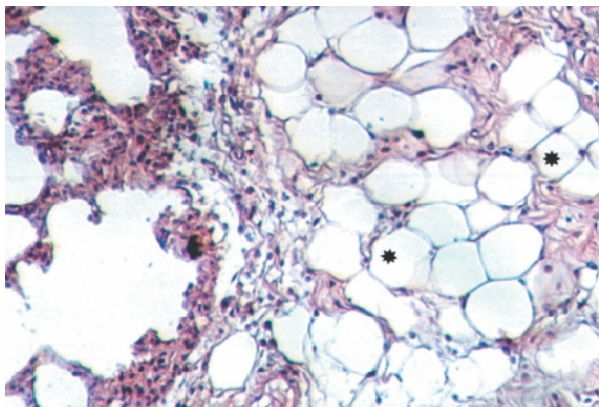
**Figure 2.** Cellular infiltration (asterisks) was seen in pulmener interstitium in FA group. Hematoxylin Eosin x 20

use of laboratory animals (86/609/EEC). The rats were kept in Plexiglas cages (4 rats/cage) where they received standard chow (supplied from Elazig Feed Plant, Elazig, Turkey) and water ad libitum in an air-conditioned room with automatically regulated temperature ( $22\pm 1^{\circ}\text{C}$ ) and lighting (07.00–19.00 h). The rats in the control group received  $10\mu\text{mol/kg}$  ethanol for 8 days, while Group II (FA) received intra peritoneally  $10\text{mg/kg}$  FA at the 4th day of the experiment. Group III (FA+CAPE) was administered  $10\mu\text{mol/kg}$  CAPE starting from the first day throughout 8 days and  $10\text{mg/kg}$  FA starting from the 4th day. All the groups received the determined agents at determined dose for eight days. At the end of the experimental

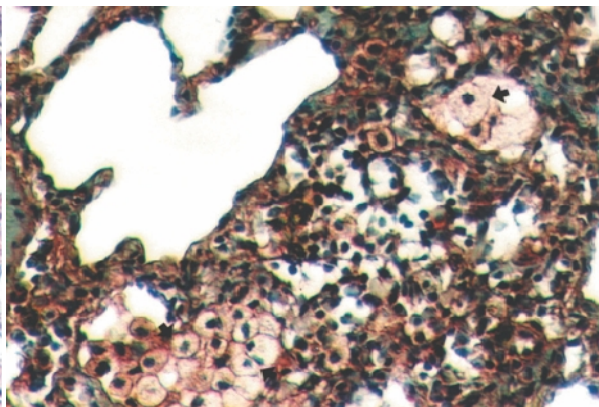
period, the thoracic cavities of all rats were opened and lungs were removed for histopathologically evaluation. Then these specimens fixed in formaldehyde solution. After a series of histological procedure, they were embedded into paraffin blocks. Tissue sections were stained Hematoxylin-Eosine, Masson's trichrom and PAS (Periodic Acid Schiff). The findings were evaluated under an Olympus BH-2 light microscopy.

## RESULTS

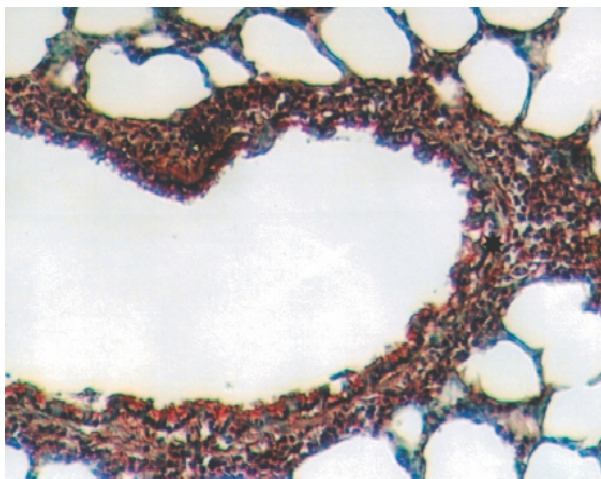
Normal pulmonary histology was revealed at the control group (Figure 1). Microscopic examination of the FA group, fatty and cellular infiltration in the pulmonary interstitium (Figure 2, 3),



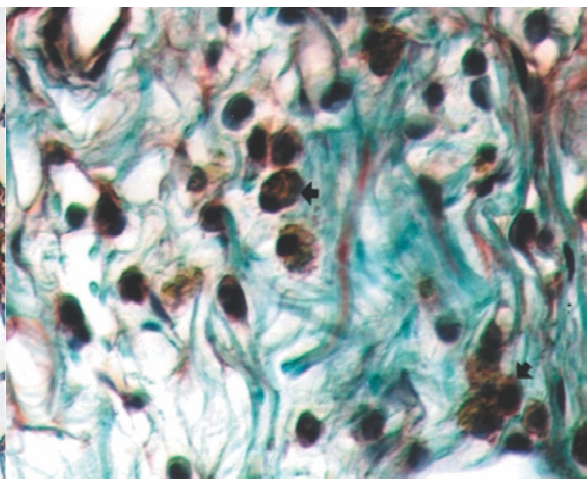
**Figure 3.** Lubrication (asterisks) was observed in pulmener interstitium in FA group. Hematoxylin Eosin x 10



**Figure 4.** Foamy macrophage accumulation (arrows) was seen in pulmener interstitium in FA group. Masson's Trichrome x 20



**Figure 5. Thickening of bronchiolar walls (asterisks) was determined in FA group. Masson's Trichrome x 10**



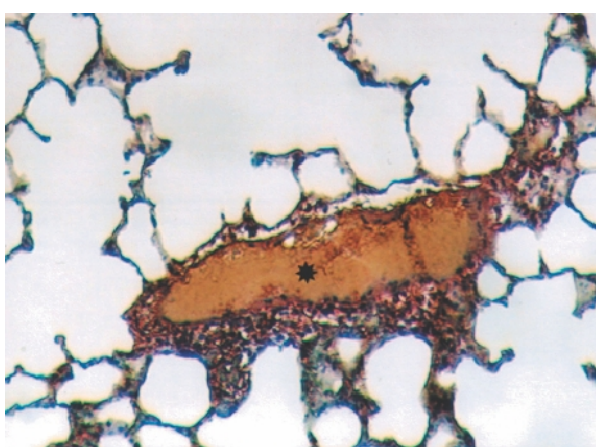
**Figure 6. Pigmented cells (arrows) was evident in peribronchiolar area in FA group. Masson's Trichrome x 40**

foamy macrophages accumulation (Figure 4), thickening in the bronchiolar wall (Figure 5) were observed. Pigmented and pycnotic nucleated cells were observed in the peribronchiolar area (Figure 6). Moreover, dilatation and congestion were prominent in the alveolar septal vessels (Figure 7). In the FA+CAPE group, foamy macrophages accumulation (Figure 8) and inflammatory cell infiltration in the pulmonary interstitium were prominent. Dilatation of inter alveolar septal vessels was less observed than the FA group. Bronchial wall structures (Figure 9) were similar to the control group. Fatty infiltration was not detected in this group. Additionally, decreased cellular damage

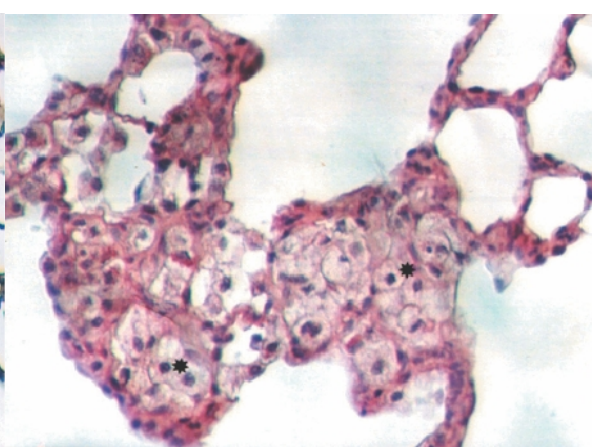
caused by formaldehyde was observed and structural appearance was similar to the control group.

**DISCUSSION**

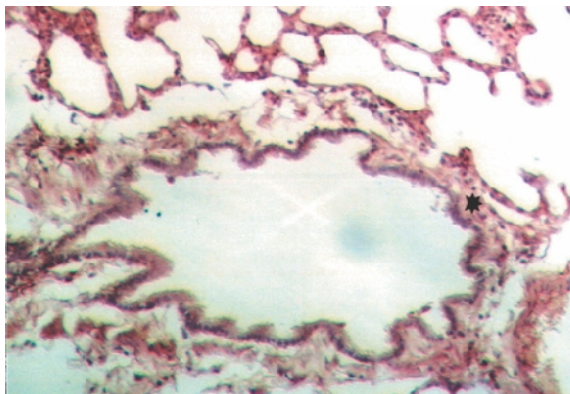
Formaldehyde inflicts various harms on many systems. Its negative effects on the respiratory system have been well documented in the epidemiological studies. (11, 12). Recently, there has been a trend for experimental studies about harmful effect of FA. FA is a potent respiratory irritant and is capable of stimulating a number of receptors related to the trigeminal nerve and localized in the nasal epithelium (13). While the mechanism by which formaldehyde exerts its cytotoxic



**Figure 7. Dilated and congested vessels (asterisk) was seen in alveolar septa in FA group. Masson's Trichrome X10**



**Figure 8. Foamy macrophage accumulation (asterisks) was observed in pulmoner interstitium in FA+CAPE group. Periodic Acid Schiff x20**



**Figure 9. Bronchiolar walls were seen as similar to control in FA+CAPE group. Periodic Acid Schiff x10**

effects is not known, formaldehyde reacts directly with tissue constituents, and cytotoxicity is presumably a function of this reactivity. (14). Lesions primarily develop in the epithelium lining the nasal septum and the ventral meatus of the turbinates. The types of lesions following an acute 24 h nasal instillation of 400 mM FA were squamous metaplasia, ulceration, hyperplasia, and goblet cell hypertrophy, which were observed at 3 weeks post treatment (15). These lesions occurred only in respiratory and transitional epithelium lining the anterior nasal passages of the rat nose. This suggests that respiratory and transitional epitheliums are more susceptible to FA damage than the other epithelial types present in the nose. It is well known that chronic formaldehyde exposure has an irritant effect on the respiratory tract and induces adverse alterations in respiratory-function parameters and cellular morphology. The reduced resistance to upper and lower respiratory tract infections of workers occupationally exposed to formaldehyde could suggest changes in the function of polymorphonuclear neutrophils, which are known to be the first line of defence against bacterial infections (16).

Reactive oxygen species (ROS) are formed continuously in cells as a consequence of external factors and they become harmful when they are produced in excess under abnormal conditions such as inflammation (17, 18). ROS may cause cell damage and are involved in the pathophysiology of inflammation, cancer and ethanol intoxication (19, 20, 21). CAPE was shown to possess significant anti-inflammatory

and antioxidant properties. It was reported that CAPE is a potent inhibitor of lipoxygenase, and through this activity, leukocyte chemotaxis and inflammatory activity are abolished (22, 23, 24, 25). Calikoglu et al. indicated that CAPE might be effective in protecting the injury of remote organs caused by oxidative stress and neutrophil accumulation (26). On the other hand, FA has oxidant effects. Zararsiz et al reported that formaldehyde decreases SOD activity and increases MDA levels in the lung which is indicative of oxidative damage. In other words, FA leads to oxidative damage in the lungs (27). We observed that FA caused histopathological changes in the lungs of the rats. Additionally, it plays oxidative role for respiratory structure including lungs. CAPE, however, decreased the histopathological changes and protects lungs from oxidative damage.

In conclusion, it was detected that FA-exposure leads to inflammation and injury in lungs. CAPE shows protective and anti-inflammatory activity against these harmful effects.

## REFERENCES

1. Pitten FA, Kramer A, Herrmann K, Bremer J, Koch S. Formaldehyde Neurotoxicity in animal experiments. *Pathol Res Pract* 2000;196:193-8
2. Nelson N, Levine RJ, Albert RE, et al. Contribution of formaldehyde to respiratory cancer. *Environ Health Perspect* 1986;70: 23-35
3. Çelik HH, Sargon MF, Çelik MH, Uslu SS, Çelik TH. A review of the health effects of formaldehyde toxicity. *Morphology J* 2001; 9;49-52
4. Hester SD, Benavides GB, Yoon L, et al. Formaldehyde-induced gene expression in F344 rat nasal respiratory epithelium. *Toxicology* 2003 187;13-24
5. Kerns WD, Pavkov KL, Donofrio DJ, Gralla EJ, Swenberg JA. Carcinogenicity of formaldehyde in rats and mice after long-term inhalation exposure. *Cancer Res* 1983 43;4382-92
6. Alexandersson R, Hedenstierna G, Kolmodin-Hedman B. Exposure to formaldehyde: effects on pulmonary function. *Arch Environ Health* 1982 37;279-84
7. Burdock GA. Review of the biological properties and toxicity of bee propolis (propolis). *Food Chem Toxicol* 1998 36;347-63
8. Ozyurt H, Irmak MK, Akyol O, Sogut S.

- Caffeic acid phenethyl ester changes the indices of oxidative stress in serum of rats with renal ischemia-reperfusion injury. *Cell Biochem Funct* 2001 19;259-63
9. Russo A, Longo R, Vanella A. Antioxidant activity of propolis: role of caffeic acid phenethyl ester and galangin. *Fitoterapia* 2002 73;21-9
  10. Ogeturk M, Kus I, Colakoglu N, Zararsiz I, Ilhan N, Sarsilmaz M. Caffeic acid phenethyl ester protects kidneys against carbon tetrachloride toxicity in rats. *J Ethnopharmacol* 2005 97;273-280
  11. Kilburn KH, Seidman BC, Warshaw R. Neurobehavioral and respiratory symptoms of formaldehyde and xylene exposure in histology technicians. *Arch Environ Health* 1985 40;229-33
  12. Kilburn KH, Warshaw R, Boylen CT et al. Pulmonary and neurobehavioral effects of formaldehyde exposure. *Arch Environ Health* 1985 40;254-60
  13. Casee FR, Arts JH, Groten JP, Feron VJ. Sensory irritation to mixtures of formaldehyde, acrolein, and acetaldehyde in rats. *Arch Toxicol* 1996 70;329-37
  14. Kimbell JS, Subramaniam RP, Gross EA, Schlosser PM, Morgan KT. Dosimetry modeling of inhaled formaldehyde: comparisons of local flux predictions in the rat, monkey, and human nasal passages. *Toxicol Sci* 2001 64;100-10
  15. St Clair MB, Gross EA, Morgan KT. Pathology and cell proliferation induced by intra-nasal instillation of aldehydes in the rat: comparison of glutaraldehyde and formaldehyde. *Toxicol Pathol.* 1990 18;353-61
  16. Lyapina M, Zhelezova G, Petrova E, Boey M. Flow cytometric determination of neutrophil respiratory burst activity in workers exposed to formaldehyde. *Int Arch Occup Environ Health* 2004 77;335-40
  17. Green HJ, Plyley MJ, Smith DM, Kile JG. Extreme endurance training and fiber type adaptation in rat diaphragm *J Appl Physiol* 1989 66;1914-20
  18. Gutteridge JM, Halliwell B. The measurement and mechanism of lipid peroxidation in biological systems. *Trends Biochem Sci* 1990 15;129-35
  19. Good PF, Werner P, Hsu A, Olanow CW, Perl DP. Evidence of neuronal oxidative damage in Alzheimer's disease. *Am J Pathol* 1996 149;21-8
  20. Gassen M, Youdim MB. The potential role of iron chelators in the treatment of Parkinson's disease and related neurological disorders. *Pharmacol Toxicol* 1997 80;159-66
  21. Halliwell B, Gutteridge JMC In: *Studies of generalized light emission (luminescence/fluorescence)* (3rd ed.) University Press, Oxford 1999: 387
  22. Mirzoeva OK, Calder PC. The effect of propolis and its components on eicosanoid production during the inflammatory response. *Prostaglandins Leukot Essent Fatty Acids* 1996 55;441-449
  23. Sud'ina GF, Mirzoeva OK, Puskareva MA, Korshunova GA, Sumbatyan NV, Varfolomeev SD. Caffeic acid phenethyl ester as a lipoxygenase inhibitor with antioxidant properties. *FEBS Lett* 1993 329;21-24
  24. Bhattacharjee P, Eakins KE. Lipoxygenase products: Mediation of inflammatory responses and inhibition of their formation. In: L.W. Chakrin and D.M. Bailey, Editors, *The leukotrienes*, Academic Press, Orlando, FL 1984:195-215
  25. Koksel O, Ozdulger A, Tamer L et al. Effects of caffeic acid phenethyl ester on lipopolysaccharide-induced lung injury in rats *Pulm Pharmacol Ther.* Published Online: 10 Jun 2005 DOI:10.1016/j.pupt.2005.03.006
  26. Calikoglu M, Tamer L, Sucu N et al. The effects of caffeic acid phenethyl ester on tissue damage in lung after hindlimb ischemia-reperfusion. *Pharmacol Res* 2003 48;397-403
  27. Zararsiz I, Sonmez MF, Yılmaz HR, Pekmez H, Kus I, Sarsilmaz M. The protective effects of omega-3 fatty acids against formaldehyde-induced oxidative damage to lung in rats. *Selcuk Medical Journal* 2004 20;93-98