

# MAGNETIC RESONANCE IMAGING DIAGNOSIS OF CARCINOID HEART DISEASE

Orkun Baloğlu<sup>1</sup>, Servet Tatlı<sup>2\*</sup>

Hacettepe University, School of Medicine<sup>1</sup>, Ankara, Turkey  
Brigham and Women's Hospital, Harvard Medical School, Department of Radiology<sup>2</sup>,  
Boston, USA

---

Carcinoid heart disease is a rare complication of metastatic carcinoid. We present a 46-year-old woman who had metastatic carcinoid and progressive right heart failure. Cardiac MR imaging was helpful in the detection of the extent of the cardiac disease.

**Key words:** MRI, carcinoid tumor, carcinoid heart disease

*Eur J Gen Med 2008; 5(1):54-56*

---

## INTRODUCTION

Carcinoid heart disease is an uncommon complication of the carcinoid syndrome that often leads to heart failure (1). Histologically, it is characterized by pathognomonic plaque-like intracardiac deposits of fibrous tissue with retraction and fixation of valvular cusps (2).

Echocardiography may be limited to demonstrate the extent of the cardiac involvement. MR imaging may be helpful for the demonstration of the extent of the disease in this is rare clinical condition. We describe the magnetic resonance (MR) imaging findings of heart involvement in a patient with metastatic carcinoid.

## CASE

A 46-year-old woman presented with bilateral progressive pedal edema, facial flushing episodes and severe diarrhea. Urine 5-hydroxyindoleacetic acid level was markedly elevated. Abdominal CT examination revealed innumerable liver metastases without a primary site. Liver biopsy was performed and pathologic evaluation revealed the diagnosis of carcinoid tumor. Her echocardiography showed thickened, retracted tricuspid valve with opposition of the leaflets and moderately enlarged right atrium and ventricle consistent with carcinoid disease of the heart. The left heart chambers were

unremarkable. The pulmonary valve could not be evaluated. Upon progression of her symptoms, obtained MR imaging to evaluate the extent of the disease demonstrated significantly enlarged right ventricle (Figure 1 A,B) and atrium with evidence of volume overload that manifested by presence of D-shaped left ventricle seen in diastole only (Figure 1B). On gradient echo cine images, the right ventricle function was preserved. The tricuspid valve appeared thickened and retracted with narrow apposition of the leaflets. There was severe retraction as well as severe tricuspid regurgitation (Figure 1A). In addition, the pulmonary valve was also involved with moderate severity of insufficiency (Figure 1 C, D). The aortic and mitral valves were structurally normal with traces of insufficiency. Left ventricle size and function was normal.

The patient underwent elective tricuspid and pulmonary valve replacement. Pathologic evaluation of the tricuspid and pulmonary valves revealed chorda tendineae with fibrous endocardial thickening with abundant smooth muscle cells, devoid of elastic fibers consistent with carcinoid plaque. The patient was discharged in a stable condition.

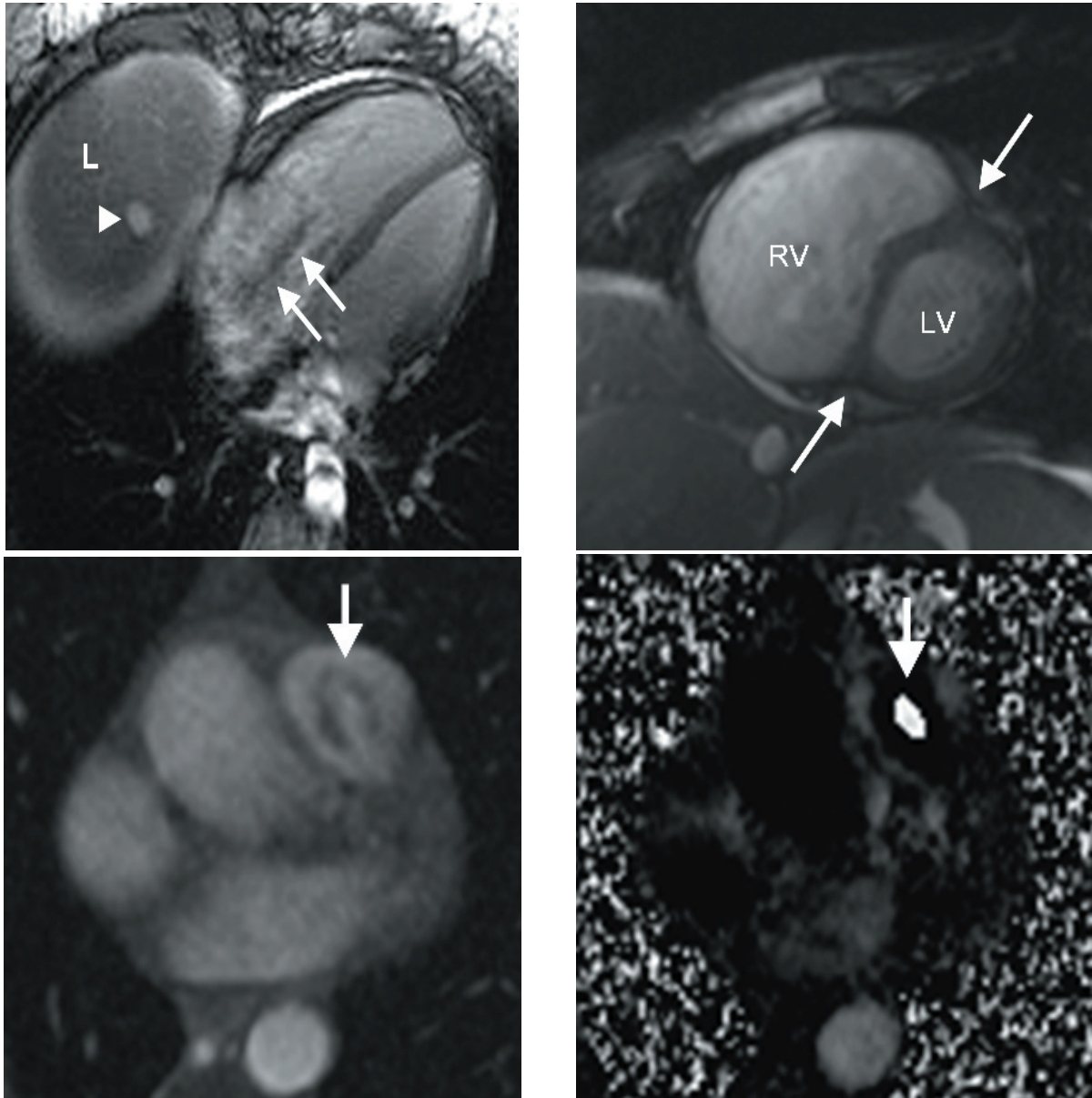
---

*Correspondence:* Servet Tatlı, MD

Assistant Professor of Radiology Department of Radiology, Brigham and Women's Hospital, 75 Francis St., Boston, MA 02115

Phone: 617-525-7916, Fax: 617-732-6304

E-mail: [statli@partners.org](mailto:statli@partners.org)



**Figure 1.** A. Cardiac-gated, breath hold, gradient-echo MR image in 4 chamber view shows marked enlargement of the right atrium and ventricle with an abnormal jet due to tricuspid regurgitation in systole (arrows). Note also the hyperintense metastatic nodule (arrow head) in the dome of the liver (L). B; Cardiac-gated, breath hold, gradient-echo MR image in short axis view shows enlargement of the right heart (RV) as well as flattening of the interventricular septum (arrows) causing a characteristic D-shaped left ventricle (LV) due to volume overload in diastolic phase. C; Phase-contrast MR angiography (magnitude image) obtained in a plane perpendicular to the pulmonary trunk shows a jet (arrow) in the pulmonary artery during systole consistent with pulmonary regurgitation. D; Phase-contrast MR angiography (phase image) corresponding to the image of Figure 1C shows a bright signal intensity (arrow) in the pulmonary artery during diastole consistent with aliasing artifact arising from a high velocity regurgitant flow. The encoded gradient was chosen as superior to inferior.

## DISCUSSION

Carcinoid heart disease is an uncommon complication of the carcinoid syndrome that often leads to heart failure (1). Histologically, it is characterized by pathognomonic plaque-like intracardiac deposits of fibrous tissue with retraction

and fixation of valvular cusps (2). It typically involves the valves and endocardium of the right side of the heart. Tricuspid regurgitation is found nearly in all patients but tricuspid stenosis and pulmonary regurgitation less commonly occur (2). Echocardiography is the most commonly

used diagnostic tool to identify carcinoid heart disease. Cardiac MR imaging adds valuable information when evaluating cardiac structures that might be difficult to analyze on echocardiography (3, 4).

MR imaging features of the carcinoid disease of the heart include dilatation of the right atrium and ventricle with flattening of the ventricular septum; thickening of tricuspid valve and its subvalvular apparatus with marked immobility throughout the cardiac cycle leading a fixed open position of the cusps during systole; and a severe tricuspid regurgitation (4). Although its spatial resolution is limited to demonstrate pathognomonic valvular deposits, MR imaging has the advantage that valvular dysfunction can be precisely quantified with phase contrast technique. MR imaging can also be useful in determining the involvement of pulmonary valve, which may sometimes be difficult to evaluate on echocardiography (5).

## REFERENCES

1. Botero M, Fuchs R, Paulus DA, Lind DS. Carcinoid heart disease: a case report and literature review. *J Clin Anesth* 2002;14:57-63
2. Connolly HM, Pellikka PA. Carcinoid heart disease. *Curr Cardiol Rep* 2006;8:96-101
3. Bastarrika G, Cao MG, Cano D, Barba J, de Buruaga JD. Magnetic resonance imaging diagnosis of carcinoid heart disease. *J Comput Assist Tomogr* 2005; 29:756-9
4. Mollet NR, Dymarkowski S, Bogaert J. MRI and CT revealing carcinoid heart disease. *Eur Radiol* 2003; 13(Suppl 6):L14-18
5. Didier D. Assessment of valve disease: qualitative and quantitative. *Magn Reson Imaging Clin N Am* 2003;11:115-34