

Colovaginal fistula secondary to diverticular disease in young age: a case report*

AKÇAKAYA A.¹, BABALIOĞLU R.², KARAKELLEOĞLU A.¹, İNTEPE A.¹, SIDAL B.²
Department of General Surgery¹ and Obstetrics and Gynecology²; Vakıf Gureba Teaching Hospital, İstanbul

Key words Colovaginal fistula, diverticular disease, young

*This paper was presented in XV. World Congress of Gynecology and Obstetrics of FIGO; 3-8 August 1997; Denmark

Accepted for publication: 2 December 1997

Introduction

Colovaginal fistula is a rare, but a distressing problem and a special time, skill and multidisciplinary approach requires for the treatment. The most common cause is colonic diverticular disease. Although it is uncommon in persons less than 40 years of age, the incidence of diverticular disease increases with advancing age, so that by the ninth decade it is present in at least two thirds of the population (1,2). The disorder is an increasingly common clinical problem in older age groups, especially in the industrialized countries. There is a higher incidence of diverticular disease in females than males. It is postulated that this may reflect some protective, possibly hormonal effect during the reproductive period that decreases in the postmenopausal period (2,3).

In this case report, it was aimed to present a patient with colovaginal fistula, interestingly in young- childbearing age and to discuss the diagnosis- and treatment problems.

Case report

S.T., 30-year-old woman, had a complaint of stool coming from vagina with mild abdominal discomfort. Approximately nine months ago, the patient had diarrhea and abdominal pain. Since her father had lung tuberculosis and received treatment, she was given antituberculous treatment for suspected intestinal tuberculosis. In the eighth month of treatment, the complaint of vaginal stool passage occurred. The patient who was mild cachectic, had two normal, spontan live births.

Vaginal examination revealed a 0.5 cm of diameter stool coming opening on posterior fornix. After a gauze was placed in the rectum, 10cc of methylene blue was injected from the opening. 20 minutes later, when the gauze removed from the rectum, methylene blue was seen on it. A fistulography was showed sigmoidovaginal fistula (Figure 1). In blood analysis, there were mild anemia and hypoproteinemia (Hb: 11.5 g/dl, Htc: 36%, protein 5.1 g/dl, ESR: 62mm/hr). Chest ray and intravenous pyelogram were normal. Microbiological

only there was a non-smooth appearance in terminal ileum, cecum and sigmoid colon. In the fistulography, opaque solutin passed to sigmoid then rectum (Figure 1).

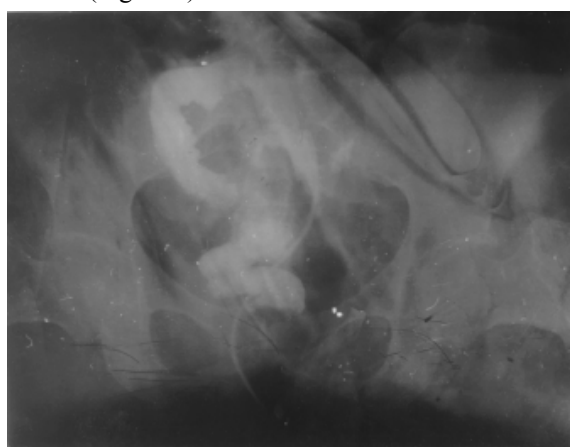


Figure 1. Fistulogram showing the fistulous tract between vagina and sigmoid colon

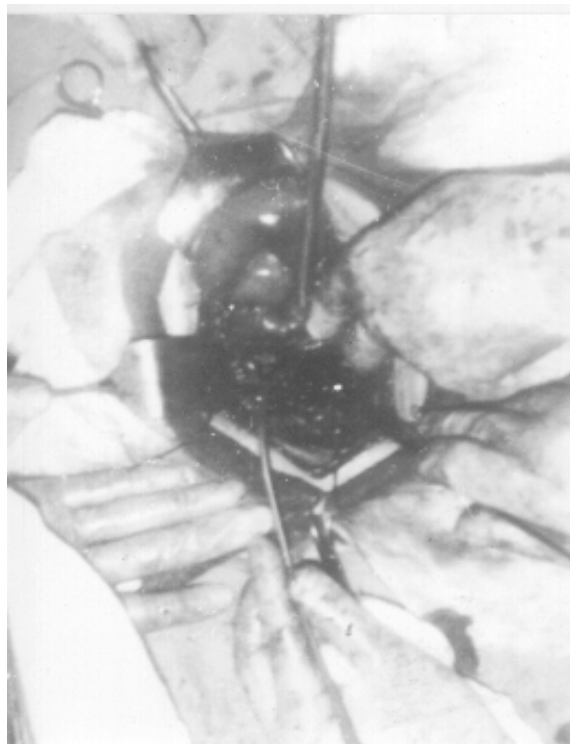

Figure 2. Photograph showing fistulous tract at operation

During the preoperative period, hypoalbuminemia and anemia were improved, and bowel preparation was performed. In operation, it was noticed that caecum and a part of ileum was adhered to the right site of uterine fundus forming a gateau. Sigmoid colon had also adhered to this conglomerate from the medial portion. After the gateau was released with careful dissection, the fistulous tract was appeared between vagina and sigmoid colon (Figure 2). Following hysterectomy, right oophorectomy, the resection of fistula tract, and closing of vaginal portion and a loop colostomy in descendent colon were performed. Because of ischemic appearance of the caecum, we also performed right hemicolectomy and end to end ileotransversostomy. In postoperative period, the patient received antibiotics and total parenteral nutrition for five days, and then oral feeding started. Histopathological diagnosis was sigmoid colon diverticulitis and salpingitis. PCR (Polimerase chain reaction) detection for tuberculosis was negative. Microbiological examination revealed no spesific infection. Three months later, the colostomy was closed. During the two year-follow up period, no recurrence and complaint occurred.

Discussion

Colovaginal fistula is rarely seen in gynecological practice. Diverticular disease is the most common cause of this fistula, followed by gynecological neoplasms. The other reasons are gastrointestinal malignancies, hysterectomy, irradiation, pelvic abscess and perforation by a foreign body. Most women with colovaginal fistulae had undergone previous hysterectomies. Some fistula cases secondary to Crohn disease and dermoid cyst have been reported (1-3).

Diverticular disease is a common disorder of the sigmoid colon and is an increasing common clinical problem in older age groups, especially in the industrialized countries (4,5). The mean age of onset is 58.

The onset of the fistula is usually a surprisingly mild clinical event and without prodrome. The passage of faeces and gas from the vagina is diagnostic for colovaginal fistula. This symptom varies in severity. While some patients complain nonspecific but persistent vaginal discharge, the others complain a grossly feculent one. If the patient has acute diverticulitis, then symptoms may include left lower quadrant pain, fever, leukocytosis, nausea, vomiting and abdominal distention. However, patients with colovaginal fistula secondary to diverticulitis often do not present symptoms of acute diverticulitis (1-7).

In our case, the patient was 30-year old woman, in other words rather young for this fistula. She had prodromal diverticulitis symptoms, but at admission to hospital, there were no acute inflammation signs. Because of her family history, she had antituberculous therapy, but except high ESR, no supporting findings could be found in the evaluation. At the beginning, in some cases this fistula could be attributed to abdominal tuberculosis.

Mostly the diagnosis of colovaginal fistula is a problem. The fistula can be visible in 40 - 50 % of the cases on vaginal examination. Sigmoidoscopy and barium enema are able to provide diagnosis in 20% and 50 % of cases, respectively. These two methods, should not be used in the acute stage of diverticular disease owing to the danger of perforation (1,2). Computed tomography has also limited value in the diagnosis. Perhaps the most efficient single test for colovaginal fistula is vaginogram using a Foley catheter with a 30 ml bulb inflated in the vagina and injection of water-soluble contrast medium, as originally described by Adachi and Gold (8). This method has provided the diagnosis in 90 % of the cases and has the advantage of simplicity and lack of complication. A colposcopic search of the vaginal mucosa, the cannulation of any ostia seen with a sialogram catheter and injection of water-soluble contrast medium pose some logistic barriers but have been advocated (2).

In our case, after the methylene blue dye injection, the time interval from the injection to the arrival to the gause, was supposed to be the fistulous connection between sigmoid colon and vagina. Only, after the cannulation and contrast medium injection, the right site of this connection was correctly determined by reuntgenogram. If the vaginal opening of the fistula can be seen, the latter method seems appropriate. Barium enema had no diagnostic value in our case either. Detection of colovaginal fistula with methylene blue dye injection seems simple, but its diagnostic value is limited.

Colovaginal fistulae do not close spontaneously or with medical therapy. Diverticular disease is the most common cause of pelvic colonic fistulas, and surgical therapy for these fistulas is essentially the same as for diverticulitis. One stage segmental resection of the involved colon with primary anastomosis seems to be the preferred surgical method. But in complicated cases, two and three stage operations including colonic resections and temporary colostomy may be performed. After the fistulous connection to the vagina is excised, the vagina is either left open or closed (1,2,4,9). In one report, attempt of transvaginal repair of

colovaginal fistula resulting from diverticular disease has failed (10).

Since our patient had symptoms of diverticulitis, and surgical findings showed an acute complicated situation, two stage operation was performed. Histerectomy was preferred since the patient had already two children.

Conclusion

Because a colovaginal fistula may be underdiagnosed and its prevalence may be expected to increase within older population, suspicion for the diagnosis and efforts to optimize the treatment of this lesion - especially if encountered in young age- seem necessary.

References

1. Grissom R, Synder TE: Colovaginal fistula secondary to diverticular disease. *Dis Colon Rectum*, 34(11):1043-1049,1991.
2. Cross SB, Copas PR: Colovaginal fistula secondary to diverticular disease. A report of two cases. *J Reprod Med*, 38 (11): 905-906, 1993.
3. Fleshner PR, Schoetz DJ, Roberts PL. et al: Anastomotic vaginal fistula after colorectal surgery. *Dis Colon Rectum*, 35 (10), 938-943, 1992.
4. Walton L, Schwartz M, Photopulos G, Fowler W: Sigmoidovaginal fistulae due to diverticular disease: two case reports and on up date. *Obstet Gynecol*, 1978, 51 (suppl): 59-61.
5. Painter NS, Burkitt DP: Diverticular disease of the colon: A deficiency disease of western civilization. *British Medical Journal*, 2: 450-454, 1971.
6. Colcock BP, Stahmann FD. Fistulas complicating diverticular disease of the sigmoid colon. *Ann Surg*, 175: 838-46, 1972.
7. Parks TG: Natural history of diverticular disease of the colon. A review of 521 cases. *British Medical Journal*, 4: 639-645, 1969.
8. Adachi A, Gold M: Vaginography for enterovaginal fistulae. *Am J Obstet Gynecol*, 131: 227-228, 1978.
9. Wychulis AR, Pratt JH: Sigmoidovaginal fistulas .A study of 37 cases. *Arch Surg*, 92: 520-524, 1965.
10. Livengood CH III.: Colovaginal fistula. Report of a case with failure of transvaginal repair. *J Reprod Med*, 41 (4): 291-293, 1996.

Correspondence to:

Dr. Rabiye Babaloğlu

Vakıf Gureba Eğitim Hastanesi

Kadın Hast. Doğum Kliniği

34290 Aksaray, Fatih, İstanbul