

# Incidence of agger nasi and frontal cells and their relation to frontal sinusitis in a Turkish population: a CT study

Adnan Özdemir<sup>1</sup>, Serdar Arslan<sup>2</sup>

<sup>1</sup>Department of Radiology, School of Medicine, Kırıkkale University, Kırıkkale, Turkey

<sup>2</sup>Department of Radiology, Konya Training and Research Hospital, University of Health Sciences, Konya, Turkey

## Abstract

**Objectives:** The aim of this study was to determine the incidence of agger nasi and frontal cells in a Turkish population and their relation to frontal sinusitis.

**Methods:** A total of 412 non-contrast paranasal sinus computed tomography (CT) images taken between March 2017 and June 2018 were examined retrospectively. Frontal cells were classified into four types according to Kuhn's classification. The relation of agger nasi and frontal cells to frontal sinusitis was evaluated.

**Results:** Of the 412 patients, 202 were males (mean age 34.8±14.9) and 210 were females (mean age 35.1±13.9). agger nasi cell was detected in 214 (51.9%), and frontal cell in 198 patients (48%). Frontal sinusitis was detected in 68 patients (16.5%). According to Kuhn's classification, Type 1 frontal cell was detected most frequently. A significant relationship was observed between the presence of agger nasi and frontal cells and frontal sinusitis ( $p<0.001$ ). When the right and left frontal sinusitis were evaluated separately, the relationship of frontal cell types of Kuhn's classification with frontal sinusitis was found to be significant on the right side, but not on the left side.

**Conclusion:** Agger nasi and frontal cells are common paranasal sinus variations that play a role in the development of frontal sinusitis. Although most of the paranasal sinus variations are considered as predisposing in the development of sinusitis, there are obvious differences in studies. For this reason, a higher number of comprehensive studies are necessary to reveal the relation between the presence of agger nasi and frontal cells and sinusitis.

**Keywords:** agger nasi cell; frontal cell; frontal sinusitis; Kuhn's classification

Anatomy 2018;12(2):71–75 ©2018 Turkish Society of Anatomy and Clinical Anatomy (TSACA)

## Introduction

There are a number of anatomical variations of paranasal sinuses. These anatomical variations may cause narrowing or obstruction in sinus drainage canals, leading to a reduction in the ventilation of sinuses and a deterioration mucociliary activity.<sup>[1]</sup> Particularly the inflammation of the cells around the sinus ostium leads to a narrowing in the sinus ostium, which disrupts the ventilation of sinuses and in turn leads to development of sinusitis.<sup>[2]</sup>

In the surgical treatment of paranasal sinus diseases, knowledge of the anatomy of paranasal sinuses and their variations yields better results in surgery and reduces complications.<sup>[3]</sup> Computed tomography (CT) is an imaging technique used as golden standard in the evaluation of the

patients preoperatively. Detailed anatomical information can be obtained preoperatively with CT and imaging findings are used as a surgical maps.<sup>[4]</sup>

In this study, we aimed to determine the incidence of agger nasi (AN) and frontal cells in a Turkish population and to reveal whether there is a relation with these and frontal sinusitis.

## Materials and Methods

This study was conducted in the Department of Radiology of Kırıkkale University, School of Medicine between January 2018 and June 2018. Ethics Committee approval was obtained from Kırıkkale University Ethics Committee. Paranasal sinus CT images obtained with

64-section multislice CT (Brilliance CT system; Philips Healthcare, Cleveland, USA) were evaluated retrospectively. The informed consent was waived due to the retrospective design of the study. The conformed with the principles outlined in the appropriate version of 1964 Declaration of Helsinki. The patients under the age of 18 and over the age of 75, and those with nasal polyposis, a history of operation on the sinonasal area, trauma history or a benign or malignant tumor were discluded from the study. CT images were obtained on coronal plane, with the patients lying prone (face down). Sagittal and axial images were reconstructed when necessary.

Radiologically, frontal sinusitis was defined as the thickening of sinus ostium or sinus walls at least for 3 mm in CT images. AN cell was accepted as the foremost anterior cell which was pneumatized in the frontal recess as described by Messerklinger.<sup>[5]</sup> Right and left recesses were evaluated separately. The frontal cells superior to the AN cell were divided into four groups in CT according to Kuhn's classification.<sup>[4]</sup> Based on this classification, Type 1 is a single cell located on AN cell; Type 2 is in the form of two or more cells on AN cell; Type 3 is a single large cell pneumatized into the frontal sinus; and Type 4 is in the form of a cell within the frontal sinus. The presence of frontal cells was evaluated separately on the left and right sides. All measurements were performed by a single researcher with seven years of experience in head and neck radiology.

Statistical analysis was performed using the Statistical Package for Social Sciences (SPSS for Windows, version

20.0, Chicago, IL, USA). Categorical variables were presented as frequencies and percentages, and data were expressed as mean±standard deviation. Groups were compared with Pearson's chi-squared test. To compare non-categorical changes, independent samples t-test was used. A p-value <0.05 was considered statistically significant.

## Results

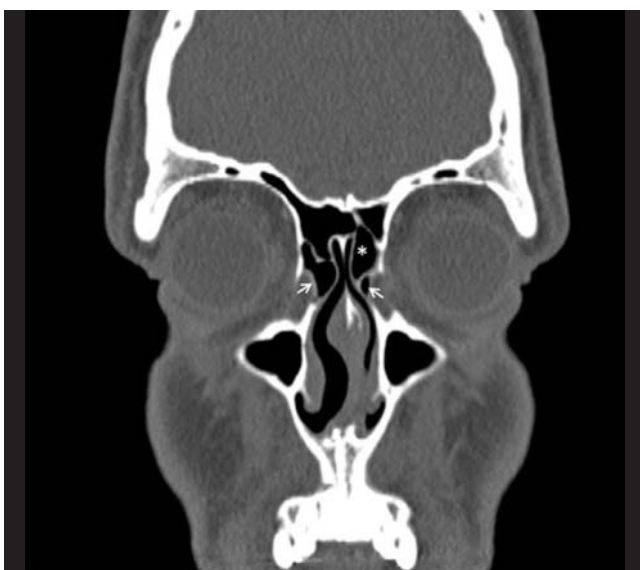
Of the 412 patients, 202 were males (mean age 34.8±14.9) and 210 were females (mean age 35.1±13.9). AN cell was detected in 214 patients (51.9%); 74 on the right side (17.9%), 36 on the left side (8.7%), and 104 bilateral (25.2%) (**Figure 1**).

Frontal cells were detected in 198 patients (48%); 54 (13.1%) of these were on the right side, 46 (11.1%) on the left side, and 98 (23.7%) bilateral. The most common frontal cell was Khun Type 1 and the least common Khun Type 4 (**Figure 2**). The incidence of frontal cells according to Kuhn's classification is shown in **Table 1**.

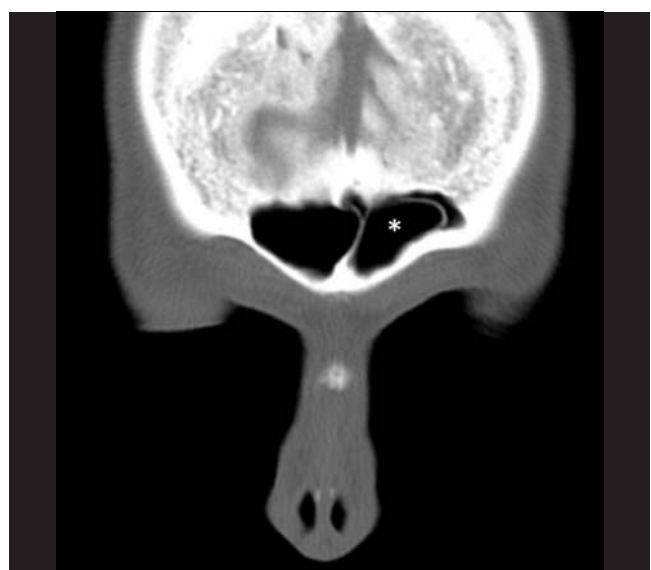**Table 1**

The incidence of frontal cells on the right and left sides according to Kuhn's classification.

Kuhn's classification	Right (%)	Left (%)
Type 1	78 (18.9%)	58 (14%)
Type 2	56 (13.5%)	50 (12.1%)
Type 3	12 (2.9%)	24 (5.8%)
Type 4	6 (1.4%)	14 (3.3%)



**Figure 1.** Coronal non-contrast paranasal sinus CT image shows bilateral agger nasi cells (white arrows) and frontal cell Type 1 on the left side (\*).



**Figure 2.** Coronal non-contrast paranasal sinus CT image shows a frontal cell Type 4 in the left frontal sinus (\*).

**Table 2**

The incidence of agger nasi cell and frontal cells and their relationship between frontal sinusitis.

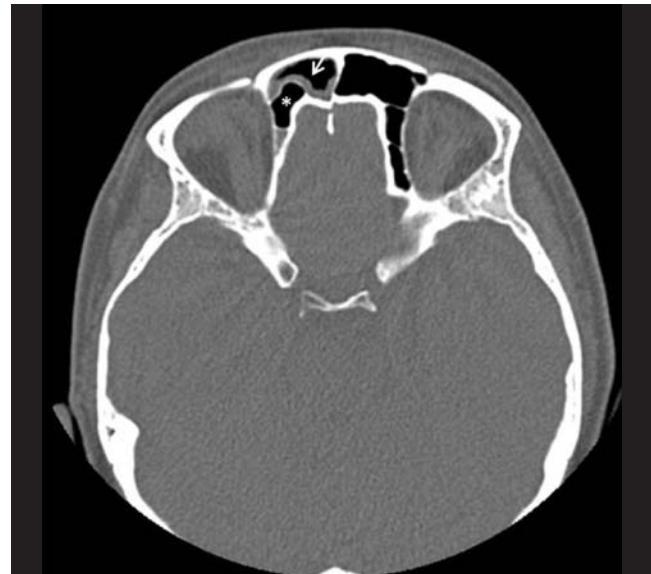		None (%)	Right (%)	Left (%)	Bilateral (%)	Total (%)	p
Agger nasi cell	None	96 (23.3%)	0 (0%)	0 (0%)	0 (0%)	96 (23.3%)	<0.001
	Right	58 (14%)	8 (1.9%)	2 (0.4%)	6 (1.4%)	74 (17.9%)	
	Left	30 (7.2%)	2 (0.4%)	4 (0.9%)	0 (0%)	36 (8.7%)	
	Bilateral	160 (38.8%)	10 (2.4%)	16 (3.8%)	20 (4.8%)	206 (50%)	
	Total	344 (83.4%)	20 (4.8%)	22 (5.3%)	26 (6.3%)	412 (100)	
Frontal cell	None	198 (48%)	4 (0.9%)	6 (1.4%)	6 (1.4%)	214 (53.1%)	<0.001
	Right	40 (9.7%)	8 (1.9%)	2 (0.4%)	4 (0.9%)	54 (13.1%)	
	Left	36 (8.7%)	2 (0.4%)	4 (0.9%)	4 (0.9%)	46 (11.1%)	
	Bilateral	70 (16.9%)	6 (1.4%)	10 (2.4%)	12 (2.9%)	98 (23.7%)	
	Total	214 (51.9%)	54 (13.1%)	46 (11.1%)	98 (23.7%)	412 (100%)	

Frontal sinusitis was detected in 68 patients; 20 (4.8%) of these were on the right side, 22 (5.3%) on the left side, and 26 (6.3%) were bilateral (Figure 3). A statistically significant relation was found between the presence of both AN and frontal cells and frontal sinusitis (p<0.001) (Table 2).

When right and left paranasal sinuses were evaluated separately, frontal cell types according to Kuhn's classification had a significant relationship with frontal sinusitis on the right side (p=0.002), whereas there was no significant relationship on the left side (p=0.942) (Table 3).

**Discussion**

Non-contrast paranasal sinus CT taken on a coronal plane is the most commonly preferred imaging technique in revealing the anatomy of paranasal sinuses in detail.<sup>[4]</sup> The variations of paranasal sinuses are often detect in routine paranasal CT examinations, and have been reported in different studies with wide ranges.<sup>[6,7]</sup> In this study, we



**Figure 3.** Axial non-contrast paranasal sinus CT image shows a frontal cell Type 3 in the right side (\*) and right frontal sinusitis (white arrow).

**Table 3**

The relation between frontal cell types and frontal sinusitis.

Frontal cell types			Absent (%)	Present (%)	Total	P
Right frontal sinusitis	Right	Type 1	30 (7.2%)	9 (2.1%)	39 (9.4%)	0.002
		Type 2	26 (6.3%)	2 (0.4%)	28 (6.7%)	
		Type 3	5 (1.2%)	1 (0.2%)	6 (1.4%)	
		Type 4	0 (0%)	3 (0.7%)	3 (0.7%)	
		Total	61 (14.8%)	15 (3.6%)	76 (18.4%)	
Left frontal sinusitis	Left	Type 1	23 (5.5%)	6 (1.4%)	29 (7%)	0.942
		Type 2	20 (4.8%)	5 (1.2%)	25 (6%)	
		Type 3	10 (2.4%)	2 (0.4%)	12 (2.9%)	
		Type 4	5 (1.2%)	2 (0.4%)	7 (1.6%)	
		Total	58 (14%)	15 (3.6%)	73 (17.7%)	

aimed to identify whether there was a relations between the presence of AN and frontal cells and frontal sinusitis. AN incidence was reported at different rates in different studies. Kayalioglu et al.<sup>[6]</sup> reported AN incidence as 7.77%. In contrast, in another study, Bradley and Kountakis<sup>[7]</sup> reported this incidence very high, 93%. The possible reason for this wide range of results in these studies is the difference in the definition of AN cell. In this study, the incidence of AN cell was 51.9%, and bilateral AN cell 25.2%.

Similarly, differences exist in earlier studies regarding the incidence of frontal cells; Gümüş et al.<sup>[8]</sup> reported as 15.2%, Küçükgünay et al.<sup>[9]</sup> 20.9%, and Eweiss et al.<sup>[10]</sup> 78.5%. In this study, the incidence of frontal cells was 48%, and bilateral frontal cells 23.7%. The most common frontal cell was Khun Type 1 and the least common Khun type 4.

Sinusitis is defined as the infection or inflammation of the paranasal sinuses. Its pathology can be explained with deterioration in the ventilation of sinus through the sinus ostium. The factors that affect the size of the sinus ostium play a role in the development of sinusitis.<sup>[11]</sup> This clinical situation can be seen in all sinuses. Among these factors, frontal sinusitis comes to the fore due to its anatomical position and intracranial complication risks.<sup>[11]</sup>

There are also differences in literature regarding the relationship between AN cell and frontal sinusitis. Eweiss et al.,<sup>[10]</sup> Kubota et al.,<sup>[12]</sup> and Del Gaudio et al.<sup>[13]</sup> found no relation between AN cell and frontal sinusitis, whereas Yegin et al.<sup>[14]</sup> reported the presence of sinusitis as significantly higher on the side of the AN cell. We also found a statistically significant relationship between frontal sinusitis and AN cell ( $p < 0.001$ ).

Del Gaudio et al.<sup>[13]</sup> reported no relationship between frontal cells and frontal sinusitis. In contrast, Meyer et al.<sup>[4]</sup> reported a significant relationship between Type 3 and Type 4 frontal cells and frontal sinusitis. Küçükgünay et al.<sup>[9]</sup> noted that Type 3 frontal cells had a relationship with sinusitis, but other types were not related. Gümüş et al.<sup>[8]</sup> detected a significant relationship between the presence of frontal cells and ipsilateral frontal sinusitis. In this study, when the right and left sides were evaluated separately, the relationship with frontal sinusitis was found to be significant on the right, but not on the left side.

The improvements in endoscopic sinus surgery have rendered the detailed anatomy of paranasal sinuses and their variations more important. Knowledge of variations is essential in order to avoid the complications

which could arise during the operation and to apply surgical procedures in a safe way.<sup>[15]</sup> Therefore, the evaluation of paranasal sinus anatomy and its variations preoperatively is crucial in eliminating complications.<sup>[15]</sup> CT is the best imaging method for the evaluation of inflammatory paranasal sinus pathologies and the osteomeatal complex. Contrary to the axial plane, coronal CT evaluation is considered to be a more efficient imaging method for endoscopic approaches.<sup>[3,4]</sup>

## Conclusion

The presence of AN and frontal cells plays a role in the development of frontal sinusitis. Although it is accepted that most of the paranasal sinus variations may be predisposing in the development of sinusitis, there are obvious differences between studies. For this reason, a higher number of comprehensive studies are required to reveal the relation between the presence of AN and frontal cells and sinusitis.

## References

1. Llyod GA, Lund VJ, Scadding GK. CT of paranasal sinuses and functional endoscopic surgery: a critical analysis of 100 symptomatic patients. *J Laryngol Otol* 1991;105:181–5.
2. Lee WT, Kuhn FA, Citardi MJ. 3D computed tomographic analysis of frontal recess anatomy in patients without frontal sinusitis. *Otolaryngol Head Neck Surg* 2004;131:164–73.
3. Bradley DT, Kountakis SE. The role of agger nasi air cells in patients requiring revision endoscopic frontal sinus surgery. *Otolaryngol Head Neck Surg* 2004;131:525–7.
4. Meyer TK, Kocak M, Smith MM, Smith TL. Coronal computed tomography analysis of frontal cells. *Am J Rhinol* 2003;17:163–8.
5. Messerlinger W. *Endoscopy of the nose*. Baltimore: Urban and Schwarzenberg, 1978.
6. Kayalioglu G, Oyar O, Govsa F. Nasal cavity and paranasal sinus bony variations: a computed tomographic study. *Rhinology* 2000;38:108–13.
7. Zhang L, Han D, Ge W, Xian J, Zhou B, Fan E, Liu Z, He F. Anatomical and computed tomographic analysis of the interaction between the uncinate process and the agger nasi cell. *Acta Otolaryngol* 2006;126:845–52.
8. Gümüş C, Yıldırım A, Erdiç P, Öztoprak B, Karaman B. Presence of frontal cell in frontal sinusitis and its association with anatomic variations. [Article in Turkish] *Cumhuriyet Üniversitesi Tıp Fakültesi Dergisi* 2005;27: 69–73.
9. Küçükgünay B, Eskiizmir G, Ünlü HH, Aslan A, Bayındır P, Ovalı GY, Özyurt. The radiological evaluation of anatomical variations of frontal recess in normal population and cases with frontal rhinosinusitis. [Article in Turkish] *Journal of Medical Updates* 2012; 2:47–52.
10. Eweiss AZ, Khalil HS. The prevalence of frontal cells and their relation to frontal sinusitis: a radiological study of the frontal recess area. *ISRN Otolaryngol* 2013;2013:687582.

11. Azila A, Irfan M, Rohaizan Y, Shamim AK. The prevalence of anatomical variations in osteomeatal unit in patients with chronic rhinosinusitis. *Med J Malaysia* 2011;66:191-4.
12. Kubota K, Takeno S, Hirakawa K. Frontal recess anatomy in Japanese subjects and its effect on the development of frontal sinusitis: computed tomography analysis. *J Otolaryngol Head Neck Surg* 2015;44:21.
13. DelGaudio JM, Hudgins PA, Venkatraman G, Beningfield A. Multiplanar computed tomographic analysis of frontal recess cells: effect on frontal isthmus size and frontal sinusitis. *Arch Otolaryngol Head Neck Surg* 2005;131:230-5.
14. Yegin Y, Çelik M, Şimşek BM, Olgun B, Canpolat S, Kayhan FT. Relationship between the presence of agger nasi cells and the development of frontal sinusitis: a computer-assisted anatomic study. *Bezmialem Science* 2017;5:112-5.
15. Bayonne E, Kania R, Tran P, Huy B, Herman P. Intracranial complications of rhinosinusitis. A review, typical imaging data and algorithm of management. *Rhinology* 2009;47:59-65.

Online available at:  
www.anatomy.org.tr  
doi:10.2399/ana.18.050  
QR code:



deomed®

**Correspondence to:** Serdar Arslan, MD  
Department of Radiology, Konya Training and Research Hospital,  
University of Health Sciences, Konya, Turkey  
Phone: +90 332 221 00 00  
e-mail: arslanserdar10@gmail.com

*Conflict of interest statement:* No conflicts declared.

This is an open access article distributed under the terms of the Creative Commons Attribution-NonCommercial-NoDerivs 3.0 Unported (CC BY-NC-ND3.0) Licence (<http://creativecommons.org/licenses/by-nc-nd/3.0/>) which permits unrestricted noncommercial use, distribution, and reproduction in any medium, provided the original work is properly cited. *Please cite this article as:* Özdemir A, Arslan S. Incidence of agger nasi and frontal cells and their relation to frontal sinusitis in a Turkish population: a CT study. *Anatomy* 2018;12(2):71-75.