

# Traumatic bronchial rupture

YALÇINKAYA İ.<sup>1</sup>, BİLİCİLER U.<sup>2</sup>

Department of Thoracic Surgery<sup>1</sup>, School of Medicine, Yüzüncü Yıl University, Van  
Van Military Hospital<sup>2</sup>, Van

**Key words:** Bronchial rupture, trauma

## Introduction

Tracheobronchial ruptures are most frequently caused by forceful trauma like motor vehicle accidents. They are rather uncommon and probably have a high prehospital mortality. It appears to occur in approximately 1% to 2% of individuals sustaining blunt injury(1). Symptoms of bronchial rupture include dyspnea, subcutaneous emphysema, and pneumothorax. Associated injuries are very frequent in these patients.

A case of the right main bronchus rupture caused by blunt chest trauma was treated by immediate thoracotomy and repair at the Department of Thoracic Surgery of School of Medicine Yüzüncü Yıl University. Because of the type of the injury and rarity of the case, we would like to present the case by summarizing the relevant literature.

## Case report

A 22-year-old boy was transferred from the Military Hospital to our department because of clinical suspicion of a bronchial rupture after blunt chest trauma. He had been in a traffic accident as a truck driver. On admission he was anxious, and a thoracic catheter was in place. A roentgenogram of the chest obtained in the referring hospital showed a complete pneumothorax on the right side(Fig. 1, 2). He had left clavicle and multiple rib fractures.

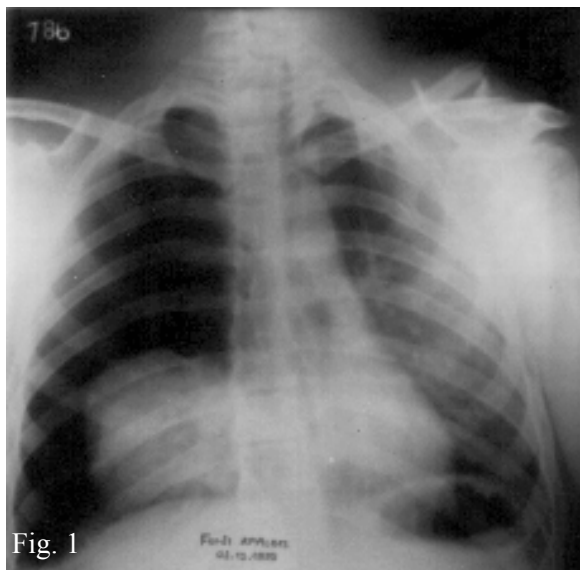


Fig. 1

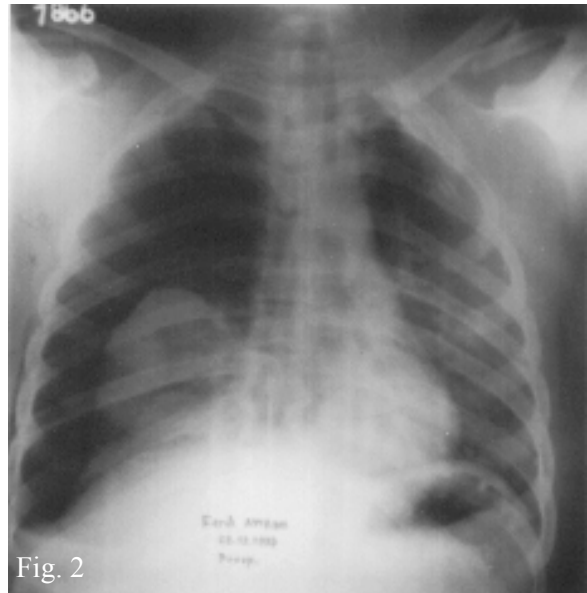


Fig. 2

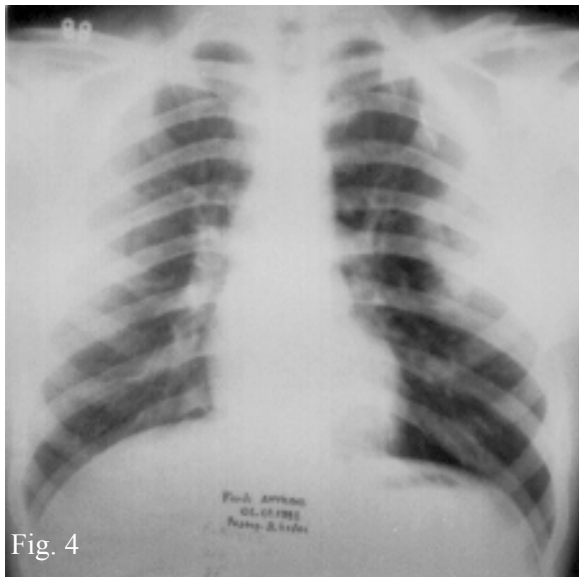
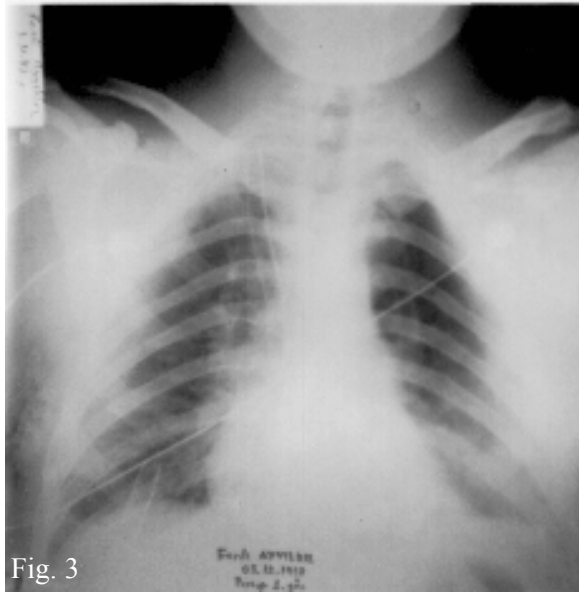
A major air leak was detected. The patient was then taken immediately to the operating room for urgent thoracotomy. A rigid bronchoscope, performed in the operating room while preparations for thoracotomy are being made, revealed a large defect of the right main bronchus just distal to the carina. After placement of a double-lumen endotracheal tube, the patient was positioned on his left side and a right posterolateral thoracotomy above the fifth rib was performed. The right lung was collapsed. A complete transection of the right main bronchus was present. The membranous portion of the main bronchus was transected transversely about 0.5 cm distal to the carina. The transection planes were connected by a single longitudinal tear at the membranous part of the right main bronchus.

The rupture was primarily repaired, and interrupted resorbable Vicryl (polyglactin 910) 3-0 sutures were used. After the repair, the sutures were covered with parietal pleura. A roentgenogram of the chest showed good expansion of the right lung (Fig. 3). The thoracic drain was removed after 5 days.

A follow-up bronchoscopic study after two days showed good patency of the main bronchus. Minimal granulation tissue was observed on the anastomosis line by bronchoscopic examination just before discharging. Chest roentgenogram was normal after 5 weeks (Fig. 4). But the control bronchoscopy revealed obliteration with granulation tissue in almost complete in upper lobe, close to complete and 2/3 of the main bronchus. The patient was referred to

Accepted for publication: 21 July 1998

another center for endoscopic therapy. Laser coagulation was applied, and airway was opened.



## Discussion

Bronchial rupture due to the blunt thoracic trauma is rarely seen. Difficulties of the diagnosis may cause delay in the treatment.

The constellation of persistent pneumothorax, massive air leak, and atelectatic lung in the presence of a well placed, functional thoracostomy tube constitutes the “fallen lung” sign and is a chest roentgenogram finding of high specificity for intrathoracic airway rupture (1). A pneumothorax is frequently present but may be absent if the mediastinal pleura remains intact. For the diagnosis, bronchoscopy is the first method of choice (2). It is reported that three-dimensional helical computed tomography might be used in the diagnosis (3).

Most intrathoracic airway ruptures caused by blunt trauma are situated at the distal trachea or the main bronchi within 2.5 cm of the carina (4). Tracheobronchial ruptures are three types: transverse, longitudinal, and complex. Complex injuries being either combined transverse, categorized into and longitudinal or multiple ruptures.

Immediate primary repair of the bronchial rupture is advocated to preserve functional lung tissue and to provide the best long-term results. Even in complete ruptures, reanastomosis chance must be tried, even if the rupture is old (5,6). A successful bronchial anastomosis 15 years after the trauma is reported in the literature (7). Repair suture material preferably is coated Vicryl, size 3-0 or 4-0. However, monofilament PDS, Prolene, and stainless steel wire have also been satisfactorily used (8).

Anesthetic management of the ruptured airway can be difficult and hazardous. Care should be taken to prevent further disruption of the airway during endotracheal intubation. The tube should be passed into the main bronchus of the unaffected lung in the case of bronchial rupture, or the double-lumen endotracheal tube should be placed.

The prognosis of tracheobronchial ruptures is often related to the severity of associated injuries in these multiple injured patients. Over the long term, bronchial stenosis by granulation tissue after primary repair of a bronchial rupture is to be feared. Regular bronchoscopic checks should be performed. Stenosis can be managed either with endoscopic therapy (electrocautery, laser coagulation, cryotherapy, dilatation and both silastic and metal stent placement) or, if endoscopic treatment is unsuccessful, by reoperation (sleeve or standart resection)(9). In early postoperative period (2-5 weeks) excess granulation formation developed at anastomosis line in our case. We considered that this complication might be due to the surgical technique or to the type of the rupture (there was longitudinal tear in membranous part with transvers cut) or to an unknown. We did not encounter such a complication in early period in the reports related to traumatic bronchial ruptures. In our case, laser coagulation was successfully performed.

In conclusion, in a patient with a complex bronchial rupture, primary repair of the bronchus can be possible with complete functional preservation of the lung tissue.

## References

1. Lee RB. Traumatic injury of the cervicothoracic trachea and major bronchi. *Chest Surg Clin North Am* 7(2):285-304, 1997
2. Elbeyli L, Erkol H, Yıldız H, Şanlı M. Travmatik bronş rüptürü. *Ulusal Travma Dergisi* 2(1):107-9, 1996
3. Oto Ö, Açıkkel Ü, Tüzün E, ve ark. Genç bir olguda bronş rüptürü onarımı ve tanısal tetkiklerde yeni ufuklar. *GKD Cer Dergisi* 5:292-5, 1997

4. Özçelik C, İnci I, Kandemir N, Eren N, Özgen G. Trakeobronşial yaralanmalarda tedavi. GKD Cer Derg 3(1):106-10, 1995
5. Yavuzer Ş, Akay H, Akalın H, ve ark. Trakeobronkial yaralanmalar. Mavi Bülten 10:211-5, 1978
6. Demircan S, Kuzucu A, Taştepe I, ve ark. Künt toraks travmasına sekonder bronş rüptürü(Olgu sunumu). Solunum Hastalıkları 8(1):71-5, 1997
7. Ökten İ. Bronş rüptürleri. Ankara Tıp Bülteni 4:323-6, 1982
8. Hood MR. İnjury to the trachea and major bronchi. Thoracic Trauma. Hood RM, Boyd AD, Culliford AT. WB. Saunders Company, Philadelphia, 1989, pp.264
9. Maiwand MO, Zehr KJ, Dyke CM, Tadjkarimi S, Khagani A, Yacoub MH. The role of cryotherapy for airway complications after lung and heart-lung transplantation. Eur J Cardio-thorac Surg 12(4):549-54, 1997

**Correspondence to:**

Yrd. Doç. Dr. İrfan Yalçınkaya

Yüzüncü Yıl Üniversitesi Tıp Fakültesi

Göğüs Cerrahisi ABD, Van, TÜRKİYE