

Pituitary apoplexy as a cause of coma: a case report

GÜVEN M.B.¹, ÇIRAK B.¹, YÜCEER N.²

Department of Neurosurgery¹, School of Medicine, Yüzüncü Yıl University, Van

Department of Neurosurgery², School of Medicine, Dokuz Eylül University, İzmir

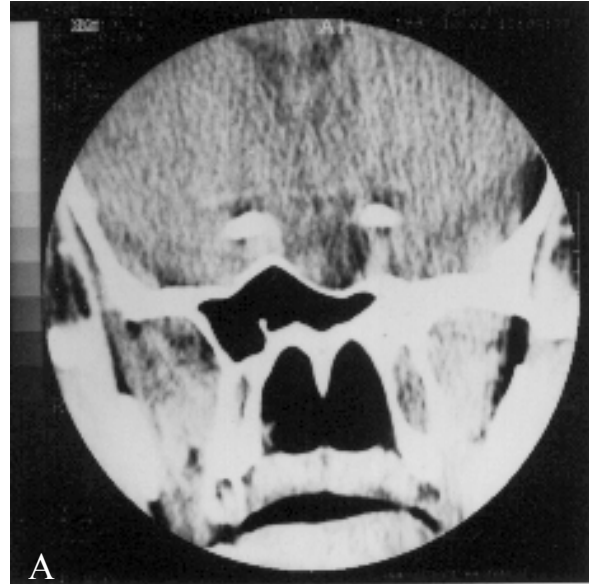
Key words: Pituitary apoplexy, coma

Introduction

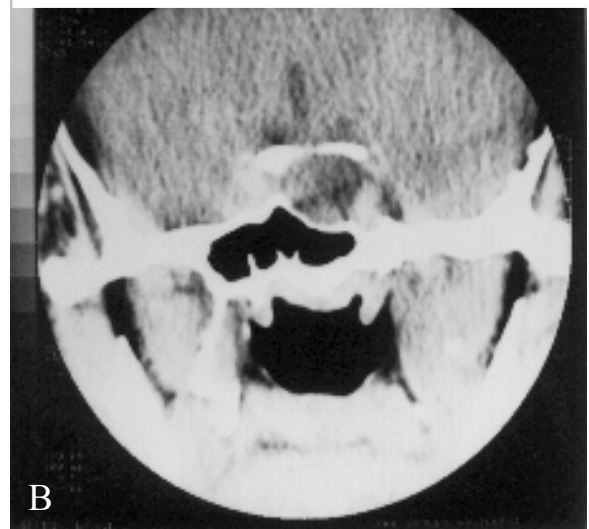
Pituitary apoplexy is an acute hemorrhagic or ischemic infarction in pituitary adenomas. Clinical diagnosis can often be difficult as the patient is frequently unaware of an existing adenoma. Therefore, the classic features of the syndrome must be known. They include sudden headache, impairment of consciousness, endocrinological disturbances and sudden visual deterioration or oculomotor palsies (1). We present a case of pituitary apoplexy caused impairment of consciousness, and its surgical treatment.

Case report

A 23 year - old male patient was admitted to our Emergency Clinic, with the complaint of impaired consciousness. It was learned that he had had headache for 1 week , and been prescribed some analgesic medicine in another medical center. The day before he applied to our clinic he had suddenly lost his consciousness. On his neurological examination he was unconscious, his eyes were spontaneously closed, there were no response to verbal stimuli, but he was localising the painful stimuli. His pupils were miotic and light reflexes were rather decreased; other findings were in normal limits. He underwent a cranial computerized tomography (CT). There was an intrasellar mass lesion causing bony destruction (picture 1, A and B).



Accepted for publication: 30 July 1998



Picture 1. Coronal CT sections A, and B, demonstrating the intra and suprasellar lesion.

He was thought as the pituitary adenoma and apoplexy. He was operated on in emergency conditions. Through a frontotemporal craniotomy, lesion was resected. In the mass lesion there were hemorrhagic areas, which confirmed the diagnosis of apoplexy. Postoperative period was uneventful, his postoperative cortisol and thyroid hormone levels were found to be lower than normal, he was prescribed oral steroid and thyroid hormone. He was discharged with normal neurologic findings.

Discussion

Pituitary adenomas are frequently encountered benign intracranial tumors. Clinically classified according to their capacity to produce and secrete hormones, they are diagnosed from the clinical manifestations and biochemical findings of pituitary hormones. Additionally, the tumor may result in neurologic findings due to mass effect. Pituitary adenomas may present acutely with pituitary apoplexy after intrapituitary hemorrhage or infarction (2). This rare complication occurs in about 2 to 10% of operated adenomas. Acute form results from massive intrapituitary bleeding leading to violent headache, meningeal signs, impaired consciousness and ophthalmological signs including bilateral blindness. Associated signs including paralysis of oculomotor nerves, epileptic seizures, hemiplegia are frequent. Diabetes insipidus is exceptional. In less acute forms, the sudden nature of the headache and ophthalmological signs can suggest the diagnosis. On x-ray film there may be sella destruction. CT or magnetic resonance imaging (MRI) shows either hematoma or a cystic cavity in pituitary gland. MRI which describes the size, suprasellar extension, compression of adjacent structures, ischemic areas and the age of the hemorrhage is essential. Emergent surgery is mandatory according to all authors. Transcranial route may be preferred for suprasellar extension having tumors. Transsfenoidal decompression can also be used for intrasellar lesions (3). Almost most of pituitary apoplexy occur spontaneously, some precipitating factors have been reported. Some occur after pituitary function tests (4), cardiac surgery (5), delivery (5), thrombolytic therapy (7), and some medications (8). Our patient is a case of apoplexy occurring spontaneously, and it

caused impaired consciousness. In the case of conscious impairment we must consider the possibility of pituitary apoplexy, since it is a curable condition. Emergent surgery is of vital importance for these cases. As in our case early surgical intervention helps the consciousness to improve.

References

1. Milazzo S, Toussaint P, Proust F, Touzet G, Malthieu D: Ophthalmologic aspects of pituitary apoplexy. *Eur J Ophthalmol* 6(1): 69-73,1996
2. Hennessey JV, Jackson IM: Clinical features and differential diagnosis of pituitary tumors with emphasis on acromegaly *Baillieres Clin Endocrinol Metab* 9(2): 271-314,1995
3. Berthelot JL, Rey A: Pituitary apoplexy. *Presse Med* 24(10): 501-503,1995
4. Masago A, Ueda Y, Kanai H, Nagai H, Umemura S: Pituitary apoplexy after pituitary function test: a report of two cases and review of the literature. *Surg Neurol* 43(2):158-164,1995
5. Pliam MB, Cohen M, Cheng L, Spaenle M, Bronstein MH, Atkin TW: Pituitary adenomas complicating cardiac surgery: summary and review of 11 cases. *J Card Surg* 10(2):125-132,1995
6. Lavalley G, Morcos R, Palardy J, Aube M, Gilbert D: MR of nonhemorrhagic postpartum pituitary apoplexy. *AJNR Am J Neuroradiol* 16(9): 1939-1941,1995
7. Fuchs S, Beeri R, Hasin Y, Weiss AT, Gotsman MS, Zahger D: Pituitary apoplexy as a first manifestation of pituitary adenomas following intensive thrombolytic and antithrombotic therapy. *Am J Cardiol* 81(1): 110-111,1998
8. Faustini-Fustini M: Pituitary apoplexy after leuprolide administration for carcinoma of the prostate: What's new? *Clin Endocrinol (Oxf)* 46(3):378,1997

Correspondence to:

Dr. Bayram Çırak

Yüzüncü Yıl Üniversitesi Tıp Fakültesi

Nöroşirürji ABD, Van, TÜRKİYE