

Is there an association of giardiasis with beta-thalassemia minor?

Javed Yakoob^{a,*}, Wasim Jafri^a, Hizbullah Shaikh^b

^a Department of Medicine, The Aga Khan University Hospital, Karachi, Pakistan

^b Institute of Liver Studies, King's College Hospital, London, United Kingdom

Abstract. Beta-thalassemia minor is a symptomless carrier state of a hemoglobinopathy which predisposes to bacterial infections. We report three cases presenting with giardiasis, a parasitic infection of gastrointestinal tract caused by *Giardia lamblia*. Patients presented with recurrent diarrhea and abdominal pain for over a year. An esophagogastroduodenoscopy finding varied from normal to acute duodenitis. Duodenal biopsy demonstrated changes consistent with mild chronic non-specific inflammation with *G. lamblia* trophozoites. All three patients were diagnosed as β -thalassemia minor hemoglobin electrophoresis. They were treated with Diloxanide furoate 500 mg and Metronidazole 400mg three times daily for five days. Their symptoms resolved and a stool test repeated one week after the end of treatment was normal. The host immune system both humoral and cellular components have a role in protection and clearance of Giardiasis. However, β -thalassemia minor patients have an observed probability of giardiasis but not a confirmed incidence.

Key words: β -Thalassemia-trait, diarrhea, abdominal pain, giardiasis, CD2

1. Introduction

Beta -thalassemia (β -thalassemia) is one of the most common hematological disorders in Pakistan. The carrier frequency is estimated to be 5.4% (1). The β -thalassemia contains a heterogeneous group of disorders with a wide spectrum of clinical manifestations, ranging from being asymptomatic to life-threatening hemolysis. Patients with β -thalassemia major are known to have dysfunctions of the cardiopulmonary, renal, reticuloendothelial and other systems due to deposit of iron. However, β -thalassemia minor (b-Tm) is the symptomless carrier state. A greater predisposition of b-Tm carriers to gastrointestinal and hepatobiliary diseases has also been reported (2-5). *Giardia lamblia* is the most common protozoan isolated from the gastrointestinal tract and is a major cause of parasite-induced diarrhea in humans (6).

Giardiasis is widespread primarily in developing countries. Infection with *G. lamblia* includes asymptomatic cyst passage, acute usually self-limited diarrhea and a chronic syndrome of diarrhea, malabsorption and weight loss. Predisposition to giardiasis has been documented in patients with common variable immunodeficiency, X-linked agammaglobulinemia, reduced gastric acidity, chronic pancreatitis and protein energy malnutrition (7). We report 3 cases of b-Tm who presented with diarrhea and abdominal pain and following investigations were diagnosed as having giardiasis. Evaluation of these cases provides insight into mechanisms of immunosuppression associated with b-Tm.

2. Case reports

Case report 1

In September, 2007 a 14 years old male presented with recurrent diarrhea with abdominal pain intermittent for 2 years. Milestones were normal for age. Father was a known case of β -thalassemia minor. There was a history of receiving treatment with metronidazole for giardiasis and amebiasis in the past. Physical examination was normal. Spleen was not palpable on abdominal examination. However, an ultrasound of abdomen was not carried out. Upper gastrointestinal endoscopy was normal.

* Correspondence: Dr Javed Yakoob MBBS, PhD.
Department of Medicine, The Aga Khan University Hospital, Stadium Road, Karachi-74800, Pakistan
Tel: +92 21 4930051 ext-4679
E-mail: yakoobjaved@hotmail.com

However, duodenal biopsy demonstrated mild chronic non-specific inflammation with *G. lamblia* trophozoites (Fig 1). A complete blood count revealed hemoglobin of 12 gm/dl, hematocrit 34%, MCV 60.2%, red cell count $6.20 \times 10^{12}/L$ and platelet count of 135×10^9 per liter. Hemoglobin electrophoresis showed HBA 95.1% (normal range 98-100) and HbA2 4.9% (normal range 1.5-3.5). There were no biochemical abnormalities. Serum immunoglobulin determination revealed no evidence of IgA deficiency. Stool microscopy and culture was negative for *G. lamblia* and other parasites cyst or ova and bacterial pathogens.

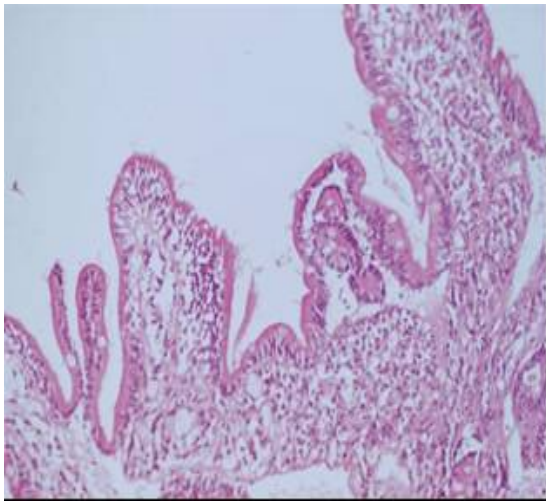


Fig. 1. High-power view of duodenal biopsy showing mild chronic inflammation, villous widening, and several *Giardia lamblia* trophozoites adjacent to villi (arrows).

Case report 2

In December, 2007 a 14 year-old female presented with abdominal pain and diarrhea intermittent for one year. There was no family history of β -thalassemia. Physical examination was normal. Spleen was not palpable on abdominal examination. However, an ultrasound of abdomen was not carried out. Upper gastrointestinal endoscopy demonstrated duodenitis in second part. Duodenal biopsy demonstrated mild chronic non-specific inflammation with *G. lamblia* trophozoites. A complete blood count revealed hemoglobin of 12.2 gm/dl, hematocrit of 35.3%, MCV 60.4%, red cell count $6.10 \times 10^{12}/L$ and platelet count of 135.8×10^9 per liter. Hemoglobin electrophoresis showed HBA 94% and HbA2 6%. There were no biochemical abnormalities. Serum immunoglobulin determination for evidence of IgA deficiency was negative. Stool microscopy and culture was negative for *G.*

lamblia and other parasites cyst or ova and bacterial pathogens.

Case report 3

In January, 2008 a 15 year-old female presented with loose stool for one year. She was a known case of b-Tm. Physical examination was normal. Spleen was not palpable on abdominal examination. However, an ultrasound of abdomen was not carried out. Upper gastrointestinal endoscopy was normal with duodenal biopsy demonstrating mild chronic non-specific inflammation with *G. lamblia* trophozoites. A complete blood count revealed hemoglobin of 10.8 gm/dl, hematocrit of 34.2%, MCV 60.9%, red cell count $6.15 \times 10^{12}/L$ and platelets count of 138.6×10^9 per liter. Hemoglobin electrophoresis showed HBA 94.5% and HbA2 4.5%. There were no biochemical abnormalities. Serum immunoglobulin determination for evidence of IgA deficiency was negative. Stool microscopy and culture was negative for *G. lamblia* and other parasites cyst or ova and bacterial pathogens.

3. Discussion

The incidence of giardiasis in our general population was described as 12% (8). However, it has been shown to be more in children 1 to 5 years old in squatter settlements in the city (9). This analysis demonstrated b-Tm patients have an observed probability of giardiasis. This is the first report describing giardiasis with b-Tm. Medline literature search did not identify previous report of such a condition. Intestinal parasitic infections are common worldwide particularly in developing countries and are associated with considerable morbidity. In Pakistan about 5 % of the individuals with a hypochromic and microcytic blood picture have the b-Tm (10). In heterozygote beta-thalassemic subjects there is a high incidence of infectious diseases and of liver diseases with progression toward chronic hepatitis. This predisposition has been suggested as being related to some immunological defects and to an altered immunological reactivity in thalassemia trait carriers.

In a previous study, humoral and cellular parameters in healthy heterozygote beta-thalassemic subjects and normal subjects showed that there was no difference in the number and percentage of total lymphocytes, gamma globulins, immunoglobulin G and M (IgG/M), number and percentage of cluster of differentiation (CD21), CD3, CD4, CD8, CD4/CD8 ratio and lymphocytes' ability to respond to phytohemagglutinin (11). The values of immunoglobulins G were found to be higher only in

heterozygote beta thalassemic subjects however, the number of CD2 in these subjects was lower (11).

The human CD2 is a cell adhesion molecule expressed on T cells and is recognized as a target for CD58 (humans) (12). It is expressed on all T cells, thymocytes and natural killer cells. CD2 binds to the CD58, a cell surface glycoprotein, and promotes the initial stages of T cell contact with antigen presenting cells (APCs) or target cells (12). CD2 binding is independent of TCR triggering. The coligation of CD2 and CD58 leads to immune recognition processes. In the presence of the human CD2/CD58 interaction, T cells recognize the relevant major histocompatibility (MHC) complexes on APCs with a 50- to 100-fold greater efficiency than in cell conjugates that lack the counter receptor interaction (13). Human CD2 signaling serves to optimize T cell activation, enhances IL-12 responsiveness, and reverse T cell anergy (14). In a case report, prolonged disturbance of CD2 expression led to an acquired cellular immunodeficiency with the development of opportunistic systemic *Rhodococcus* infection (15). This underlines the importance of CD2 in vivo, where it may play a role in the fine regulation of T-cell proliferation. It might be that CD2 signaling that enhances IL-12 responsiveness is deficient in these patients with beta thalassemia trait. Also, the cytokine, interleukin (IL) 12 is known to stimulate T cell and natural killer cell production of interferon (IFN) III and inhibits T cell production of IL-4. The effects of IL-12 on cytokine gene expression, IgE, mucosal mast cell, and eosinophil responses were studied in the course of infection in mice inoculated with the nematode parasite *Nippostrongylus brasiliensis*. The study concluded that Th2-associated responses protected against, and/or Th1-associated responses exacerbate, nematode infections (15).

Iron and its binding proteins have immunoregulatory properties and therefore iron excess may tip the immune balance unfavorably to allow increased growth rates of infectious organisms (16). In a study of serum ferritin levels in carriers of β -thalassemias trait, they were found to be above the normal limits in 13 % cases (17). The host immune system both humoral and cellular components plays an important role in protection from giardiasis, in clearance of the parasite and in certain instances in production of disease. *G. lamblia* interfere with the functions of the

enterocytes but do not damage them physically although minor damage to the cell membrane can sometimes be seen (17) Further damage may result from a cell-mediated immune response. The parasite is dealt with by a cell-mediated immune response of T-cell lymphocytes, which may emigrate to the lumen of the bowel. Mast cell mediated reactions contribute to the inflammation and edema seen in the mucosa and lamina propria. In β -thalassemia there is substantial evidence that a defect in innate effector functions of phagocytes (neutrophils, monocytes / macrophages) plays an important role in the weakened resistance to pathogenic bacteria and is at least in part due to iron overload. Moreover, reduced chemotaxis by these phagocytes has been repeatedly demonstrated. Antibody alone, or with complement can damage some extracellular parasites, but it is more effective acting in combination with certain effector cells by opsonizing for phagocytosis or by promoting antibody dependent cell mediated cytotoxicity (ADCC).

In conclusion, on the basis of this case series it is not possible to conclude that there is an association b-Tm with giardiasis. Only a study with larger number of appropriately selected patients will answer the questions raised here.

References

1. Khan SN, Riazuddin S. Molecular characterization of β -thalassemia in Pakistan. Hemoglobin 1998; 22: 333-345.
2. Gallerani M, Pulga A, Bottini E, et al. Heterozygous beta thalassemia and gastrointestinal pathology. Minerva Med 1986; 77: 709-712.
3. Gibertini P, Rocchi E, Cassanelli M, Pietrangelo A, Ventura E. Porphyria cutanea tarda in beta-thalassemia trait carriers. Dermatologica 1984;169: 131-134.
4. Fargion S, Cappellini MD, Sampietro M, Fiorelli G. Non-specific iron in patients with beta-thalassaemia trait and chronic active hepatitis. Scand J Haematol 1981; 26: 161-167.
5. Friedman S, Ozsoylu S, Luddy R, Schwartz E. Heterozygous beta thalassaemia of unusual severity. Br J Haematol 1976; 32: 65-77.
6. Palm JE, Weiland ME, Griffiths WJ, Ljungström I, Svärd SG. Identification of immunoreactive proteins during acute human giardiasis. J Infect Dis 2003 15; 187: 1849-1859.
7. Zafar MN, Baqai R, Lodi TZ, et al. *Giardia lamblia* in patients undergoing upper G.I. endoscopy. J Pak Med Assoc 1991; 41: 74-75.
8. Baqai R, Zuberi SJ, Qureshi H, Ahmed W, Hafiz S. Efficacy of albendazole in giardiasis. East Mediterr Health J 2001; 7: 787-790.
9. Mehraj V, Hatcher J, Akhtar S, Rafique G, Beg MA. Prevalence and factors associated with intestinal parasitic infection among children in an urban slum of Karachi. PLoS One 2008; 3: e3680.

10. Qureshi TZ, Anwar M, Ahmed S, Ahmed Khan D, Saleem M. Serum ferritin levels in carriers of beta-thalassaemia trait. *Acta Haematol* 1995; 94: 7-9.
11. Gallerani M, Cicognani I, Ricci A, et al. Immunological pattern in heterozygote beta-thalassemic subjects. *Riv Eur Sci Med Farmacol* 1990; 12: 191-195.
12. Springer TA. Adhesion receptors of the immune system. *Nature* 1990; 46: 425.
13. Gollob JA, Li J, Kawasaki H, et al. Molecular interaction between CD58 and CD2 counter-receptors mediates the ability of monocytes to augment T cell activation by IL-12. *J Immunol* 1996; 157: 1886-1893.
14. Boussiotis VA, Freeman GJ, Griffin JD, et al. CD2 is involved in maintenance and reversal of human alloantigen-specific clonal anergy. *J Exp Med* 1994; 180: 1665-1673.
15. Kittner JM, Jacobs R, Buyny S, et al. Adult onset of T-cell deficiency with impaired CD2 expression complicated by *Rhodococcus* infection: a case report. *Ann of Allergy Asthma and Immunol* 2007; 98: 294-298.
16. Finkelman FD, Madden KB, Cheever AW, et al. Effects of interleukin 12 on immune responses and host protection in mice infected with intestinal nematode parasites. *J Exp Med* 1994; 179: 1563-1572.
17. Walker EM, Walker SM. Effects of iron overload on the immune system. *Ann Clin Lab Sci* 2000; 30: 354-365.