

## Landau-kleffner syndrome-A rare experience

Ramnath Santosh Ramanathan\*, Tina Ahluwalia, Ankush Sharma

*Department of Neurology, Max Superspecialty Hospital, Saket, New Delhi-110017, India*

**Abstract.** Landau Kleffner syndrome (LKS)/Acquired epileptic aphasia (AEA) typically develops in healthy children who acutely or progressively lose receptive and expressive language ability coincident with the appearance of paroxysmal EEG changes. In most cases described in detail, a clearly normal period of motor and language development occurs before LKS symptoms appear. The same was the case with our patient also. LKS should be differentiated from autism with minimal language regression, especially when it is associated with isolated EEG abnormalities. Currently LKS is considered as part of the syndrome of electrical status epilepticus of sleep (ESES) by many, which is also known as continuous spike and wave of slow-wave sleep (CSWS). We also have increasing evidence that the language disorder is directly caused by epileptic discharges in critical language areas which must be viewed as a special kind of epileptic aphasia. We present a case of 5-year-old child admitted with sudden loss of speech along with seizures in the form of staring look and classical EEG abnormalities of Landau Kleffner syndrome. We started our patients on high dose oral steroids following failure of intravenous immunoglobulin trial. There are small numbers of publications reviewing Landau-Kleffner syndrome in the literature hence making it one of those rarer entities.

**Key words:** Landau Kleffner Syndrome, Acquired epileptic aphasia, seizures, Continuous spike and wave of slow wave sleep, Electrical status epilepticus of sleep.

### 1. Introduction

In 1957, Landau and Kleffner initially described AEA and later on hesitantly agreed to the attachment of their names to the syndrome. The onset of aphasia is between 18 months and 13 years, but generally is seen after 4 years and before 7 years. There is frequent association of a language disorder with epilepsy in children, but there is usually no causal relationship (1). Whether seizures and epileptiform discharges cause language dysfunction in LKS is disputed. Most cases of LKS are spontaneous, though familial clustering has been reported. As only about 200 cases have been described in global literature and only about 100 cases are documented every 10 years this entity becomes one of those rarer diseases.

The initial manifestation of the language problem is often word deafness or auditory verbal agnosia. Though in many patients, auditory verbal agnosia may include lack of recognition of familiar noises, alert responses to sound and tonal audiograms are usually normal. Speech production is also affected as badly as or even worse than language comprehension. Reading and writing may be preserved in children with little speech or auditory comprehension. There may be number of Speech disturbances which include fluent aphasia, use of jargon and paraphrase, asyntaxia, and verbal stereotypies in children who are not completely mute. There is gradual language deterioration over weeks or months. Continuous spike and wave during sleep seems to precede language deterioration as also improvement in the paroxysmal EEG pattern during sleep often precedes the clinical language improvement. The prevalence of clinical seizures in LKS is 70-85%. Seizures usually appear between 4 and 10 years of age. Remission of the seizures before adulthood (often before age 15 y) is the rule which has shown in many series. Behavior patterns are thought to be secondary to the language impairment, but some patients may

\*Correspondence: Dr. Ramnath Santosh Ramanathan  
4750, Centre Avenue, Apt No. 52  
Pittsburgh-15213 Pennsylvania,  
USA Phone-001-412-799-4663  
E-mail: dr.santosh7@gmail.com

Received: 11.11.2010

Accepted: 10.05.2011

have complex, hard-to-explain and bizarre behaviors.

Most cases of LKS do not have a well-defined cause. Secondary LKS may be associated with low-grade brain tumors, closed-head injury, neurocysticercosis, demyelinating disease and CNS vasculitis. MRI should hence be done in patients with suspected LKS to rule out secondary causes though MRIs in patients with LKS are grossly normal. Positron emission tomography reveals decreased metabolism in 1 or both temporal lobes. Hypometabolism is especially prominent in the middle temporal gyrus though hypermetabolism can also be seen in patients with LKS. Single-photon emission CT (SPECT) of the brain demonstrates decreased perfusion of the left temporal lobe in patients with LKS. EEG in the awake state shows some epileptiform abnormalities. The discharges are either focal or bilateral with temporal or parietal predominance. Sleep may promote the appearance of generalized paroxysmal abnormalities. Drowsiness or early sleep increases the frequency and generalization of the discharges. Generalized spike-and-wave discharges initially have frequencies around 3-4 Hz, but during the course of the disease they may be slower, in the 1.5- to 3-Hz range. LKS is generally considered as a variant of the continuous spike-and-wave during slow sleep (CSWS). EEG sleep stages in LKS show activation and generalization of discharges.

There isn't any standard treatment of LKS as many therapeutic modalities have been tried with variable success. Among these are anticonvulsant drugs, corticosteroids, ACTH, immunoglobulins, ketogenic diet, and surgery. Early corticosteroid or ACTH therapy can improve symptoms of LKS normalize the EEG. Prolonged steroid therapy with ACTH 80 IU/d (range 0.2-1 U/kg/d from other sources) has been recommended. Prednisone 60 mg/d followed by a 3-mo taper is commonly used. Pulse intravenous methylprednisolone therapy has been used to induce remission in LKS. A dose of 20-30 mg/kg/d for 3-5 d has been used, intervals followed by prednisone 2 mg/kg, which is then tapered after 1-2 months. A few case reports have demonstrated that intravenous gammaglobulin may be useful in LKS, but it requires repeated doses (2). Multiple subpial transections (MST) have been used with variable success in LKS.

## 2. Case report

5 years old child was admitted for evaluation of sudden loss of Speech and abnormal behavior. The child was perfectly well until 3 months back

when the mother noticed that she was not responding to her. Later she noticed that she was talking nonsense and she responded verbally in strange way. When asked about something she would answer by talking about something different not related to question asked. The condition was progressively worsening and the child finally lost speech. Currently she can speak few scattered words but is not able to form sentences. She also stopped expressing her needs and feelings verbally and whenever she wanted something she just pointed to it. She recognized her family members but could not call them by names. Mother gave history of brief episodes of staring. There was no history of frank abnormal movements, headache or vomiting, loss of consciousness, urine or fecal incontinence. The girl was able to dress herself and take food by herself. Family history revealed that parents were not related and our patient had 2 other younger siblings. There was no family history of similar problem. Her birth history was normal and there was no history of developmental delay. There was no social problem. An ENT(Ear Nose Throat-Otorhinology) specialist and speech therapist also evaluated the child but examination was normal and no intervention was suggested from their side.

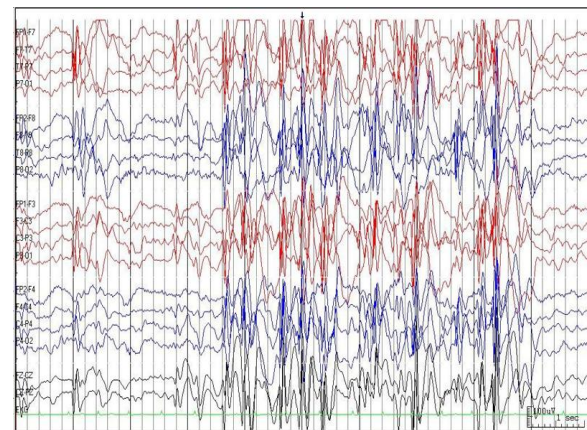


Fig 1. A long-term video EEG revealed abnormal frequent generalized spike and wave discharges in >85% of epoch during sleep and less in awake stage consistent with LKS/CSWS

The general physical and neurological examination was normal. She was aggressive and in addition, almost uncooperative to allow detailed neurological examination. Testing higher functions was difficult. Psychiatry and ENT examination was unremarkable. A long-term video EEG (figure 1-5) revealed abnormal frequent generalized spike and wave discharges in >85% of epoch during sleep and < 20% in

awake stage consistent with LKS/CSWS. MRI brain was normal. ANA and Anti ds-DNA Antibody were negative. Lactate Plasma, Neonatal Metabolic Screen, Blood spot (Tandem mass spectrometry) - all were normal. Liver Function Test and full Blood Count were normal. A diagnosis of Landau-Kleffner syndrome was made and she was put on sodium valproate for the control of seizures. She was given trial of monthly IV immunoglobulins treatment but she did not respond to it and hence she was put on oral steroids in the dose of 2mg/kg body weight along with aggressive speech and language therapy. Further plan is long-term follow up of our patient to look for the response of the multidisciplinary treatment including oral steroids in our patient.

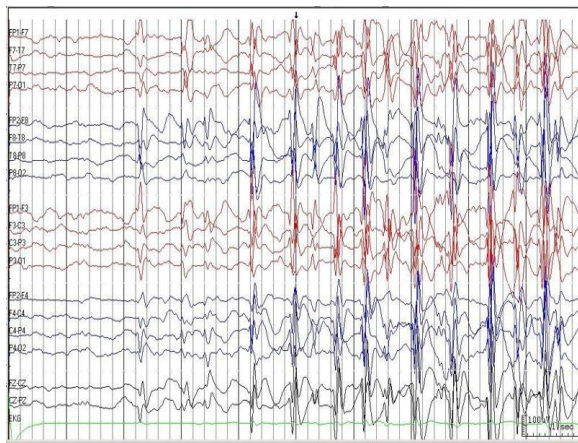


Fig. 2. A long-term video EEG revealed abnormal frequent generalized spike and wave discharges in >85% of epoch during sleep and less in awake stage consistent with LKS/CSWS

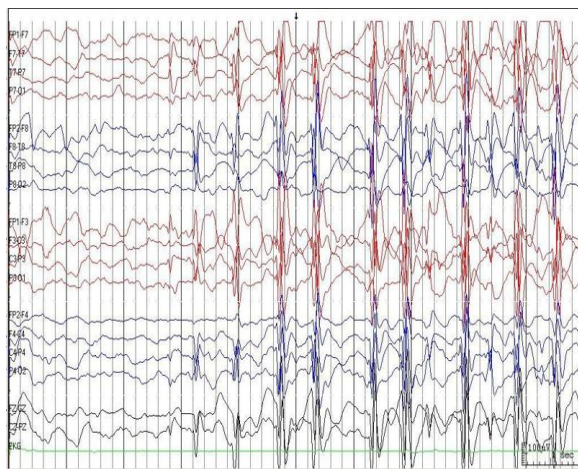


Fig. 3. A long-term video EEG revealed abnormal frequent generalized spike and wave discharges in >85% of epoch during sleep and less in awake stage consistent with LKS/CSWS

### 3. Discussion

The characteristic for LKS and childhood disintegrative disorder is combination of aphasia and epileptic seizures. Young children with previously normal psychomotor development are affected, causing profound regression with loss of receptive and expressive language capabilities. The etiology of these childhood epilepsy-aphasia syndromes are obscure, and even the long-term prognosis is poor (3).

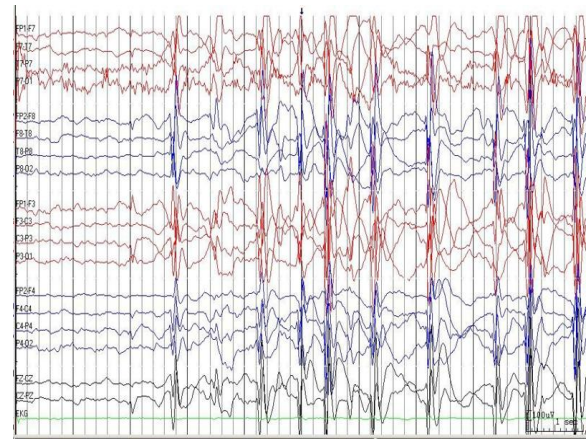


Fig. 4. A long-term video EEG revealed abnormal frequent generalized spike and wave discharges in >85% of epoch during sleep and less in awake stage consistent with LKS/CSWS

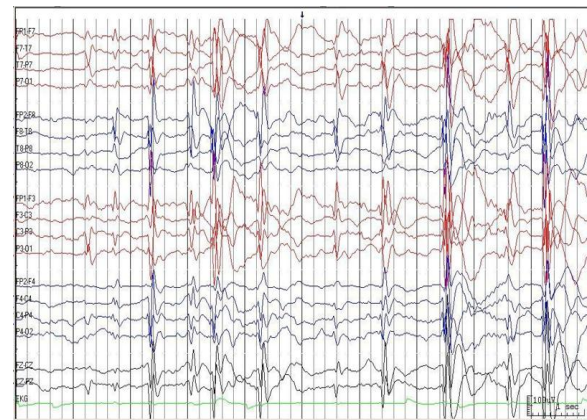


Fig. 5. A long-term video EEG revealed abnormal frequent generalized spike and wave discharges in >85% of epoch during sleep and less in awake stage consistent with LKS/CSWS

There is a large spectrum of interactions between language and epilepsy as indicated by the occurrence of sleep EEG abnormalities in some children with specific language impairment (SLI), the various forms of language dysfunction patterns seen in children with benign childhood

epilepsy with Centrotemporal spikes (BECTS), and finally the acquired aphasia in LKS (4).

There exists good evidence for a relationship between LKS/AEA and electrical status epilepticus during sleep (ESES), which reflects the course of the aphasia (5). ESES describes an EEG pattern showing significant activation of epileptiform discharges in sleep. The terms continuous spike wave in slow-wave sleep (CSWS) and LKS describe the clinical epileptic syndromes seen with ESES. Even though there is an overlap between these 2 syndromes, children with CSWS present with a more global regression, have more problematic epilepsy and have EEG foci located predominantly in frontotemporal or frontocentral regions. As with our patient, children with LKS present with an acquired auditory agnosia, fewer seizures, and EEG foci in the posterotemporal regions (6). Although epilepsy resolves with time in most cases, many children are left with significant cognitive or language impairment. One of the major predictor of poor outcome is longer duration of ESES. LKS or CSWS syndrome cause cognitive decline and syndromes like West, Lennox-Gastaut or Dravet's induce both psychomotor regression and intractability. In such cases, early aggressive treatment is indicated (7). Our patient was treated with high dose prednisolone 2mg/kg/day, as well as with aggressive speech and language therapy. The importance of multidisciplinary approach alongwith high dose steroids was also stressed by Gallagher S et al (8). ACTH is an effective treatment for LKS. Relapses often occur if it is given only for short period and hence to avoid relapses adjustment of long term low dose maintenance therapy is advisable (9).

Though our patient did not respond to iv immunoglobulins, in the study reporting the use of IVIG in the treatment of LKS and CSWS the

temporal relation between IVIG treatment and clinical improvement could not be denied in individual patients but its real value remains to be determined.

#### 4. Conclusion

Children with LKS may commonly present to an audiology or ENT clinic. Thus, though rare early recognition of LKS is important to initiate supportive, speech and educational care.

#### References

1. Deonna TW. Acquired epileptiform aphasia in children (Landau-Kleffner syndrome). *J Clin Neurophysiol* 1991; 8: 288-298.
2. Arts WF, Aarsen FK, Scheltens-de Boer M, Catsman-Berrevoets CE. Landau-Kleffner syndrome and CSWS syndrome: treatment with intravenous immunoglobulins. *Epilepsia* 2009; 50: 55-58.
3. Steinlein OK. Epilepsy-aphasia syndromes. *Expert Rev Neurother.* 2009; 9: 825-833.
4. Billard C, Fluss J, Pinton F. Specific language impairment versus Landau-Kleffner syndrome. *Epilepsia* 2009; 50: 21-24.
5. Bourgeois BF. Clinical aspects of epilepsy including diagnosis, management, pharmacotherapy, and surgery. *Curr Opin Neurol Neurosurg* 1993; 6: 233-239.
6. Nickels K, Wirrell E. Electrical status epilepticus in sleep. *Semin Pediatr Neurol* 2008; 15: 50-60.
7. Arts WF, Geerts AT. When to start drug treatment for childhood epilepsy: the clinical-epidemiological evidence. *Eur J Paediatr Neurol* 2009; 13: 93-101.
8. Gallagher S, Weiss S, Oram Cardy J, et al. Efficacy of very high dose steroid treatment in a case of Landau-Kleffner syndrome. *Dev Med Child Neurol* 2006; 48: 766-769.
9. Szabó L, Nagy J, Kálmánchey R. Adrenocorticotrophic hormone therapy in acquired childhood epileptic aphasia. *Ideggyogy Sz* 2008; 61: 409-416.