

## Case Report

# Double superior vena cava (persistent left superior vena cava draining into the coronary sinus) - case report

Mustafa Yurtdaş<sup>\*</sup>, Musa Şahin

Department of Cardiology, Medisina Hospital, Van, Turkey.

**Abstract.** A 24-year-old woman with no relevant cardiac history presented for evaluation of palpitation and chest pain. Electrocardiography showed non-specific ST-T wave changes in inferior leads. Transthoracic echocardiography showed a dilated coronary sinus. The thoracic computed tomography (CT) scan with contrast showed the normal right superior vena cava and the persistent left superior vena cava (PLSVC) draining into the right atrium through the coronary sinus. Transthoracic echocardiography - including agitated saline infusion to both antecubital veins - and computed tomography are important non-invasive diagnostic tools for accurate diagnosis of this rare congenital venous malformation. This malformation is quite frequently found, especially with the advent of cardiac ultrasound or CT, magnetic resonance imaging (MRI).

Key words: Persistent left superior vena cava, coronary sinus, retrograde cardioplegia, resynchronization therapy, echocardiography, computed tomography

## 1. Introduction

Double superior vena cava with the PLSVC is a rare venous malformation. Nearly 10% of the patients with PLSVC have other cardiac malformations such as atrial septal defect, ventricular septal defect or endocardial cushion defect. A PLSVC may give rise to some problems during the invasive procedure such as pacemaker implantation, central venous catheterisation, retrograde delivery of cardioplegia and retrograde left ventricular pacing (1-6). We report a patient with double superior vena cava with PLSVC and no other cardiac abnormalities, incidentally diagnosed during echocardiographic examination.

## 2. Case report

A 24-year-old woman presented with complaints of palpitation and chest pain.

There were non-specific ST-T wave changes, which consisted of minimal ST segment depression and T wave inversion in inferior leads. Laboratory exams were within normal limits. Transthoracic echocardiography in parasternal long-axis view showed a dilated coronary sinus with dimensions of 15 mm x 16 mm (Figure 1).

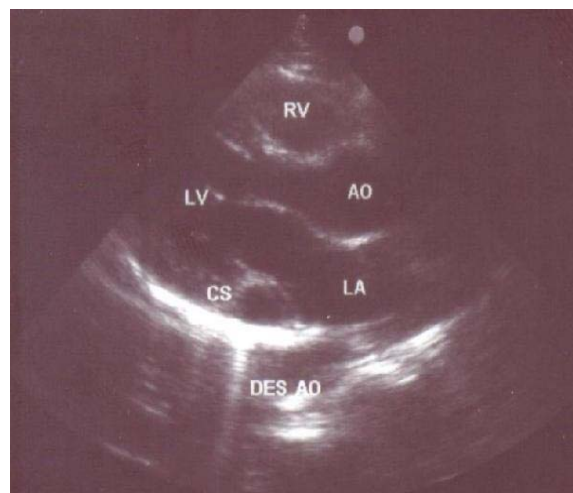


Fig. 1. Parasternal long axis two-dimensional echocardiographic view showing dilated coronary sinus. (LA = left atrium, LV = left ventricle, RV= right ventricle, CS = coronary sinus, AO= aorta, DES AO= descending aorta).

<sup>\*</sup>Correspondence: Dr. Mustafa Yurtdaş  
Medisina Hospital, Department of Cardiology,  
65200, Van/Turkey  
E-mail: mustafayurtdas@yahoo.com  
Tel: 0432 215 50 25  
Fax: 0432 212 10 08  
Received: 30.05.2011  
Accepted: 05.02.2012

There was no evidence of valvular heart disease and diameters of cardiac chambers were within normal limits. Systolic and diastolic function of the left ventricle and estimated pulmonary systolic pressure were in normal range. All pulmonary veins drained into the left atrium. In order to reveal the cause of coronary sinus dilation, an agitated saline injection was given into the right antecubital vein. The contrast agent entered only into the right atrium and right ventricle. Similarly, when the saline injection was given into the left antecubital vein, the contrast agent entered first into the dilated coronary sinus and subsequently appeared in the right atrium-right ventricle. (Figure 2).

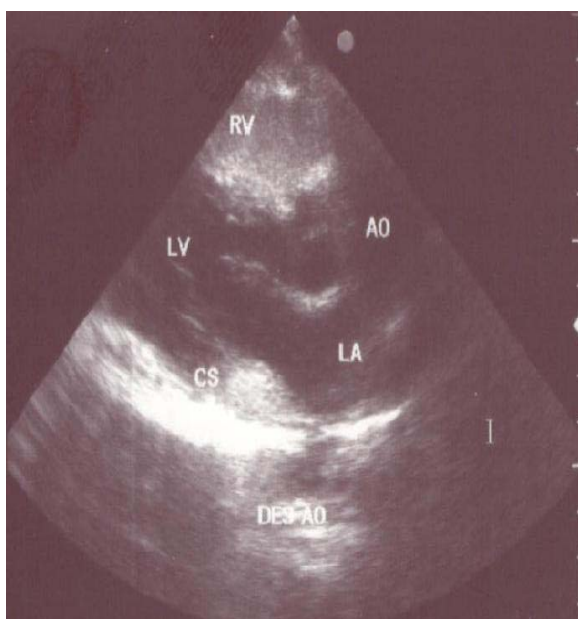


Fig. 2. Injection of agitated saline into left antecubital vein results in filling of coronary sinus first followed by the filling of the right atrium and right ventricle (LA = left atrium, LV = left ventricle, RV= right ventricle, CS = coronary sinus, AO= aorta, DES AO= descending aorta).

The chest CT scan with contrast showed the normal right superior vena cava and the persistent left superior vena cava (PLSVC) as it drains into the right atrium after joining the coronary sinus (Figure 3). Also, an anatomic correlation between PLSVC and the left branchiocephalic vein was identified. Right and persistent left caval veins have almost equal size. There were not any other communications between right and left caval systems, and any abnormal left to right venous communications on CT scan. Normal position and structure of visceral organs was confirmed by abdominal ultrasonography.

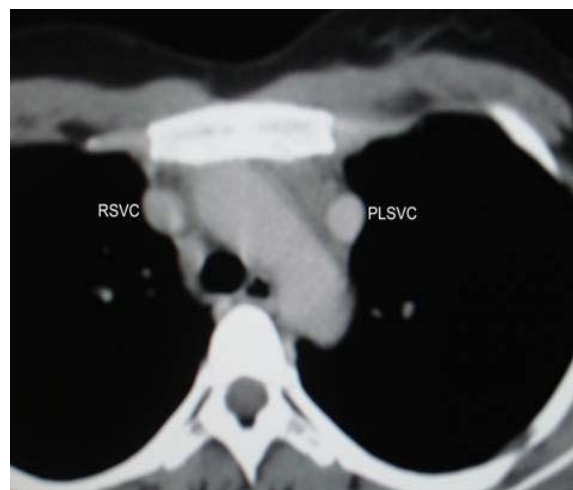


Fig. 3. Thoracic computed tomographic scan with contrast showing normal right superior vena cava (RSVC) and the left persistent superior vena cava (PLSVC).

### 3. Discussion

In the present case, we report a patient in whom double superior vena cava is associated with a PLSVC. Our report deals with the importance of detailed echocardiographic and computed tomographic examination for differential diagnosis of coronary sinus dilation and developmental abnormalities of great thoracic veins such as PLSVC, anomalous pulmonary venous drainage or congenital pulmonary varices. PLSVC is not the only cause of a dilated coronary sinus, however, with other etiologies including increased right atrial pressure, partial anomalous pulmonary venous return, coronary arterio-venous fistula, or an "unroofed" coronary sinus.

Double superior vena cava with a PLSVC is rarely encountered; it is estimated to exist in 0.3-0.5% of the general population and 3-10% of patients with other forms of congenital heart disease. It is a persistent remnant of a vessel that is present as an embryological counterpart of the normal right-sided superior vena cava. While the embryo grows, new organs appear and persist and others are transient and disappear. During the beginning of the fifth week, the anterior and posterior cardinal veins join to form common cardinal veins and enter the right and left horns of the sinus venosus. Due to the rightward direction of blood flow, the right horn of the sinus venosus occurs. Additionally, the left common cardinal veins and the distal part of the left horn become atretic and is delineated the ligament of Marshall or ligament of the left superior vena cava. If this

normal regression of the left superior cardinal vein fails to occur, a persistent left sided vascular structure results in PLSVC (1-4).

Many variations and abnormalities of this development have been published. The most common thoracic venous abnormality is the LPSVC draining into the coronary sinus with the presence of both left and right superior vena cava. This variation results in no haemodynamic compromise. A bridging innominate vein may lead to anatomical differences in these cases. A more uncommon abnormality is the persistence of a left superior vena cava connecting directly to the left atrium. This anomaly was observed in approximately 7.5% of cases of LPSVC, and it results in a small right to left shunt. This rare form has minor haemodynamic effect, mainly a variable degree of systemic cyanosis (3,4). PLSVC may also give rise to rhythm disturbances such as sinus node dysfunction and atrioventricular block. These rhythm problems may be related to fragmentation and stretching of the conduction tissue caused by expansion of the coronary sinus (1-4-6).

Detailed and accurate echocardiographic studies may identify this rare congenital defect, thus preventing future complications during invasive procedures such as cardiac pacemaker implantation, resynchronization therapy, radiofrequency catheter ablation, internal jugular or subclavian vein catheter insertion (1-5). Advances in cardiac pacemaker leads, catheter types and technique over time have provided to reduce complications related to these transactions. During cardiac surgery, the presence of PLSVC with adequate development of left innominate vein is a relative contraindication to the administration of retrograde cardioplegia. It may be possible to clamp the PLSVC to avoid the cardioplegia solution from perfusing retrograde up the PLSVC and its branches. However, there is a possibility that there may be some steal of cardioplegia solution through an accessory vein. Failure to cannulate the PLSVC in the absence of the left innominate vein or in the presence of an

inadequate left innominate vein will result in cerebral congestion. If the right superior vena cava is absent, all venous return from the upper body will drain through the LPSVC. Hence, this frustrates the use of the retrograde cardioplegia. In such a case, occlusion or ligation of the LPSVC would be fatal. During heart transplantation in a patient with PLSVC, the coronary sinus must be dissected carefully to permit reanastomosis of PLSVC to right atrium. For this reason, both operators and perfusionists should be aware of the anatomy of PLSVC and the intraoperative complications associated with this anomaly (4-6).

In conclusion, both clinicians and sonographers should be alerted to the possible presence of this venous anomaly and their clinical consequences so as to prevent possible complications in routine clinical practice and during cardiopulmonary bypass. It should be noted that transthoracic echocardiography-including agitated saline infusion to both antecubital vein - CT or MRI are important non-invasive diagnostic tools for accurate diagnosis of this rare congenital venous malformation.

## References

1. Chandra A, Reul GJ Jr. Persistent left superior vena cava. Discovered during placement of central venous catheter. *Tex Heart Inst J* 1998; 25: 90.
2. Biffi M, Boriani G, Frabetti L, Bronzetti G, Branzi A. Left superior vena cava persistence in patients undergoing pacemaker or cardioverter-defibrillator implantation: a 10-year experience. *Chest* 2001; 120: 139-144.
3. Paval J, Nayak S. A persistent left superior vena cava. *Singapore Med J* 2007; 48: 90-93.
4. Erdoğan M, Karakaş P, Uygur F, et al. Persistent left superior vena cava: the anatomical and surgical importance. *West Indian Med J* 2007; 56: 72-76.
5. Ying ZQ, Ma J, Xu G, Chen MY. Double superior vena cava with a persistent left superior vena cava. *Intern Med* 2008; 47: 679-680.
6. Goyal SK, Punnam SR, Verma G, Ruberg FL. Persistent left superior vena cava: a case report and review of literature. *Cardiovasc Ultrasound* 2008; 6: 50.