

Case Report

# Endoscopic endonasal drainage of sphenoid sinus mucocele in a child

Khadijah Mohd Nor<sup>a,b</sup> and Balwant Singh Gendeh<sup>c,\*</sup>

<sup>a</sup>Department of Otorhinolaryngology and Head & Neck, Serdang Hospital, Selangor, Malaysia

<sup>b</sup>Department of ORL-HNS, UM Medical Center, Kuala Lumpur, Malaysia

<sup>c</sup>Department of Otorhinolaryngology Head & Neck Surgery, Faculty of Medicine, Universiti Kebangsaan Malaysia, Kuala Lumpur, Malaysia

**Abstract.** The sphenoid sinus is the least common site for mucocele of all paranasal sinuses. It is very rare in children, especially in those younger than 12 years when pneumatization of the sphenoid sinus has not been completed yet. We report a case of histologically proven sphenoid sinus mucocele in an 8 year old child. The child presented with an acute onset of significant headache and vomiting. He also had a chronic problem of visual impairment. His vision gradually improved after endoscope endonasal sphenoidotomy and drainage of the sinus content which resolved all his symptoms. The rareness of paranasal sinus mucocele in children especially sphenoid occurrence prompted the authors to discuss the etiology, radiological imaging findings and the role of endoscopic endonasal sphenoidotomy.

Key words: Sphenoid sinus, Mucocele, Children, Endoscopic endonasal sphenoidotomy

## 1. Introduction

A mucocele is an epithelial-lined mucous-containing sac, generally completely filling a paranasal sinus. These lesions are thought to be secondary to an obstruction of the sinus ostium caused by an inflammation, fibrosis, trauma, previous surgery or mass effect (osteoma, Paget's disease, fibrous dysplasia, and malignancy) (1). However, there are different theories about their etiology, including cystic dilatation of the glandular structures and cystic development of embryonic epithelial residues (2). Mucoceles are benign, encapsulated, expansile, locally invasive masses within paranasal sinus filled with mucus and lined by epithelium. It can expand gradually and result in resorption and sometimes erosion of the bony walls of the sinus. The sphenoid sinus is an uncommon site of mucocele formation, especially in children. The symptomatology produced by mucoceles may vary depending on

the site of their occurrence, although headache, visual impairment, and diplopia seem to be the most common symptoms encountered in fronto-ethmoidal mucoceles (3,4). Diminished vision is a common presenting symptom. Because of its locally invasive, a sphenoid sinus mucocele might mimic a more serious condition or be associated with a tumor-like condition. MRI is usually helpful in characterizing the lesion. The marsupialization and drainage of the cyst is believed to be the mainstay of treatment (4) and the endoscopic approach seems to be the most successful tool in carrying out this type of surgical management (1,5-6). The endoscopic approach has also been successfully used in pediatric patients affected by mucoceles (5,6,7-9). In this case, we reported our experience with the use of the endoscopic approach for the treatment of child affected by mucoceles.

## 2. Case report

A 8-year-old child presented with a 2-weeks of increasing headache and vomiting. In the past few months, he had bilateral visual impairment, but no diplopia. Meanwhile, he was treated for astigmatism by the ophthalmologist. There was no other associated clinical abnormality of the eyes or any history of convulsion or sensory alteration. He had never complaining of rhinorrhoea, facial tenderness, nasal blockage or epistaxis. On examination, nasal endoscopy was performed and the findings were unremarkable.

\*Correspondence: Prof. Dato' Dr Balwant Singh Gendeh  
Department of Otorhinolaryngology Head & Neck Surgery,  
Faculty of Medicine, Universiti Kebangsaan Malaysia,  
Jalan Yaakub Latif, 56000 Cheras, Kuala Lumpur,  
Malaysia  
Tel: +603 91456047  
Fax: +603 91456675  
E-mail: bsgendeh@gmail.com  
Received: 08.09.2013  
Accepted: 05.11.2013

The MRI of the brain and skull base revealed a mild expansion of sphenoid sinus, suggestive of a sphenoid mucocele with mild extension into sphenoidal recess bilaterally with no evidence of cavernous sinus involvement (Figure 1). Pituitary gland and sella turcica were normal. The maxillary, frontal and ethmoid sinuses were clear.

Under general anaesthesia, an endoscopic left middle turbinate reduction and

sphenoethmoidectomy were carried out, and a mucocele within the sphenoid sinus was identified and marsupialized. The mucosal lining and the mucous within the mucocele was sent for diagnostic examination (Figure 2). Headache and vomiting resolved postoperatively within a few days, and his vision improved markedly and the patient can read without glasses.

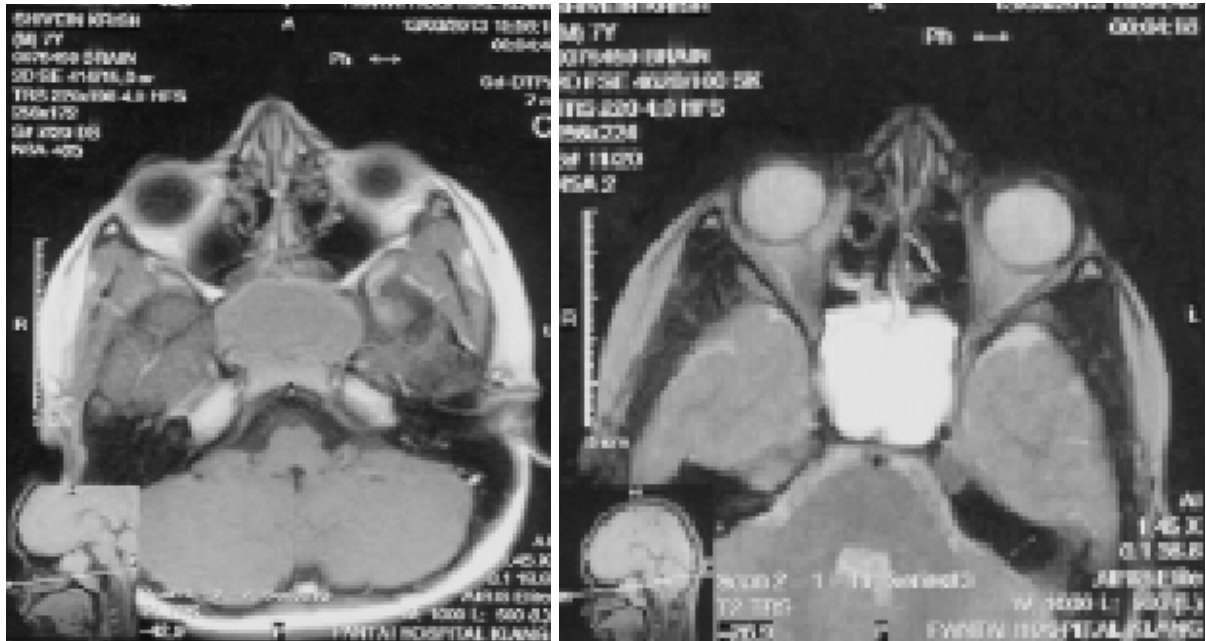


Fig. 1. Axial views of T1 and T2 weighted MRI images showing the mucocele of sphenoid reported in a 8-year-old male patient.

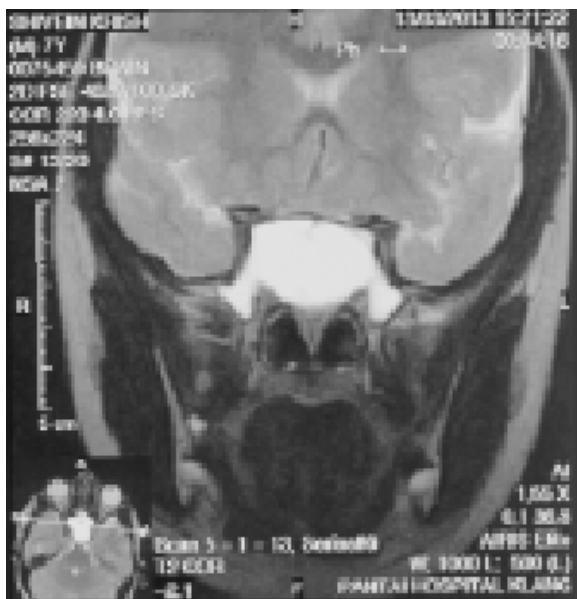

Fig. 2. Coronal section in MRI images showing the sphenoid mucocele.

### 3. Discussion

Mucoceleles are benign cystic lesions that enlarge slowly over the years and most commonly occurring at the level of the fronto-ethmoidal region (10). This slow growth may allow the mucocele to remain subclinical for a long period; and with the expansion and compression of the contiguous structures the symptoms arise (8). Mucoceleles arising within the frontal and anterior ethmoidal sinuses commonly produce frontal headache, proptosis, periorbital swelling and reduced ocular mobility. The senior author has reported 10 cases of paranasal sinus mucocele in adult (4 frontal, 2 frontoethmoidal, 1 ethmoidal, 1 maxillary, 1 sphenoethmoidal and 1 in sphenoid sinus) and its management by endoscopic marsupialization and the surgical outcome (11).

On the contrary, mucoceleles involving the posterior ethmoid and sphenoid sinuses have more subtle symptoms and present with visual disturbance, generalized headache with occipital

and vertex pain, globe displacement, and diplopia (1,6). On the other hand, rare sphenoidal mucoceles can produce a wide variety of symptoms depending on their direction of expansion, grade of pneumatization of the sphenoid and involvement of the surrounding structures. Levine indicated 13 sensitive structures which can be involved by an expansion of the sphenoid mucocele such as: the dura, the pituitary gland, the optic nerve and chiasm, the cavernous sinus, the internal carotid artery, the oculomotor nerve, the trochlear nerve, the abducens nerve, the maxillary nerve, the sphenopalatine ganglion, the sphenopalatine artery, the pterygoid canal, and nerve (12). Moriyama et al. (6) pointed out that the mechanisms of visual disturbance created by a sphenoidal mucocele are due to circulatory disorders caused by the mechanical pressure of the mucocele on the optic nerve and/or the spread of inflammation involving the optic nerve. Although the optic nerve is the most frequently involved cranial nerve with reduction of visual acuity (occurring in almost 65% of the cases), the oculomotor nerve seems to be involved in terms of frequency, although to a lesser degree (2,13,14). Sethi et al. (13) emphasized that the importance of a sphenoid sinus mucocele presenting with an isolated oculomotor nerve palsy. In fact, many of these lesions may be misdiagnosed as skull base tumors. For this reason, the immediate radiological assessment is essential for distinguishing between the great variability of lesions that may be involved in producing a cranial nerve palsy and for deciding the correct surgical management. Owing to the high frequency of ophthalmological symptoms produced by mucoceles, patients often go first to the ophthalmologist (6). For this patient, he complained of visual disturbance, and was treated as astigmatism, but the visual problem was resolved after surgery. Visual disturbances and cranial nerve palsies produced by mucoceles may represent an important interface between the disciplines of otolaryngology, ophthalmology, and neurosurgery (13).

In the last 20 years, few reports have shown the efficacy of the endoscopic approach in achieving the marsupialization and drainage of mucoceles (1,5,6). Mucoceles in children are thought to be extremely rare, and only several manuscripts have shown the efficacy of the endoscopic approach in these patients (5,7-9). Moreover, this mini-invasive treatment may be particularly useful in children and young adults, where an incision of an external approach is not always cosmetically acceptable (5, 15). In the literature,

most of the mucoceles in paediatric patients have been associated with cystic fibrosis which was absent in our patient (9). This was consistent with Hartley and Lund's (7) observation in their review of seven children treated for mucoceles by endoscopic surgery, none of whom suffered from cystic fibrosis.

The preoperative radiological assessment of mucoceles has paramount importance in reaching the correct diagnosis of the disease and in choosing the appropriate surgical treatment. Although an MRI is useful in differentiating a mucocele from the surrounding soft tissue or from tumors, only a CT scan can give us the bony details that are fundamental in carrying out the endoscopic surgery. Furthermore, CT scan is the optimum imaging method for showing the bone expansion which occurs during mucocele formation. In fact, in this circumstance, the bony outline becomes more rounded as the bone remodels to the growing pressure of the mucocele (16).

#### 4. Conclusion

This case pointed out the usefulness of the endoscopic approach for the treatment of mucoceles in the pediatric population. This mini-invasive technique permits accurate drainage and marsupialization of the mucocele with low morbidity, excellent visualization, lack of external incision, and other important thing is a shorter hospital stay, if compared to the other open approaches. Although a longer follow-up for these patients is warranted due to the slow growth of the mucocele, the endoscopic approach is a technique which can be repeated in cases of recurrence.

#### References

1. Conboy PJ, Jones NS. The place of endoscopic sinus surgery in the treatment of paranasal sinus mucoceles. *Clin Otolaryngol Allied Sci* 2003; 28: 207-210.
2. Haloi AK, Ditchfield M, Maixner W. Mucocele of the sphenoid sinus. *Pediatr Radiol* 2006; 36: 987-990.
3. Close LG, O'Conner WE. Sphenoidal mucoceles with intracranial extension. *Otolaryngol Head Neck Surg* 1983; 91: 350-357.
4. Har-El G, Balwally AN, Lucente FE. Sinus mucoceles: is marsupialization enough? *Otolaryngol Head Neck Surg* 1997; 117: 633-640.
5. Lund VJ. Endoscopic management of paranasal sinus mucoceles. *J Laryngol Otol* 1998; 112: 36-40.
6. Moriyama H, Hesaka H, Tachibana T, Honda Y. Mucoceles of ethmoid and sphenoid sinus with visual disturbance. *Arch Otolaryngol Head Neck Surg* 1992; 118: 142-146.

7. Hartley BE, Lund VJ. Endoscopic drainage of pediatric paranasal sinus mucoceles. *Int J Pediatr Otorhinolaryngol* 1999; 50: 109-111.
8. Zrada SE, Isaacson GC. Endoscopic treatment of pediatric ethmoid mucoceles. *Am J Otolaryngol* 1996; 17: 197-201.
9. Thomé DC, Voegels RL, Cataldo de la Cortina RA, Butugan O. Bilateral ethmoidal mucocele in cystic fibrosis: report of a case. *Int J Pediatr Otorhinolaryngol* 2000; 55: 143-148.
10. Lund VJ. Anatomical considerations in the aetiology of fronto-ethmoidal mucoceles. *Rhinology* 1987; 25: 83-88.
11. Namavar E, Loh JCN, Gendeh BS. Paranasal mucocele: endoscopic marsupialization and surgical outcome. *The Egyptian J. Otolaryngol* 2012; 28: 95-97.
12. Levine H. The sphenoid sinus, the neglected nasal sinus. *Arch Otolaryngol.* 1978; 104: 585-587.
13. Sethi DS, Lau DP, Chan C. Sphenoid sinus mucocoele presenting with isolated oculomotor nerve palsy. *J Laryngol Otol* 1997; 111: 471-473.
14. Friedmann G, Harrison S. Mucocoele of the sphenoidal sinus as a cause of recurrent oculomotor nerve palsy. *J Neurol Neurosurg Psychiatry* 1970; 33: 172-179.
15. Sharifi G, Jalessi M, Erfanian D, Farhadi M. English, Portuguese: Sudden blindness due to isolated sphenoid sinus mucocele and retention cyst. *Braz J Otorhinolaryngol* 2013; 79: 120.
16. Lloyd G, Lund VJ, Savy L, Howard D. Optimum imaging for mucoceles. *J Laryngol Otol* 2000; 114: 233-236.