

Skeletal Dentoalveolar and Soft Tissue Effects of β Thalassemia Major

Craniofacial Features of β Thalassemia Major

Atılım Akkurt^a, Mehmet DOGRU^a, Arzum Guler DOGRU^c, Kamile Keskin^b

a Assistant Professor Department of Orthodontics, Faculty of Dentistry, Dicle University, Diyarbakir, Turkey.

b Research Assistant Department of Orthodontics, Faculty of Dentistry, Dicle University, Diyarbakir, Turkey.

c Assistant Professor Department of Periodontology, Faculty of Dentistry, Dicle University, Diyarbakir, Turkey.

Abstract

Objective: Thalassemia (TH) is a genetic disorder of hemoglobin synthesis caused by the absence or reduced synthesis of globin chains which causes different craniofacial effects. The purpose of this study is to evaluate the skeletal, dental and soft tissue cephalometric features of TH patients.

Materials and Methods: Present study consisted of lateral cephalometric images obtained from CBCT scans of 25 TH (mean age: 13,7 \pm 3,8 years) and 50 normal (mean age: 13,9 \pm 1,81 years) individuals. An Independent sample *t* was used to compare the cephalometric measurements.

Results: TH patients revealed a high angle Class II pattern (SnGoMe, Sum $p < 0,01$, ANS-PNS/GoMe, ANB, $p < 0,001$) caused by retruded mandible (SNB, SNPog, $p < 0,001$) with retrusive upper (U1-Na $^\circ$, $p < 0,01$, U1-Na mm $p < 0,001$) and protrusive lower incisors (L1Nb $^\circ$, $p < 0,001$, IMPA, $p < 0,05$, L1Nb mm, $p < 0,01$). Except the S-N length ($p > 0,05$), all craniofacial parameters (S-Ar $p < 0,05$, S-Go $p < 0,01$, Ar-Go, N-Me $p < 0,05$, Go-Me, S-Go/N-Me $p < 0,001$) of TH patients' found significantly smaller than that obtained from normal individuals. On the contrary ANS-PNS parameter ($p < 0,01$) was found significantly bigger in TH patients'. In addition TH patients have protrusive upper ($p < 0,05$) and lower lips ($p < 0,01$) accompanied with an increased nasolabial angle ($p < 0,01$) when compared with normal individuals.

Conclusion: A high angle Class II pattern caused by the retrusion and clockwise rotation of mandible accompanied with retrusive upper, protrusive lower incisors and protrusive upper and lower lips may be considered the most common craniofacial features of TH patients.

* Corresponding author: Atılım AKKURT, Dicle University, Faculty of Dentistry, Department of Orthodontics, Diyarbakir, Turkey.
e-mail: aakkurt@dicle.edu.tr

INTRODUCTION

Thalassemia (TH) also called Mediterranean anemia is a genetic disorder of hemoglobin synthesis caused by the absence or reduced synthesis of globin chains. Different classifications were made such as TH major, minor and intermediate or α and β TH according to the genetic and clinical findings or affected globin chains.^{1,2} TH minor characterized mild morphologic abnormalities whereas TH major presented a life threatening disease with severe clinical symptoms and orofacial deformations which required blood transfusion.¹

Abnormal globin chain synthesis leads to anemia, hepatosplenomegaly and ineffective erythropoiesis which result in expansion of the bone marrow.^{3,4} Growth and development retardation is a common finding in TH patients. Possible causes of retardation are chronic anemia⁵, hyperparathyroidism⁶ and somatomedin deficiency⁷ which stimulates the cartilage growth.

According to the reports of the previous studies, severity of the TH effects depends on the severity of the anemia, patient's age, duration of clinical symptoms, timing of both therapeutic blood transfusion and splenectomy.^{5,8} It has been reported that transfusion therapy would reduced or, indeed prevent development of bony abnormalities in growing patients.^{8,9} However according to Sun¹⁰ the prognosis is very poor in β TH. Cannell¹¹ reported the life expectancy of these patients under the best medical management, rarely greater than 30 years of age.

Some studies revealed that the carrier rate reaches 60 per cent^{12,13} in south-east Asian countries. It has been reported that for each year 120- 350 patients are born with TH in Malaysia.¹⁴ According to another study 1500 individuals were affected by TH in Iran.¹⁵ Cavdar and Arcasoy¹⁶ reported that the incidence of β TH in Turkish population is 1.66%. Thus, TH may be considered a common public health problem around Asian region.

Oral mucosa displayed a characteristic pallor in TH major. The gingival tissues appeared thin and pale but are often otherwise normal. The incidence of gingivitis in children with the disease seems likely related to local factors such as poor oral hygiene, malocclusion and drying of the gingiva through the patient's inability to close his mouth over the protruding teeth. The chronic anoxemia may in some cases predispose to gingival disorders.⁹

The craniofacial features of TH patients from different countries were described in several studies.¹⁷⁻²⁴ Although some of them^{23,24} were mainly based on observation, most of these studies reported a high angle Class II skeletal growth pattern with a significantly increased ANB angle.¹⁹⁻²² However mild skeletal Class II and maxillary protrusion were also determined.^{17,18} All of these studies used traditional cephalometric radiographs which may have some possible disadvantages such as distortion and magnification errors.²⁵ With the introduction of Cone-Beam Computed Tomography (CBCT) systems in 1990s²⁶, creating 3D anatomically true images has become available.²⁷ In recent years CBCT systems has been widely used due to the advantages such as, providing lower radiation dose and lower prices when compared with conventional CT systems.^{28,29} Orientation of the craniofacial structures with using CBCT images via some software may considered as an advantage to reduce the superposition. Thus more accurate data obtained from cephalometric evaluations.

The purpose of this study is to evaluate the skeletal, dental and soft tissue cephalometric features of TH patients and compare these findings with Class I normal individuals with using oriented lateral cephalograms which obtained from CBCT images.

MATERIAL-METHOD

The present study consisted of lateral cephalometric images obtained from CBCT scans of 25 TH (13 females and 12 males, aged between 10,1-27,9 years) patients with the mean age of $13,7\pm 3,8$ years whom referred to Periodontology Department of Faculty of Dentistry, Dicle University as a part of their periodontal treatment. The control group was consisted of 50 patients (23 females and 22 males) with the mean age of $13,9\pm 1,81$ years. Patients who had orthodontic treatment or any other acquired developmental or congenital craniofacial deformities were not included. Due to the limited sample size and insignificant age and cephalometric differences between sexes, male and female measurements in each group were pooled.

In our university all patients have to sign in an informed consent form before CBCT exposure. CBCT scans of TH patients were provided for another research and the ethical approval had already been obtained from the Ethical Committee of the Dicle University (DUD-FEK 2009/21). CBCT scans used in control group were selected from the archive of radiology department thus ethics committee approval was not needed.

All CBCT images were acquired with an i-CAT 3D imaging device (Imaging Sciences International, Hatfield, Pa). The device was set for 5.0 mA and 120 kV. A 9.6-second scan with a single 360 degree rotation created images with a voxel size of 0.3 mm. As a routine image exposure protocol, the patients' heads were oriented by adjusting the Frankfort plane parallel to the horizontal plane, and the CBCT scans were taken while the patients bite into maximum intercuspation.

Due to the cephalometric analysis of groups, Digital Imaging and Communications in Medicine (DICOM) files obtained from the CBCT scans were exported to the Dolphin 11.0 (Dolphin Imaging, Chatsworth, Calif, USA) Imaging software. Cephalograms were first oriented with using the 3D module of the software according to the Frankfort horizontal and midsagittal plane. Thus, superposition and unwanted angulations were minimized.

Cephalometric radiographs obtained from the groups were analyzed by using Dolphin software. A customized analysis that was a combination of Jarabak, Björk, Eastman and Steiner analysis was used. Thirty angular and linear (16 angular, 14 linear) measurements were chosen to identify the differences between groups Table 1. The landmarks and planes used in this study are shown in Figure 1.

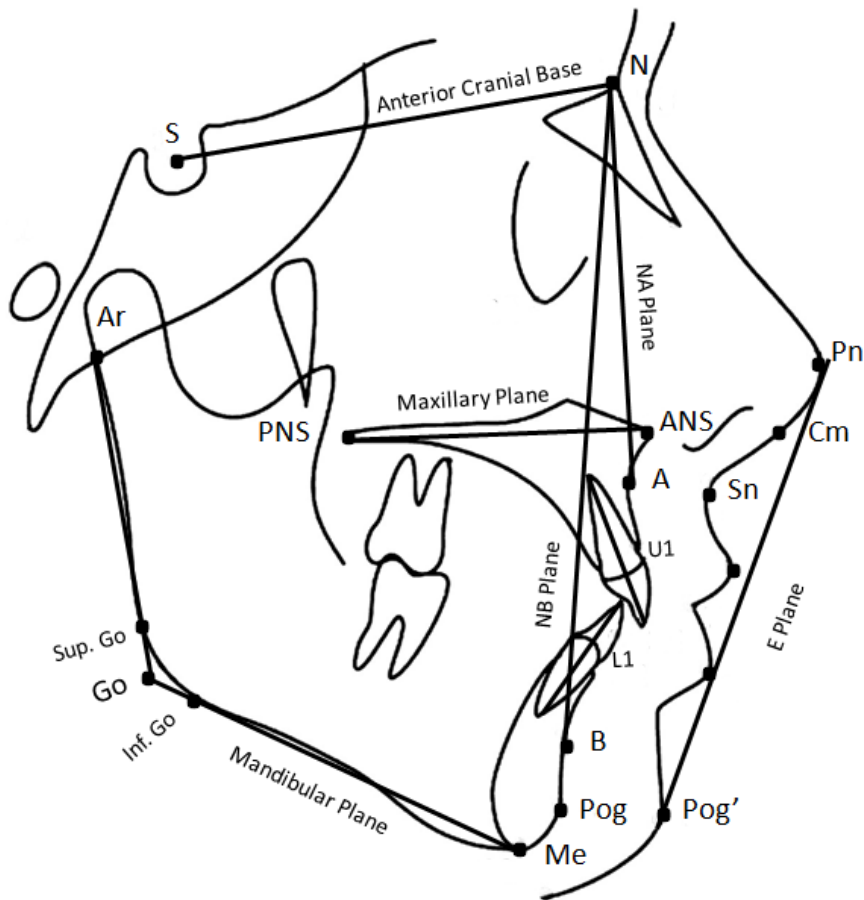


Figure 1. Cephalometric landmarks and points. N: Nasion, the most anterior point of the frontonasal suture in the midsagittal plane; S = Sella, The centre of sella turcica; Ar = Articulare, a point at the intersection of the image of the posterior margin of the ramus and the outer margin of the cranial base; Go = Gonion, a point at the intersection of lines tangent to the posterior border of the ramus (articulare–superior gonion; Sup. Go) and the lower border of the mandible (menton–inferior gonion; Inf. Go); Me = menton, the most inferior point of the outline of the symphysis in the midsagittal plane; Gn = gnathion, the most anterior inferior point of the bony chin; Pog = pogonion, the most anterior point of the bony chin in the midsagittal plane; B point = The deepest point on the outer contour of the mandible; A = A point, the deepest midline point on the anterior outer contour of the maxillary alveolar process; ANS = anterior nasal spine, the most anterior point of the tip of the anterior nasal spine in the midsagittal plane; PNS = posterior nasal spine; Na Plane= Plane running through Nasion and A point; Nb Plane: Plane running through Nasion and B point; L1 = Lower incisal constructed between mandibular incisal tip and its apex; U1 = Upper incisor constructed between maxillary incisal tip of and its apex; Pog' = Soft tissue pogonion, the most anterior point on the soft tissue chin; Li = Labrale inferius, the muco-cutaneous border of the lower lip; Ls = Labrale superius, point on the muco-cutaneous junction of upper lip and philtrum; Sn = Subnasale, point at which the nasal septum merges with the upper cutaneous lip in the midsagittal plane; Cm = Columella, the most anterior point on the columella of the nose; Pn = Pronasale, the most prominent point on the tip of the nose. Maxillary plane = Plane running through ANS and PNS; Mandibular plane = Plane running through points Me and Go; E plane = Plane running through points Pn and Pog'

Table 1. Defination of the cephalometric measurements.

| Measurement | Definition |
|--------------------------|--|
| Angular | |
| SNA (°) | Angle between point A and anterior cranial base (S–N) |
| SNB (°) | Angle between point A, nasion, and point B |
| ANB (°) | Angle between point A, nasion and point B |
| SnPog (°) | Angle between anterior cranial base and pogonion |
| NSAr (°) | Angle between points nasion,sella and articulare |
| ArGoMe (°) | Angle between points articulare, gonion, and menton |
| SArGo (°) | Angle between points sella, articulare and gonion |
| Sum (°) | Sum of the angles NSAr, SArGo and ArGoMe |
| SnGoMe (°) | Angle between cranial base and mandibular plane |
| Sn/ANS-PNS (°) | Angle between cranial base and maxillary plane |
| ANS-PNS/Go-Me (°) | Angle between maxillary plane and mandibular plane |
| U1-Na (°) | Angle between upper incisor and Na plane |
| L1Nb (°) | Angle between lower incisor and Na plane |
| U1L1 (°) | Angle between upper incisor and lower incisor |
| IMPA (°) | Angle between lower incisor and mandibular plane |
| Nasolabial Angle (°) | Angle between columella, subnasale, and labrale superius |
| Linear | |
| S-N (mm) | Anterior cranial base length |
| S-Ar (mm) | Posterior cranial base length |
| S-Go (mm) | Posterior Face Height (PFH) between S point and Go point |
| Ar-Go (mm) | Mandibular ramus height |
| Go-Me (mm) | Distance between Go point and Me point |
| ANS-PNS (mm) | Length of the maxillary base between anterior and posterior nasal spine |
| N-ME (mm) | Anterior Face Height (AFH) between N point and Me point |
| PFH:AFH (%) | Ratio between anterior and posterior face height |
| U1NA (mm) | Distance between Upper incisor and Na plane |
| L1NB (mm) | Distance between Lower incisor and Nb plane |
| OVERJET (mm) | Sagittal distance between the incisal edges of the most prominent upper and lower incisors. |
| OVERBITE (mm) | Vertical distance between the incisal edges of upper and lower incisors. |
| Upper lip to E line (mm) | The distance of the upper lip to E plane measured at the right angle from labrale superior to E plane |
| Lower lip to E line (mm) | The distance of the lower lip to E plane measured at the right angles from labrale inferior to E plane |

Method Error

For method error evaluation, randomly selected 15 cephalograms from each group were re-traced after 4 weeks by the same examiner (A.A.). Paired sample *t* test was not showed any significant differences between repeated measurements ($p > 0,05$). The degree of reproducibility of measurements using intraclass correlation coefficient, to detect any random error, showed good reproducibility with a minimum value of 0.743.

Statistical Analysis

Descriptive statistics, including the mean, standard deviation (SD), and difference between the means for each group, were analyzed with using the Statistical Package for Social Sciences version 16.0 (SPSS Inc., Chicago, Illinois, USA). An Independent sample *t* test was used for comparison of cephalometric measurements, with $p < 0,05$ set as the level of significance.

RESULTS

Descriptive statistics including means, standard deviations, mean differences and comparison of the cephalometric measurements between groups are given in Table 2. According to the results of Independent Sample *t* test, 21 of the 30 parameters showed statistically significant differences.

Skeletal Parameters

Significant differences among groups were observed which reflected a high angle (SnGoMe $p < 0,01$, ANS-PNS/GoMe $p < 0,001$, Sum $p < 0,01$) Class II (ANB, $p < 0,001$) pattern caused by a retruded chin position (SNPog, $p < 0,001$) and mandible (SNB, $p < 0,001$) in TH patients. In addition, all linear measurements (S-Ar $p < 0,05$, S-Go $p < 0,01$, Ar-Go $p < 0,05$, Go-Me $p < 0,001$, N-Me $p < 0,05$, S-Go/N-Me $p < 0,001$) except S-N parameter were found significantly lower in TH patients. On the contrary ANS-PNS ($p < 0,01$) parameter was found significantly higher in TH patients than controls.

Dental Parameters

Dentoalveolar relationship showed a significant retrusion of upper incisors (U1-Na°, $p < 0,01$) accompanied with a backward position according to their bony basis (U1-Na mm $p < 0,001$). However significant protrusion of lower incisors (L1Nb °, $p < 0,001$, IMPA, $p < 0,05$) accompanied with a forward position according to their bony basis (L1Nb mm, $p < 0,01$) was observed in TH patients when compared with controls. No significant differences were observed in U1-L1, Overjet and Overbite parameters.

Soft Tissue Parameters:

Soft tissue analysis revealed proclined position of the upper (Upperlip to E line, $p < 0,05$) and lower lips (Lowerlip to E line, $p < 0,01$) according to the E line accompanied with an increased nasolabial angle ($p < 0,01$) in TH patients.

Table 2. Descriptive statistics and comparison of the cephalometric measurements between groups.

| Parameter | Thalassemia (n=25) | | Control (n=50) | | Mean Difference | p | Level of significance |
|-----------------------------------|--------------------|------|----------------|-------|-----------------|-------|-----------------------|
| | Mean | SD | Mean | SD | | | |
| Skeletal Measurements | | | | | | | |
| SNA (°) | 81.50 | 3.41 | 80.63 | 2.75 | -0.86 | 0.307 | NS |
| SNB (°) | 74.95 | 3.12 | 78.02 | 2.98 | 3.06 | 0.001 | *** |
| ANB (°) | 6.04 | 1.58 | 2.60 | 1.18 | -3.43 | 0.000 | *** |
| SnPog (°) | 75.27 | 3.14 | 79.27 | 3.29 | 4.00 | 0.000 | *** |
| NSAr (°) | 123.45 | 5.24 | 122.45 | 6.60 | -0.99 | 0.555 | NS |
| ArGoMe (°) | 125.86 | 6.90 | 123.99 | 6.90 | -1.86 | 0.332 | NS |
| SArGo (°) | 147.72 | 7.04 | 148.30 | 7.48 | 0.57 | 0.776 | NS |
| Sum (°) | 397.03 | 5.10 | 393.33 | 3.22 | -3.71 | 0.002 | ** |
| SnGoMe (°) | 37.04 | 5.16 | 33.82 | 3.39 | -3.22 | 0.007 | ** |
| Sn/ANS-PNS (°) | 7.90 | 3.03 | 8.66 | 3.60 | 0.75 | 0.420 | NS |
| ANS-PNS/GoMe (°) | 31.00 | 5.42 | 25.54 | 4.79 | -5.45 | 0.000 | *** |
| S-N (mm) | 62.50 | 4.05 | 64.04 | 2.86 | 1.54 | 0.102 | NS |
| S-Ar (mm) | 29.18 | 3.00 | 31.61 | 3.61 | 2.43 | 0.012 | * |
| S-Go (mm) | 65.95 | 5.54 | 70.87 | 6.18 | 4.92 | 0.004 | ** |
| Ar-Go (mm) | 39.50 | 4.28 | 42.22 | 4.21 | 2.72 | 0.023 | * |
| Go-Me (mm) | 60.00 | 4.92 | 67.22 | 6.30 | 7.22 | 0.000 | *** |
| ANS-PNS (mm) | 48.45 | 4.20 | 45.66 | 3.80 | -2.78 | 0.014 | ** |
| N-ME (mm) | 104.45 | 6.24 | 108.53 | 7.41 | 4.08 | 0.038 | * |
| PFH:AFH (%) | 63.13 | 4.14 | 76.13 | 3.39 | 13.00 | 0.000 | *** |
| Dentoalveolar measurements | | | | | | | |
| U1-Na (°) | 12.22 | 6.05 | 17.86 | 7.49 | 5.63 | 0.005 | ** |
| U1Na (mm) | 2.45 | 1.62 | 4.23 | 2.02 | 1.78 | 0.001 | *** |
| L1Nb (°) | 27.18 | 5.59 | 21.88 | 5.72 | -5.29 | 0.001 | *** |
| L1Nb (mm) | 5.68 | 1.67 | 4.56 | 1.62 | -1.11 | 0.017 | ** |
| U1L1 (°) | 132.86 | 9.40 | 134.91 | 11.13 | 2.05 | 0.479 | NS |
| IMPA (°) | 95.00 | 6.17 | 89.89 | 6.46 | -4.69 | 0.010 | * |
| OVERJET (mm) | 2.54 | 1.37 | 3.43 | 2.85 | 0.89 | 0.178 | NS |
| OVERBITE (mm) | 1.50 | 1.87 | 1.90 | 2.08 | 0.40 | 0.462 | NS |
| Soft tissue measurements | | | | | | | |
| Nasolabial Angle (°) | 113.5 | 7.9 | 105.4 | 11.1 | 8.01 | 0.010 | ** |
| Upperlip to E line (mm) | -0.09 | 1.69 | -1.76 | 3.35 | -1.66 | 0.036 | * |
| Lowerlip to E line (mm) | 2.13 | 1.78 | 0.14 | 2.44 | -1.99 | 0.002 | ** |

NS; Not Significant, *p<0.05, ** p<0.01, *** p<0.001

DISCUSSION

The sagittal angular parameters of TH patients obtained from the present study revealed a Class II relationship with an increased ANB angle (p<0,001) accompanied with a retrusive mandible (SNB, p<0,001) and chin position (SNPog, p<0,001) when compared with normal individuals. These findings are in accordance with the previous studies.¹⁹⁻²² Although Ahmed Toman et al¹⁷ reported a slightly increased ANB angle, the mean SNA and SNB angles of the control group was 88,2° and 84,9° respectively which may considered as bimaxillary protrusion. The increased ANB angle obtained from the present study may be a result of short mandibular corpus length^{20,21} (S-Go, p<0,01), clockwise rotation of mandible²⁰ (SnGoMe, p<0,01) and reduced

posterior cranial base²¹ (S-Ar, $p < 0,05$). It has been reported that a sagittal over growth of the maxilla occurs in TH patients due to its' composition, involving more cancellous bone-containing marrow spaces than the mandible.^{5,9,23} However, only an insignificant increase tendency was observed in SNA parameter of TH group from the present study. But significantly increased ANS-PNS ($p < 0,01$) measurement from TH group may be considered as a sagittal growth tendency of maxilla.

The significantly increased vertical angular parameters such as SN-GoMe ($p < 0,01$), ANS-PNS/Go-Me ($p < 0.001$) and Sum of angles accompanied with a decreased mandibular ramus (Ar-Go, $p < 0.05$) and posterior cranial base length (S-Ar, $p < 0.05$) showed a high angle pattern of TH patients when compared with normal individuals. Although not statistically significant, larger NSAr and ArGoMe angles were also obtained from TH patients. These findings are in accordance with the result of the previous studies.¹⁹⁻²² Vertical growth pattern of TH patients may be a result of muscular weakness⁸ as well as deficient condyler and ramus growth.²¹ Another possible cause of vertical growth pattern in TH patients may be the mouth breathing which reported from the previous studies.²² Mouth breathing leads to the lower position of the tongue in the oral cavity thus force balance of the facial muscles changed when compared with nasal breathers.³⁰ Some studies^{31,32} reported that clockwise rotation of the mandible is a common finding in oral breathing patients.

Present study showed a significant reduction in anterior and posterior face length as well as jarabak ratio in TH patients when compared with controls. The results of the previous studies^{17,19,20} were in accordance with the result of this study. However our results are different from the results of Bassimitci et al²² who reported no significant differences between the TH and control group in the measurements of total and lower posterior face height while anterior face height was increased. All linear cranial measurements except the S-N and ANS-PNS parameters of TH patients obtained from the present study were smaller than that obtained from the control group. Some studies reported that TH has a retarding effect on general skeletal maturation according to the hand-wrist radiographs.^{33,34} The reduced linear measurements including anterior and posterior face height may be related with the general growth retardation due to the chronic anaemia⁵, hyperparathyroidism⁶ and somatomedin⁷ deficiency which may cause deficient condyler and ramus growth.²¹ Another possible cause of significantly reduced Jarabak ratio may be related with oral breathing of TH patients'. Bakor et al³⁵ evaluated the craniofacial growth variations in nasal breathing, oral breathing and tracheotomized children and reported an increased SN-GoMe angle while significant reduction of Jarabak ratio occurred in oral breathing children.

Significant retrusion of upper maxillary incisor and protrusion of lower incisors were determined from TH patients. Similar results are obtained from the previous¹⁹⁻²¹ studies. Although Abu Alhaija et al²⁰ reported no significant dentoalveolar differences between TH and controls they also emphasized an upright or retroclined upper incisors tendency in some TH cases. Although Ahmed Toman et al¹⁷ reported no significant dentoalveolar differences except the upper incisors of TH patients which were less proclined, the mean IMPA calculated from the control group was 96° . The mean IMPA, calculated from the control group of the present study is $88,89^\circ$ which may considered within normal range. Retrusion of upper incisors and protrusion of lower incisors determined from TH patients of present study may be a result of dentoalveolar compensation mechanism due to the Class II malocclusion which maintains the normal interarch relationship.³⁶ Thus no significant differences observed in overjet, overbite and interincisal angle parameters may be explained by retrusion of upper and protrusion of lower incisors which may also considered as a dentoalveolar compensation mechanism.

TH patients showed more proclined upper ($p < 0.05$) and lower lip position ($p < 0.01$) accompanied with a larger nasolabial angle ($p < 0.01$) when compared with controls. Similar results obtained from the study of Ahmed Toman et al¹⁷ and Bassimitci et al²². Lip position is affected by the placement and inclinations of maxillary and mandibular incisors. Likewise, nasolabial angle is affected by maxilla, maxillary anterior teeth angulation, nasal anatomy and the upper lip thickness.³⁷ Larger nasolabial angle and proclined lower lip position may be explained by significant retrusion of upper incisors and protrusion of lower incisors respectively. However upper lip proclination could not be explained by upper incisor retrusion. Depressed nose¹⁷ together with a retrognathic chin position which caused the retro position of upper and lower points' of the E plane may explain the proclined upper and lower lips in TH patients⁷.

CONCLUSION

According to the results of the present study it may be concluded that a skeletal high angle Class II pattern due to a retrognathic mandible and chin accompanied with reduced craniofacial measurements and retrusive upper and protrusive lower incisors are the most common craniofacial features of the TH patients when compared with Class I normal individuals.

REFERENCES

1. Weatherall DJ, Clegg JB. The β thalassaemia. In: The thalassaemia syndromes. Oxford: Blackwell Science. 1981: 149–56.
2. Duggal MS, Bedi R, Kinsey SE, Williams SA. The dental management of children with sickle cell disease and β thalassaemia: a review. International Journal of Paediatric Dentistry. 1996; 6: 227–234.
3. Mohamed N, Jackson N. Severe thalassaemia intermedia: clinical problems in the absence of hypertransfusion. Blood Reviews. 1998;12: 163–170.
4. Tyler P A, Madani G, Chaudhuri R, Wilson L F, Dick E A. The radiological appearances of thalassaemia. Clinical Radiology. 2006;61: 40–52.
5. Caffey J. Cooley's anemia : a review of the roentgenographic findings in the skeleton. [Am J Roentgenol Radium Ther Nucl Med](#). 1957;78:381-91.
6. [Flynn DM](#), Fairney A, [Jackson D](#), [Clayton BE](#). Hormonal changes in thalassaemia major. [Arch Dis Child](#). 1976;51:828-36.
7. Saenger P, Schwartz E, [Markenson AL](#), [Graziano JH](#), [Levine LS](#), [New MI](#), [Hilgartner MW](#). Depressed serum somatomedin activity in beta-thalassemia. [J Pediatr](#). 1980;9:214-8.
8. Logothetis J, Economidou J, Constantoulakis M, Augoustaki O, Loewenson R B, Bilek M. Cephalofacial deformities in thalassaemia major (Cooley's anemia). A correlative study among 138 cases. American Journal of Diseases of Children 1971;121: 300–306.
9. Kaplan RI, Werther R, Castano FA. Dental and oral findings in Cooley's anemia: a study of fifty cases. Annals New York Academy of Science. 1964;119:664-66.
10. Sun NCJ. Hematology: An Atlas and Diagnostic Guide, W.B. Saunders Company , Philadelphia,pp:58-61.
11. Cannell H. the development of oral and facial signs in β thalassaemia major. Br J Orthod. 1988;164:50-51.
12. Vichinsky E P. Changing patterns of thalassaemia worldwide. Annals of the New York Academy of Sciences. 2005;1054: 18–24.
13. Ismail A, Campbell M J, Ibrahim H M, Jones G L. Health related quality of life in Malaysian children with thalassaemia. Health and Quality of Life Outcomes. 2006;4: 39.

14. Malaysian Health Technology Assessment Unit. Management of thalassaemia. Report. MOH/PAK/77.03 (TR) Malaysia Ministry of Health, Kuala Lumpur 2003.
15. Farhud D, Sadighi H. Investigation of prevalence of beta thalassaemia in Iranian provinces. *Iranian J Pub Health*. 1997;26:3-6.
16. Çavdar A O, Arcasoy A. The Incidence of β -Thalassaemia and Abnormal Hemoglobins in Turkey. *Acta Haematol* 1971;45:312-8.
17. [Toman HA](#), [Nasir A](#), [Hassan R](#), [Hassan R](#). Skeletal, dentoalveolar, and soft tissue cephalometric measurements of Malay transfusion-dependent thalassaemia patients. *Eur J Orthod*. 2011;33:700-4.
18. MR Salehi, DD Farhud , TZ Tohidast , M Sahebamee , H Khademi. Prevalence of Orofacial Complications in Iranian Patients with β Thalassaemia Major. *Iranian J Publ Health*. 2007;36:43-6.
19. M Takriti, Dashash. Craniofacial parameters of Syrian children with b-thalassaemia major. *J Invest Clin Dent*. 2011;2:1-9.
20. [Abu Alhajja ES](#), [Hattab FN](#), [Al-Omari MA](#). Cephalometric measurements and facial deformities in subjects with beta-thalassaemia major. *Eur J Orthod*. 2002;24:9-19.
21. [Amini F](#), [Jafari A](#), [Eslamian L](#), [Sharifzadeh S](#). A cephalometric study on craniofacial morphology of Iranian children with beta-thalassaemia major. *Orthod Craniofac Res*. 2007;10:36-44.
22. Bassimitci S, Yucel-Eroglu E, Akalar M. Effects of thalassaemia major on components of the craniofacial complex. *Br J Orthod*. 1996;23: 157–62.
23. Pusaksrikrit S, Isarangkura P, Hathirat P. Occlusion of the teeth in thalassaemic patients. *Birth Defects Original Articles Series*. 1987;23: 429–433.
24. Hes J, van der Waal I, de Man K. Bimaxillary hyperplasia: the facial expression of homozygous beta-thalassaemia. *Oral Surgery, Oral Medicine, Oral Pathology*. 1990;69: 185-90.
25. Pullinger A, Thurston M, Turley P. Condylar adaptation to unilateral posterior crossbite in adults. *J Dent Res*. 1985;64: 269.
26. International Commission on Radiation Protection. Recommendations of the International Commission on Radiation Protection, ICRP Publication 26. *Ann ICRP*. 1977;1:3.
27. Schlueter BA. Cone Beam Computed Tomography Threedimensional Reconstruction for Evaluation of the Mandibular Condyle [thesis]. St Louis, Mo: Saint Louis University; 2007.
28. Ludlow JB, Ivanovic M. Comparative dosimetry of dental CBCT devices and 64-slice CT for oral and maxillofacial radiology. *Oral Surg Oral Med Oral Pathol Oral Radiol Endod*. 2008;106:106–14.
29. White SC. Cone-beam imaging in dentistry. *Health Phys*. 2008;95:628–37.
30. Solow B, Siersbaek-Nielsen S, Greve E. Airway adequacy, head posture, and craniofacial morphology. *Am J Orthod* 1984;86:214-23.
31. Pereira FC, Motonaga SM, Faria PM, Matsumoto MA, Trawitzki LY, Lima SA, et al. Myofunctional and cephalometric evaluation of mouth breathers. *Rev Bras Otorrinolaringol* 2001;67:43-9.
32. Valera FC, Travitzki LV, Mattar SE, Matsumoto MA, Elias AM, Anselmo-Lima WT. Muscular, functional and orthodontic changes in preschool children with enlarged adenoids and tonsils. *Int J Pediatr Otorhinolaryngol* 2003;67:761-70.
33. Johnston FE, Krogman WM. Patterns of growth in children with thalassaemia major. *Annals New York Academy of Sciences*. 1964;119:667-69.
34. Laor E, Garfunkel A, Koyoumdjisky E. Skeletal and dental retardations in β thalassaemia major. *Human Biology*. 1982;54:85-92.

35. [Bakor SF](#), [Enlow DH](#), [Pontes P](#), [De Biase NG](#). Craniofacial growth variations in nasal-breathing, oral-breathing, and tracheotomized children. [Am J Orthod Dentofacial Orthop](#). 2011;140:486-92.
36. Solow B. The dentoalveolar compensatory mechanism: Background and clinical implications. *Br J Orthod*. 1980;7:145–161.
37. Sarver D M. *Esthetic orthodontic and orthognathic surgery*. Mosby, St Louis; 1998.