



Type I Monteggia fracture in a kitten; a review on diagnostic and therapeutic methods

Uğur AYDIN¹, Sadık YAYLA^{1*}, Engin KILIÇ¹

¹Universty of Kafkas, Faculty of Veterinary Medicine, Department of Surgery, Kars, Turkey

Geliş Tarihi/Received
13.09.2018

Kabul Tarihi/Accepted
30.10.2018

Yayın Tarihi/Published
31.12.2018

Abstract

In this paper, it was aimed to report the type I Monteggia fracture in a kitten and its treatment results. In clinical examination of a 4-month-old female kitten brought to our clinic with complaints of lameness in the front left leg after automobile trauma it was diagnosed with a fracture in 1/3 proximal diaphyseal of ulna with cranial dislocation of the radial head. Following general anesthesia, ulnar fracture was fixed with intramedullary nail that was sent as anterograde from the processus olecrani, and the reduction of the radius head was easily placed. Then, it was repaired suturing with polypropylene of the ligamentum radii annulare. It was understood that the kitten could use the extremity smoothly and functionally in postoperative 2 months. Consequently, the internal fixation with intramedullary nail was sufficient, and therefore it was thought to be a successful method for type I Monteggia fracture in kittens or cats.

Key Words: Type I Monteggia fracture, Radius, Ulna, Intramedullary nail, Kitten.

Bir yavru kedide Tip I Monteggia kırığı; tanı ve tedavi yöntemleri

Öz

Bu olgu sunumunda yavru bir kedide karşılaşılan tip I Monteggia kırığı ve tedavi sonuçlarının bildirilmesi amaçlandı. Trafik kazasından sonra ön sol ekstremitesinde topallık şikayeti ile kliniğimize getirilen 4 aylık dişi bir kedi yavrusunun klinik muayenesinde radial başın kraniale dislokasyonu ile ulnanın 1/3 proksimalinde diafiz kırık belirlendi. Genel anestezi altında ulnar kırık processus olecraniden anteroograd olarak gönderilen intramedüller çivi ile fiks edildi ve radiusun redüksiyonu kolay bir şekilde gerçekleştirildi. Daha sonra ligamentum radii annulare polypropylene ile dikilerek onarıldı. Postoperatif 2. ay kontrollerinde kedinin ekstremitesini düzgün ve fonksiyonel bir şekilde kullanabildiği görüldü. Sonuç olarak kedi veya yavrularında Monteggia tip I kırıklarında intramedüller çivi ile sağlanan internal fiksasyonun yeterli olduğu ve bu yüzden başarılı bir yöntem olduğu düşünüldü.

Anahtar Kelimeler: Tip I Monteggia kırığı, Radius, Ulna, İntramedüller çivi, Yavru kedi

INTRODUCTION

Joint injuries, ligament lesions, joint dislocations, close-to-joint fractures and intraarticular fractures or fractures are among the traumatic lesions of radius ulna and elbow joint area (1,2). Lesions of elbow joints in cats and dogs are rare, but proximal diaphyseal fractures of ulna together with dislocation of caput radii can occur. This fracture-dislocated condition is specifically called as "Monteggia lesion" or "Monteggia fracture", and is categorized into 4 different types (3-7). Type-I is seen more often than other types, although Monteggia fracture is rarely seen in veterinary practice (3).

In this case report, it was aimed to report a type I Monteggia fracture in 1/3 proximal diaphyseal of ulna with cranial dislocation of the radial head in a kitten and its treatment results.

CASE HISTORY

A 4 month old female kitten was suffering from lameness in the front left leg after automobile trauma. Clinical and

Monteggia fracture with cranial dislocation of the radial head and 1/3 proximal diaphyseal ulnar fracture (Figure 1). On physical examination, there was painful moderate swelling around the left elbow with non-weight bearing lameness of the affected forelimb. In addition it was determined that there was absence of any signs of cardiovascular or respiratory distress based on clinical examination.

After clinical and radiological evaluations, case was defined as a closed type I Monteggia fracture and operation decision was taken.

Sefazolin sodium (20 mg/kg, iv, Cefazin®, Bilim İlaç, İstanbul Turkey), and methylprednisolone (0,5mg/kg, iv, Depo-Medrol®, İstanbul/Turkey) were administered in patient with trauma as previously defined (3). A 24-G polyurethane catheter (iv cannula, Bıçakçılar, İstanbul/Turkey) was aseptically inserted into the right ramus dorsalis of the vena saphena.

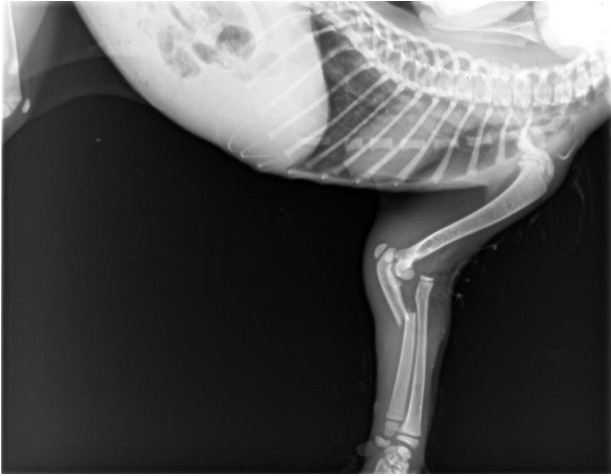


Figure 1. Lateral radiography of the elbow in a kitten: Fracture in 1/3 proximal diaphyseal of ulna and luxation to cranial of the radial head.

The kitten presented as a case was anesthetized with xlazine (0.15 mg/kg, iv, Alfazyme®, Atafen, İzmir, Turkey) and ketamine (15 mg/kg, iv, Ketazol®, Richter Pharma, Wels, Austria) following the shaving and operation preparation of the elbow joint and radius ulna area. The kitten was positioned in lateral recumbency. The operation region was restricted to sterile cover and an electrolyte solution (saline 0.9 percent, Poliflex®, Tekirdag, Turkey) was administered intravenously at 10 ml/kg/hour for operation duration. Then the ulnar fracture line was revealed by opening the skin and subcutaneous facial tissues. Ulnar fracture was fixed with intramedullary nail sent from the processus olecrani. After fixation, the reduction of the radial head was easily completed (Figure 2). The ligamentum radii annulare was repaired by suturing with 4/0 polypropylene. After repairing the ruptured ligament, joint reduction was achieved easily. But no surgical intervention was made in the joint capsule. The operation line was appropriately closed with separated suture techniques using 0 number silk thread. Bandage not was applied to the relevant extremity.

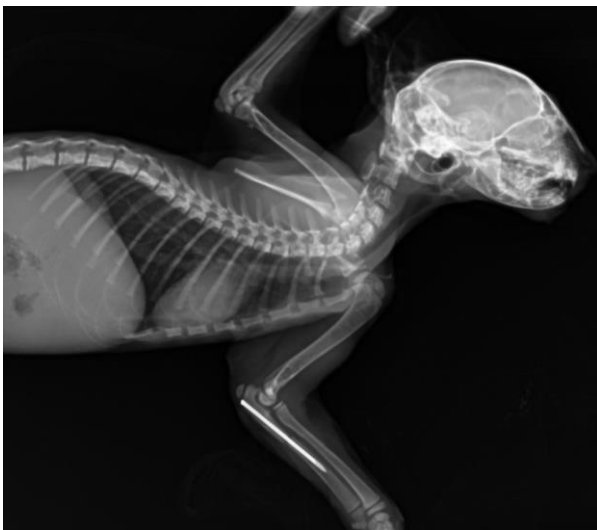

Figure 2: Postoperative lateral radiography: Type I Monteggia fracture with 1.2 mm intramedullary nail in ulna.

In the postoperative period, antibiotic therapy was continued for five days and ketoprofen (2 mg/kg, sc, Keto-

pet®, Teknovet, İstanbul, Turkey) as an analgesic was given for five days.

Based on follow-ups with the patient's owner via telephone, it was found that the kitten's condition was good during the postoperative 2 months. It was learned that the kitten could use the extremity smoothly and functionally.

DISCUSSION AND CONCLUSION

The luxation of caput radii and fracture of ulna named as "Monteggia fracture" is not a common lesion. In 1814, Monteggia fracture was first described by Giovanni Battista Monteggia. Then Bado classified Monteggia fracture into four types in 1967 (3-5) as follows.

Type I: Cranial radial head dislocation and ulnar diaphysis fracture with cranial angulation.

Type II: Caudal radial head dislocation and ulnar diaphysis fracture with cranial angulation

Type III: Lateral or craniolateral radial head dislocation and ulnar diaphysis fracture

Type IV: Cranial radial head dislocation associated with ulnar and radial diaphysis fracture.

Our case was defined as type I Monteggia fracture according to this classification. Because the fracture in 1/3 ulnar diaphysis with cranial angulation and cranial radial head dislocation is clearly visible on the radiography.

Monteggia fracture is not a common problem in veterinary surgery (5,6), but type I is more common than other types (3). Close reduction or external fixation is not recommended in the case of ulnar fracture and reduction of radial head (5,7). For open reduction and immobilization, it has been reported that one of the plate, screw or nail applications should be preferred (5-9). Reduction of the radial head can be maintained by repairing of lig. annulare radii using screws, nails or cerclage wires (7,8). In our case, ulnar fracture was fixed with intramedullary nail sent as anterograde from the processus olecrani. Although screw, plate and nail applications are recommended in adult cats and dogs, we preferred intramedullary nail application because the presented case was a kitten. Bone tissue trauma is involved during plate and screw application, which is considered inconvenient for a bone in the growth period. On the other hand, intramedullary nail application in young animals causes less tissue trauma and it provides convenience in terms of practical application.

Saglam and Bilgili (1997) (6) performed fixation with Kirschner wire in type II Monteggia fracture and then stabilized it by stapling with polypropylene for repairing of the ligamentum radii annulare in a cat. In this case, the ligamentum radii annulare was repaired by suturing with 4/0 polypropylene. It was understood that this technique was sufficient based on the postoperative follow-ups.

Bandage application is recommended for large bodied animals in the postoperative period (6,7,8). But we did not apply any bandages because the case was very young.

In our cases in the 60th day of the post-operation a complete functional healing was observed and complications such as nonunion, malunion, elbow joint lesion, redislocation, ankylosis and infection were not observed.

Consequently, intramedullary nail sent as anterograde from the processus olecrani for fixation of the ulnar fracture is sufficient. Additionally, prosthetic material instead of ligamentum radii annulare must be used, or the ligament must be repaired to avoid dislocation of radial head. It was enough to suture with polypropylene in kitten.

REFERENCES

1. Sardinas JC, Montavon PM, (1997). Use of medial bone plate for repair of radius and ulna fractures in dogs and cats: A report of 22 cases. *Vet Surg.* 26: 108-113.
2. Scott H, (2005). Repair of long bone fractures in cats. In *Pract.* 27: 390-397.
3. Irubetagoiena I, Lopez T, Autefage A, (2011). Type IV Monteggia fracture in a cat. *Vet Comp Orthop Traumatol.* 24: 483-486.
4. Bado JL, (1967). The Monteggia lesion. *Clin Orthop Relat Res.* 50: 71-86.
5. Saglam M, Bilgili H, Kürüm B, Candaş A, (2000). Treatment of ulnar fracture with dislocation of caput radii (Monteggia lesion) in 2 dogs and 3 cats. *Ankara Univ Vet Fak Derg.* 47: 73-80.
6. Saglam M, Bilgili H, (1997). Type II Monteggia lesion and operative treatment in a cat. *Ankara Univ Vet Fak Derg.* 44: 1-4.
7. Schwarz PD, Schradcr SC, (1984). Ulnar fracture and dislocation of the proximal radial epiphysis (Monteggia lesion) in the dog and cat: a review of 28 cases. *JAVMA.* 185: 190-194.
8. Leclerc A, Greunz EM, Lagrave AD, (2014). Surgical treatment of a type III Monteggia fracture in a ring-tailed lemur (*Lemur catta*). *Revue Med Vet.* 165 (11-12): 313-317.
9. Singh A, Moens NM, Nykamp S, Bruce CW, (2007). What is your diagnosis? Type 1 Monteggia fracture. *JAVMA.* 231: 1345-1346.

Corresponding author:

*Assoc. Dr. Sadık YAYLA

University of Kafkas, Faculty of Veterinary Medicine, Department of Surgery Kars, Turkey.

e mail: sadikyayla@gmail.com

Tel : 0474 242 68 36