

A case of multiple dental anomalies: a variant of Ekman-Westborg–Julin trait

Simultaneous occurrence of multiple dental anomalies is relatively common and has been reported particularly in cases with systemic alterations or syndromes. However, in 1974, Ekman-Westborg and Julin described a unique case of multiple macrodontia and multituberculism of posterior teeth accompanied by multiple dental malformations without other systemic anomalies. Here we report the case of a 20-year-old female patient who presented with macrodontia affecting her maxillary lateral teeth, mandibular incisors, and impacted multituberculated wisdom teeth accompanied by other dental anomalies that manifested itself as a variant of the Ekman-Westborg–Julin trait.

Keywords: *Multituberculism, macrodontia, dental anomaly, Ekman-Westborg–Julin, cone-beam computed tomography*

**Gizem Çolakoğlu¹,
Mağrur Kazak²,
Işıl Kaya Büyükbayram³,
Mehmet Ali Elçin¹,
Elçin Bedeloğlu⁴**

Introduction

Dental anomalies have been known to be congenital, developmental or acquired. They may be associated with defects in chromosomes or environmental factors (1). The occurrence of multiple dental anomalies is relatively common and have been reported especially in cases with other systemic alterations or syndromes. However, in 1974, Ekman-Westborg and Julin (2) described a unique case of multiple macrodontia and multituberculism of posterior teeth accompanied by multiple dental malformations without other systemic anomalies. Similar cases and their variants have been since reported in the literature (3-8). This condition is referred to as “Ekman Westborg-Julin Syndrome”, “Ekman Westborg-Julin Trait”, or “multiple macrodontic multituberculism” (3-9). The aim of this case report is to describe a 20-year-old female patient with multiple dental anomalies which appears to manifest itself as a variant of Ekman-Westborg-Julin trait.

Case report

A 20-year-old female patient was referred to the Clinic of Oral and Dentomaxillofacial Radiology Department in İstanbul Aydın University, İstanbul, Turkey, with the chief complaint of swelling in the left posterior mandible. A panoramic radiography was taken in order to evaluate the involved area. Clinical and radiographical examinations led to the diagnosis of pericoronitis of the mandibular left third molar.

During clinical examination, macrodontic maxillary laterals and mandibular incisors, as well as shovel-shaped maxillary incisors were observed. Also, enamel opacity on the right and left maxillary lateral incisors, and enamel hypoplasia on the left maxillary lateral incisor were noted. Carabelli tubercles on the right and left maxillary first molars, and extra palatal tubercles

¹Department of Oral and Dentomaxillofacial Radiology, İstanbul Aydın University, Faculty of Dentistry, İstanbul, Turkey

²Department of Restorative Dentistry, Bezmialem University, Faculty of Dentistry, İstanbul, Turkey

³Department of Endodontics, İstanbul Aydın University, Faculty of Dentistry, İstanbul, Turkey

⁴Department of Oral and Maxillofacial Surgery, İstanbul Aydın University, Faculty of Dentistry, İstanbul, Turkey

Presented at: This case has been presented as a poster at the 2nd International Congress the Oral Diagnosis and Maxillofacial Radiology Society, April 14th, 2017, Eskişehir, Turkey.

Corresponding Author: Gizem Çolakoğlu
E-mail: gizemcolakoglu@aydin.edu.tr

Received: 12 July 2017

Revised: 18 August 2017

Accepted: 21 September 2017

DOI: 10.26650/eor.2018.25807

on the right and left maxillary second molars were detected. The right and left maxillary second premolars had been extracted during previous orthodontic treatment (Figure 1a-c). Panoramic radiography showed macrodontic impacted third molars, root dilacerations on the right maxillary first premolar and left maxillary second molar (Figure 2a).

For further evaluation, informed consent was obtained from the patient and cone beam computed tomography (CBCT) (3D Accuitomo 170, J. Morita, Kyoto, Japan) was performed with 90 kV, 5 mA and 30.8 sec using 250 µm voxel size and 140x100 cm field of view (FOV). Axial, coronal, sagittal and cross-sectional images with 1 mm slice thickness and intervals were investigated by two oral and maxillofacial radiologists (GÇ, MAE). C-shaped large palatinal root canal in the right maxillary second molar, double palatinal rooted left maxillary second molar, pulp stone on the left maxillary lateral incisor, enameloma on the right and left maxillary second molars, dilaceration on the right maxillary first premolar and left maxillary second molar, macrodontic multituberculated impacted third molars were also detected during the investigation of the CBCT images (Figure 2b-f).

Her medical and family history were questioned in detail to find out the cause of these multiple dental anomalies. The medical history was non-contributory and the patient was mentally and physically healthy. She did not give permission to perform chromosomal analysis but she was the second child of healthy parents and no genetic disorders were found in her family history. She had been delivered by caesarean

section. Consanguinity was denied. Extra-oral examination did not show any abnormalities. Only a generalised birth mark in pink colour was detected extending from her first toe of the right foot to her right leg (Figure 1d-f).

The patient was referred to a medical physician in order to eliminate the possibility of systemic diseases. Biochemical tests, including complete blood count, thyroid hormone (triiodothyronine, free thyroxine, thyroid stimulating hormone), sex hormone (follicle stimulating hormone, luteinizing hormone, progesterone, prolactin) and growth hormone levels, diabetes tests (fasting blood sugar, oral glucose tolerance test) and routine blood tests were carried out and only folic acid and vitamin B₁₂ levels were found to be within the border limits.

Discussion

Ekman-Westborg and Julian (2) described multiple macrodontia and multituberculism affecting only the teeth with no other systemic anomalies. This condition has been referred to as Ekman Westborg-Julin Syndrome, Ekman-Westborg-Julin Trait and multiple macrodontic multituberculism in the literature (3-9). Because these multiple anomalies are unique to the teeth and it's not a syndrome, we preferred the term "Ekman-Westborg-Julin Trait" (6). So this case was considered to be a variant of the Ekman-Westborg-Julin Trait due to the presence of the dental morphological anomalies including macrodontia affecting maxillary laterals, mandibular incisors

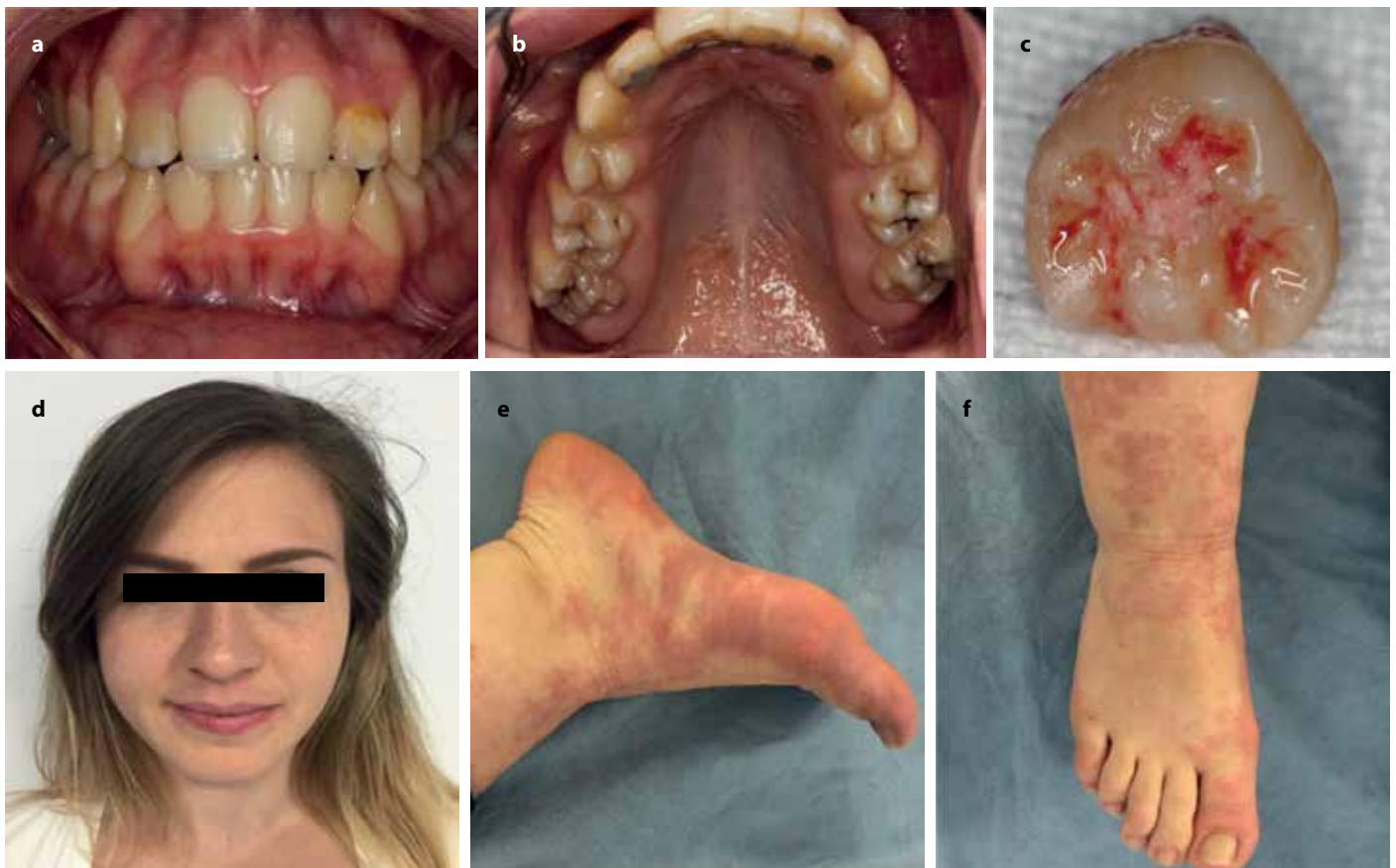

Figure 1. a-f. Intra-oral views of patient; (a) note the macrodontic teeth #12, #22, #32, #42, #31, #41, shovel-shaped teeth #11, #21, enamel opacity on tooth #12, enamel hypoplasia on tooth #22, (b) extra palatinal tubercles on teeth #17, #27, Carabelli tubercles on teeth #16, #26 and (c) extracted macrodontic multituberculated tooth #38. Extra-oral views of patient; (d) showing no abnormality and (e, f) Pink birth mark extending from her first toe of the right foot to her right leg.

and impacted wisdom teeth with multituberculism accompanying other dental anomalies.

Macrodonia, as one of the characteristic findings of the Ekman-Westborg-Julin trait, is an uncommon developmental anomaly in which the teeth appear larger compared to their normal sizes. Macrodonia more commonly involves a group of teeth or a single tooth, however rarely the entire dentition may be involved (1). Macrodonism has been reported to affect mostly the mandibular premolars, molars and rarely; the incisors (6). In our case, macrodonia was detected on the impacted third molars, maxillary laterals and mandibular incisors. Macrodonia is classified into three subgroups such as: true generalized, relatively generalized, and localized macrodonia of a single tooth. True generalized macrodonia may occur due to the systemic disorders (insulin-resistant diabetes, pituitary gigan-

tism) or syndromes (otodontal syndrome, facial hemihyperplasia, 47,XXY syndrome, oculo-facio-cardio-dental syndrome and postaxial polydactyly-dental-vertebral syndrome) (4). In order to eliminate these disorders, biochemical and routine blood tests were carried out in the present case and the patient was found to be systemically healthy. The chromosomal analysis could not be performed but detailed family history of the patient showed no genetic disorders. Although macrodonism may occur as an enlargement of all tooth structures, it may also be associated with other morphologic anomalies like multituberculism, schizodontia, invaginations and evaginations, and supernumerary teeth (2). Detailed radiographic examination (panoramic radiography and cone beam computed tomography) in this case revealed that the impacted macrodontic wisdom teeth showed multituberculism.

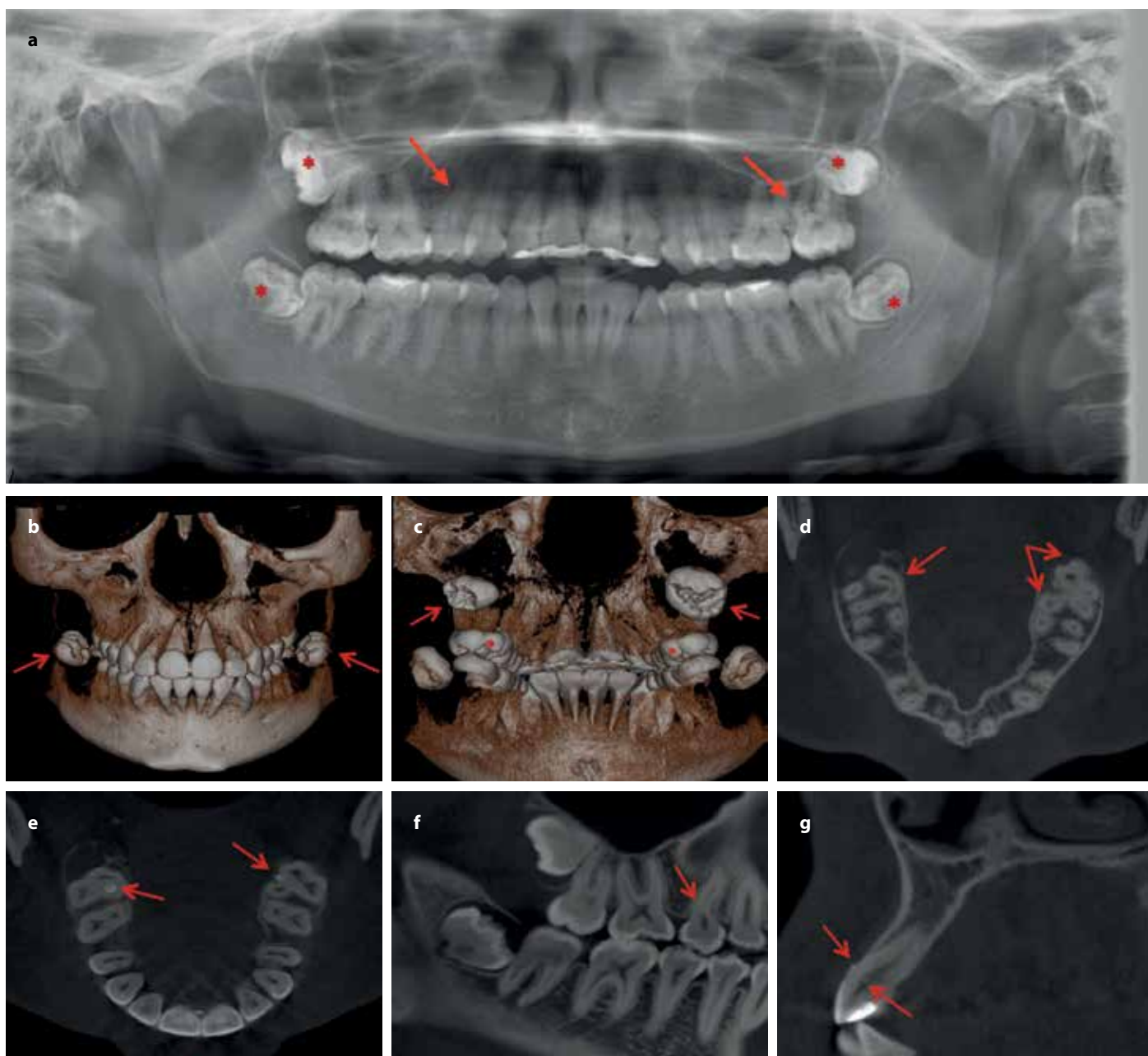


Figure 2. a-g. (a) Panoramic radiography showed macrodontic impacted third molars (red stars), root dilaceration on teeth #14, #27 (red arrows). CBCT images of the patient; 3D views of (b, c) Macrodonic multituberculated teeth #18, #28, #38, #48 (red arrows), (c) Extra palatal tubercles on teeth #17, #27 (red stars), Axial images showing (d) C-shaped large palatinal root canal of tooth #17, double palatinal rooted tooth #27, (e) Enameloma on teeth #17, #27 (red arrows), Sagittal images showing (f) Root dilaceration on tooth #14, (g) Dilaceration on cemento-enamel junction and pulp stone on tooth #22 (red arrows).

Malocclusion is a common finding in the reported cases related with Ekman-Westborg-Julian Syndrome (3-5, 7-9). The present case also had the history of orthodontic treatment and the right and left maxillary second premolars had been extracted according to the treatment plan.

The pathogenesis of this syndrome and the role of genetic factors (hereditary transmission) still remain unclear. Due to the limited number of cases reported it is not possible to elucidate the exact cause of this condition. Ekman-Westborg, Julian (2) predicted that the dental anomalies may be caused by a common pathogenetic factor during the early stage of tooth development, while the initiating factors remain obscure.

In the first reports of Ekman-Westborg-Julian Trait, there seemed to be a male predominance. Then, in 2003, Benjamin *et al.* (9) presented a 12-years-old female patient. Despite the limited number of cases, the male to female ratio is 7:5 which denotes almost no gender difference. Only in one case there was no information about gender (5).

In the literature, simultaneous occurrence of multiple dental anomalies in a single case without systemic disorders has also been reported apart from the cases which were thought to be Ekman-Westborg-Julian syndrome or a variant of this syndrome (10). The common feature of all these reports is that they present non-syndromic patients and/or those without non-systemic disorders with multiple dental anomalies. Besides, these patients are mostly young adults, as in the present case who is 20 years old. This may be related to the early recognition of dental and orthodontic problems.

Three dimensional imaging may be considered as a viable option for advanced imaging in cases with multiple dental anomalies. In the present case, CBCT was used to determine the exact morphology of macrodontic impacted third molar teeth. CBCT images revealed many other dental anomalies which were not mentioned in previous reports, such as pulp stones, enameloma, dilaceration and double rooted maxillary second molar accompanied with multituberculated macrodontic third molars. CBCT was first introduced in dentistry in the late 1990's and have been widely used in all fields of dentistry allowing the 3-dimensional and natural visualization of anatomical and pathological structures with the advantages of short acquisition time, low cost and especially low radiation dose compared with the computed tomography scanning (1).

Conclusion

Presence of multiple dental anomalies as a variant Ekman-Westborg and Julian trait is a rare occurrence. Definitive diagnosis and treatment procedures necessitate close cooperation among dental and medical professionals. Patients must be referred to medical physicians in order to exclude systemic and/or genetic disorders. CBCT can provide additional information that may be of clinical significance.

Ethics Committee Approval: Not required.

Informed Consent: Patient provided written informed consent.

Peer-review: Externally peer-reviewed.

Author Contributions: GÇ, MK, IKB, and MAE designed the study. GÇ, IKB and EB generated the data. GÇ, MK and EB gathered the data. GÇ, MK and MAE analyzed the data. GÇ wrote the majority of the original draft. All authors approved the final version of paper.

Conflict of Interest: No conflict of interest was declared by the authors.

Financial Disclosure: The authors declared that this study has received no financial support.

Türkçe öz: *Multiple Dental Anomaliler: Ekman-Westborg-Julian Trait'inin Varyasyonu. Multiple dental anomalinin bir arada görülmesi oldukça yaygındır ve özellikle sistemik hastalıklar ya da sendromlar ile birlikte rapor edilmiştir. Ancak 1974'te Ekman-Westborg ve Julian, sistemik bir anomalili olmaksızın birçok makrodonetik dişler ile multitüberküliizmlü posterior dişlere aynı anda başka dental malformasyonların eşlik ettiği bir olgu tanımlamışlardır. Bu makalede, 20 yaşındaki kadın hastada, makrodonetik maksiller lateral ve mandibular keser dişler ile multitüberküliizmlü gömülü yirmi yaş dişlerine diğer dental anomalilerin eşlik ettiği, Ekman-Westborg-Julian Trait'inin bir varyasyonu olduğu düşünülen bir olgu sunulmuştur. Anahtar kelimeler: Multitüberküliizm, makrodonetik, dental anomalili, ekman-westborg-julin, konik ışınli bilgisayarlı tomografi.*

References

1. White SC PM. Oral radiology, principles and interpretation. St. Louis: Mosby, 2004, 334-335.
2. Ekman-Westborg B, Julin P. Multiple anomalies in dental morphology: Macrodonetia, multituberculism, central cusps, and pulp invaginations. Report of a case. Oral Surg Oral Med Oral Pathol 1974; 38: 217-22. [CrossRef]
3. Guvenc D, Gokbuget AY, Cintan S, Seymen F. A variant of the ekman-westborg and julin trait. Int J Oral Maxillofac Surg 2012; 41: 42-5. [CrossRef]
4. Komatsu T, Kurihara T, Ito Y, Lee MC, Miyagi A, Ikeda M. Oral characteristics of a patient with ekman-westborg-julin trait: A case history. Spec Care Dentist 2012; 32: 70-4. [CrossRef]
5. Nakajima J. NH, Higuchi K., Takano Y., Sato Y. A variant of the ekman-westborg-julin trait. A case report and review of the literature. J Oral Maxillofac Surg Med Pathol 2016; 28: 30-5. [CrossRef]
6. Nemes JA, Alberth M. The ekman-westborg and julin trait: Report of a case. Oral Surg Oral Med Oral Pathol Oral Radiol Endod 2006; 102: 659-62. [CrossRef]
7. Peker I, Kayaoglu G. A case of ekman-westborg-julin trait: Endodontic treatment of a macrodonetic incisor. Oral Surg Oral Med Oral Pathol Oral Radiol Endod 2009; 107: e89-92. [CrossRef]
8. Ritzau M, Carlsen O, Kreiborg S, Brinch-Iversen J, Gorlin RJ, Rasmussen NH. The ekman-westborg-julin syndrome: Report of case. Oral Surg Oral Med Oral Pathol Oral Radiol Endod 1997; 84: 293-6. [CrossRef]
9. Benjamin MR, Rodrigo FS, Gorlin RJ. Multiple macrodonetic multituberculism. Am J Med Genet A 2003; 120A: 283-5. [CrossRef]
10. Patil S, Yadav N, Patil P. Non-syndromic occurrence of multiple dental and skeletal anomalies: A rare case report and brief literature review. J Clin Diagn Res 2014; 8: ZD28-30.