

Hand enchondromas treated with injectable calcium phosphate cement

Enjekte edilebilir kalsiyum fosfat çimentosu ile tedavi edilen el enkondromları

Ali Çağdaş Yörükoğlu, Alp Akman, Ali Kitiş, Hande Usta, Ahmet Fahir Demirkan

Gönderilme tarihi:17.11.2018

Kabul tarihi:10.12.2018

Abstract

Purpose: The purpose of this study was to evaluate the results of hand enchondroma patients treated by curettage and then filling of the defect with injectable calcium phosphate cement.

Material and methods: 16 patients were included in this retrospective study. The radiological, clinical (pain intensity, range of motion) and functional outcomes (Quick-DASH, grip and pinch strengths) were evaluated.

Results: There was a significant reduction in mean pain scores post operatively. All patients had full range of motion except 1 patient. New bone formation occurred in seven patients. Ectopic ossification, wound infection and recurrence were not observed in any patient. The mean Quick-DASH score was 7.3 ± 11.9 postoperatively. 90% recovery of grip strength and 85-100% of pinch strength were obtained.

Conclusion: Calcium phosphate cement is anticipated as a valuable alternative treatment method of hand enchondromas because of the lack of donor site morbidity, allowing early activity and providing good functional results.

Key Words: Calcium phosphate cement, hand enchondroma, benign tumors.

Yorukoglu AC, Akman A, Kitiş A, Usta H, Demirkan AF. Hand enchondromas treated with injectable calcium phosphate cement. Pam Med J 2019;12:115-121.

Özet

Amaç: Bu çalışmanın amacı el enkondromlarının küretajı ve defektin enjekte edilebilir kalsiyum fosfat çimentosu ile tedavi sonuçlarının değerlendirilmesidir.

Gereç ve yöntem: Bu retrospektif çalışmaya 16 hasta dahil edilmiştir. Radyolojik, klinik (ağrı değerleri, eklem hareket açıklıkları) ve fonksiyonel sonuçları (Quick-DASH skorları, kaba ve ince kavrama güçleri) değerlendirilmiştir.

Bulgular: Operasyon sonrası hastaların ortalama ağrı skorlarında anlamlı bir azalma saptandı. Bir hasta haricinde tüm hastaların tam eklem hareket açıklığına sahip olduğu saptandı. Yedi hastada yeni kemik oluşumu meydana geldi. Hiçbir hastada ektopik kemikleşme, yara yeri enfeksiyonu ve nüks gözlenmedi. Postoperatif ortalama Quick-DASH skoru $7,3 \pm 11,9$ idi. Sağlam ekstremiteler ile karşılaştırıldığında kaba kavrama gücünün %90'ının ve pinç kuvvetinin %85-100'ünün geri kazanıldığı saptandı.

Sonuç: Kalsiyum fosfat çimentosu donör alan morbiditesinin olmaması, erken aktiviteye izin vermesi ve iyi fonksiyonel sonuçlar ile el enkondromlarının tedavisinde değerli bir tedavi alternatifi olduğu düşünülmektedir.

Anahtar Kelimeler: Kalsiyum fosfat çimentosu, el enkondromları, iyi huylu tümör.

Yörükoğlu AÇ, Akman A, Kitiş A, Usta H, Demirkan AF. Enjekte edilebilir kalsiyum fosfat çimentosu ile tedavi edilen el enkondromları. Pam Tıp Derg 2019;12:115-121.

Ali Cagdas Yorukoglu, Assistant Professor, Pamukkale University, Faculty of Medicine, Department of Orthopedics and Traumatology. DENİZLİ, e-posta:alicagdasyorukoglu@gmail.com (orcid.org/0000-0001-8903-3578) (Sorumlu yazar)

Alp Akman, Assistant Professor. Pamukkale University, Faculty of Medicine, Department of Orthopedics and Traumatology. DENİZLİ, e-posta:alpakman@gmail.com (orcid.org/0000-0001-7830-1979)

Ali Kitiş, Professor. Pamukkale University, School of Physical Therapy and Rehabilitation. DENİZLİ, e-posta:alikitish@pau.edu.tr (orcid.org/0000-0002-6827-1398)

Hande Usta, MSc. Pamukkale University, School of Physical Therapy and Rehabilitation. DENİZLİ, e-posta:hande_st@hotmail.com (orcid.org/000-0002-0935-1849)

Ahmet Fahir Demirkan, Professor, Pamukkale University, Faculty of Medicine, Department of Orthopedics and Traumatology. DENİZLİ, e-posta:fahirdemirkan@yahoo.com (orcid.org/0000-0002-1393-7068)

Introduction

Enchondromas are benign tumors. The small bones of the hand are the most commonly affected with a rate of 40%. It has a low risk of sarcomatous degeneration. Enchondromas may be diagnosed incidentally, as well as patients may also suffer from fracture or deformity [1]. Curettage of the lesion is the most accepted surgical treatment of enchondromas of the hand [2]. Although all treatments give satisfactory results, there has been some debate about the optimal treatment of enchondromas. Some authors recommend leaving the defect empty, while others suggest using bone grafts [1-3]. Auto grafting is accepted as the gold standard in the treatment, however it has some disadvantages such as; donor site morbidity and loss of mechanical strength of bone and the need for long-term immobilization [4].

Bone substitutes like calcium phosphate (Ca-P) cement has become popular for filling bone cavities in recent years. It seems to be advantageous as it does not cause donor site morbidity, avoid the risk of disease transmission and increase mechanical strength with the full filling of the cavity. In the literature, two studies with few patients with Ca-P cement have been found, and good clinical results with Ca-P application have been reported [1, 5].

The aim of this study is to evaluate the results of a clinical series of sixteen hand enchondroma patients treated by curettage and then filling of the defect with injectable Ca-P cement.

Materials and methods

This retrospective study was approved by Non Interventional Clinical Research Ethics Committee meeting and numbered 60116787-20/32204. Written informed consent were obtained from patients. Inclusion criteria were: a) Lesions at metacarpal and phalangeal bones, b) Over 18 years of age. Exclusion criteria were: a) Ollier's disease, b) Hand deformity or previous injury, c) Fractures involving the joint and joint destruction due to the lesion. 16 patients (11 female, 5 male) were included in this retrospective study between March 2006 and October 2015.

Surgical procedure

Following the exposure of the affected

bone, an oval small window was opened and the cavity walls were curetted and contents were evacuated. Ca-P cement (Axoz[®],Kyeron) consists of tricalciumphosphate was injected into the cavity. The application was done by paying attention not to allow over flowing of Ca-P cement out of the cavity. Residual cement pieces were cleaned with saline solution. After reduction of the thin cortex of the bone, no splint or internal fixation was applied. Surgical interventions were performed by the same surgeon.

After treatment

Hand therapy were started on the first postoperative day and patients were called up once a week for follow-up appointments. Early pain and edema control, early active movement was provided for wrist and finger joints. Then, the patients were encouraged to participate activities of daily living and gradually strengthening at long term.

Radiological evaluation

Enchondromas of the hand were evaluated by anteroposterior and lateral radiographs. Bone incorporation (no change of radiographic appearance and no gap formation between bone and Ca-P cement) and absorption (replacement by new bone) of Ca-P cement on serial radiographs were evaluated as Yasuda et al [5] described before. The enchondromas of all patients were classified as central, eccentric, associated, polycentric, giant according to Tagikawa classification [6] with direct graphs (Table 1).

Functional evaluation

Pain intensity was assessed by Visual Analog Scale (VAS). Range of Motion assessment (ROM) was done using universal goniometer with calculating Total Active Motion (TAM) formula. Functional status of the upper extremity was assessed with Turkish version of Quick-DASH (Q-DASH) containing subjective data.

The hand grip and pinch (tip to tip, pulp to pulp, key and third pulp to pulp) strengths were measured according to a standardized protocol respectively using a hand dynamometer and a pinchmeter (Baseline[®] Evaluation Instruments, 7-piece Hand Evaluation Set, 12-0100).

Table 1. Demographics of the patients

Patient No	Gender	Age	Affected Side/Bone	Extremity Dominancy	Tagigawa Classification	Size (Length-Width) (Mm)	Follow Up (Month)	Pathologic Fracture	New bone formation
1	F	50	L/1. Metacarp	R	Giant	23x9	12	No	No
2	F	59	R/3. Metacarp	R	Giant	57x14	12	No	No
3	M	18	L/2. Proximal phalanx	R	Eccentric	18x10	16	Yes	Yes
4	F	38	L/4. Proximal phalanx	R	Giant	20x15	20	No	Yes
5	M	20	L/4. Distal phalanx	L	Giant	11x9	18	Yes	Yes
6	F	50	R/1. Proximal phalanx	L	Eccentric	16x7	24	No	No
7	F	40	R/3. Distal phalanx	R	Giant	10x17	33	Yes	No
8*	M	35	R/4. Proximal phalanx	R	Giant	18x13	47	Yes	Yes
9	F	56	R/5. Metacarp	R	Giant	51x22	40	Yes	No
10	F	37	L/1. Distal phalanx	R	Giant	18x10	41	No	Yes
11	F	38	R/3. Proximal phalanx	R	Giant	48x12	35	No	No
12	F	32	L/5. Proximal phalanx	R	Giant	17x15	38	Yes	Yes
13	M	63	L/5. Metacarp	R	Giant	18x12	36	Yes	No
14	F	29	L/4. Distal phalanx	R	Central	16x7	48	No	No
15	M	18	R/2. Proximal phalanx	R	Giant	32x22	50	No	No
16	F	50	L/3. Mid phalanx	R	Giant	21x15	52	No	Yes

(F: Female M: Male R: Right L: Left) * Patient who went secondary operation

Pain was assessed both preoperative and postoperative; ROM, Q-DASH, grip and pinch strengths were evaluated in long-term follow-up control.

Statistical analysis

Data were analyzed using the IBM SPSS statistics 21.0 US. Descriptive statistics (mean and standard deviation) were used to describe characteristics of enchondromas of the hand. Test for normality was performed for the data. Parametric or nonparametric tests were chosen according to the normal distribution. Statistical significance level was accepted as $p < 0.05$ in all data.

Results

The demographic data of the patients included in the study were given in Table 1. Mean age of the patients were 38.4 ± 14.6 (range 18 to 63) years. The mean follow up time was 32.8 ± 14.01 (range 12-52) months. Four of the patients, included in the study had enchondromas in the metacarpal bones, seven in the proximal phalanx, one in the middle and four in the distal phalanx. According to the Tagikawa classification, 13 patients had giant, two eccentric and one had central enchondromas. Seven of the patients were

admitted due to pathologic fractures, four of them have swollen fingers and five of them were found incidentally.

New bone formation occurred in seven patients. New bone formation time was seen 14.1 ± 5.7 months (range between 7-24) in patients with cement absorption (Figure 1 and Figure 2). In one patient with fracture, due to the formation of deformity, osteotomy and fixation was performed after cement absorption. Ectopic ossification, wound infection and recurrence of the lesion were not encountered in any patient.

The mean pain score (out of 10) significantly decreased from 5.56 ± 2.85 (0-8) preoperatively to 0.62 ± 1.02 (0-4) ($p = 0.001$), Wilcoxon Signed Ranks Test). According to the Strickland classification, 15 patients out of 16 were excellent and one patient with deformity had poor results. The mean Q-DASH score was (out of 100) 7.3 ± 11.9 (0-50) after treatment. Average return to work and daily activities of the patients were 4 weeks. When the patients' grip and pinch strengths were compared with the contralateral extremity, 90% recovery of grip strength and 85-100% of pinch strength were obtained. Grip and pinch strengths of the affected extremity were not found to be significantly different when compared to the contralateral extremity except lateral pinch (Table 2).

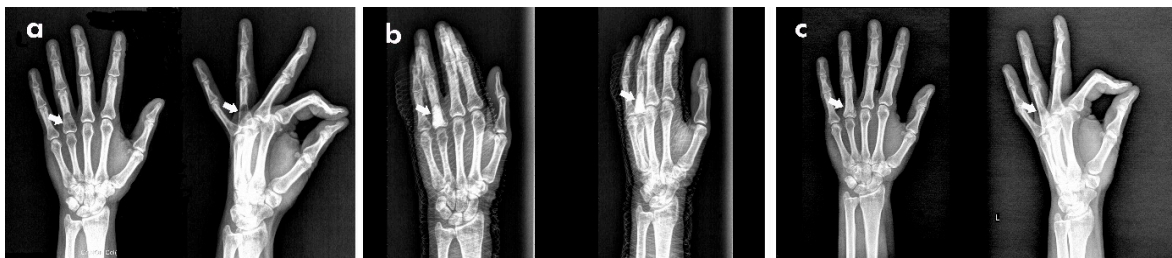

Figure 1a) A 38 years old woman enchondroma on the fourth proximal phalanx **1b)** Ca-P cemented postoperative graphics **1c)** 15th month graphics after treatment; the cement is completely resorbed and new bone formation occurred.

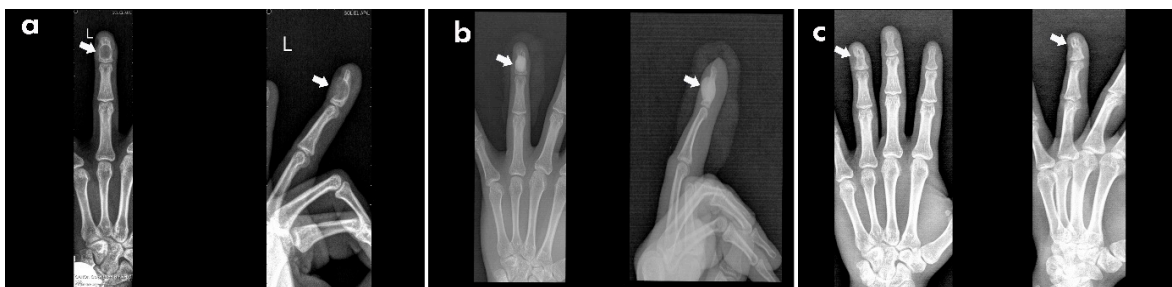


Figure 2a) A 20 years old man enchondroma on the fourth distal phalanx **2b)** Ca-P cemented postoperative graphics **2c)** 8th month graphics; the cement is completely resorbed and new bone formation occurred.

Table 2. Grip and pinch strength results of the patients

Variables (n=16)	Affected hand \bar{x} (SD)	Nonaffected hand \bar{x} (SD)	<i>p</i>
Grip strength	24.55 (8.45)	26.89 (10.51)	0.09*
Tip to tip pinch	2.20 (1.13)	2.18 (0.99)	0.89*
Pulp to pulp pinch	2.88 (1.51)	2.96 (1.32)	0.75*
Lateral pinch	4.96 (1.95)	5.88 (2.60)	0.01*
Third pulp to pulp	1.96 (0.97)	2.28 (0.67)	0.11*
Affected pulp to pulp	1.83 (1.39)	2.05 (1.01)	0.38*

* Paired Sample T Test

Discussion

Hand enchondromas can be detected by chance or by fracture or deformity. The most widely accepted surgical treatment is open or endoscopic curettage of the lesion [7]. Although the second step is contradictive, some authors suggest that to leave the lesion empty [8]. Some suggest curettage and cancellous autograft application, while others suggest the use of injectable or paste-like bone substitutes such as Ca-P [5, 9].

It is believed that filling the tumor cavity with cement increases the mechanical stability. Ca-P is an injectable bone graft and is used in orthopedics in various fields thanks to its good osteoconductive biological properties [3, 5, 10]. After curettage of the lesion, the cavity can be filled without leaving any space because it is easily moldable as well as providing mechanical strength.

A biomechanical analysis study was emphasized that Ca-P application was more advantageous than other grafting techniques [11]. Some authors have reported that autogenic or allogenic cancellous bone grafting techniques prolong recovery time causing joint stiffness. Recurrence, cavity formation and donor site morbidity are reported as disadvantages of bone grafting techniques [12-14]. Besides autograft and allograft, polymethyl methacrylate (PMMA) was also used to fill the cysts. It has been reported that early functional results are obtained by providing early movement in 13 enchondromas patients filled with PMMA after curettage and cemented internal fixation [2]. Crawford et al. [15] reported that Ca-P is more advantageous and stronger than PMMA due to the fact that its osteoconductive properties and not to causing thermal necrosis. At the same time, the cyst can be re-emptied in case

of infection and debrideable properties makes the use of Ca-P cement instead of PMMA more suitable.

Ca-P cement is resorbed in a few months or years. After resorption, it is replaced with normal bone trabeculae. This internal remodeling evidence due to the secretion of alkaline components, which are sensitive to tumor tissues while resorption, is thought to inhibit recurrence [16]. In a series of 10 patients treated with Ca-P, it has reported that the cement was resorbed within 4, 5 months except 2 patients [5].

Also, cementous overflowing is one of the important complication of the treatment of hand enchondromas with Ca-P that should be avoided because of the formation of an inflammatory condition, which leads to tendon adhesions and poor functional outcomes [1, 17]. In this study, 15 of 16 patients healed without any complication, the cement was absorbed in 7 patients and incorporated in 9 patients. No recurrence, infection, iatrogenic fracture was encountered in any of the patients. Soft tissue complication due to cementum overflow during cyst filling was not observed due to abundant washing during surgery. On control radiographs, it was seen that the cement completely filled the cyst.

Many studies on enchondromas have reported that the pain is reduced or absent [1, 18, 19]. In a study using bone graft substitute, Liodaki et al. [18] reported minimal pain intensity at postoperative 2 months. In 8 patients treated with Ca-P cementum, the pain score was reported to decrease pre-operative 4.1 to postoperative 1.6 [1]. In this study, a decrease in pain severity was observed in accordance with the literature.

Generally, assessment of the ROM was performed with total active motion formula in the literature. There are studies which full ROM is provided or loss of extension is reported. Hung et al. reported limitations and loss of extension in 4 patients [20]. Rajeh et al. [1] reported that ROM in operated hand had reached 89.3% of the contralateral hand. Kim and Kim [3] have provided excellent results in 10 patients series. In this study, excellent results were achieved except one patient who had complication.

In the literature, postoperative Q-DASH scores were reported as low [1]. In a study comparing autologous bone graft and artificial bone substitute groups, the Q-DASH scores were reported respectively as 5.1 and 2.3 [19]. In this study, similar to other studies or even lower Q-DASH scores were presented with higher levels of activity participation.

Limitations have been reported in the literature regarding the return to work [16]. It is necessary to evaluate the return to work and activities of daily living as an integral part of functional recovery. Consistent with this study, Yasuda and Bickels et al. [2, 5] reported return to functional activity as 4 weeks.

Grip and pinch strength recovery are valuable both in terms of functional use of the hand in daily activities of life and patient satisfaction. To our knowledge, there were only three studies of hand enchondroma in which different treatments were applied and grip strength results were obtained [4, 21, 22]. Figl and Leixnering [4] reported that after surgical treatment of patients with carpal and hand enchondroma, grip strength reached 80% of the healthy extremity. In this study, the results of grip and pinch strength of hand enchondroma patients treated with Ca-P cement are presented.

In a systematic review conducted in 2015, it has been reported that different cavitation management techniques did not differ from each other and functional results depend on surgical dissection and rehabilitation [23]. We also think that early hand therapy provided lower pain scores, increased ROM, excellent functional outcomes and early return to work in this study.

The limitations of this study are being retrospective and although the small number of patients. Future studies may be planned in the

form of prospective, standard follow-up times and which the Ca-P and other methods are compared included hand function tested.

In conclusion, calcium phosphate cement is anticipated as a valuable alternative treatment method of hand enchondromas because of the lack of donor site morbidity, allowing early activity and providing good functional results.

Conflict of Interest: The authors declared that there is no conflict of interest.

References

1. Rajeh M A, Diaz JJ, Facca S, Matheron AS, Gouzou S, Liverneaux P. Treatment of hand enchondroma with injectable calcium phosphate cement: a series of eight cases. *Eur J Orthop Surg Traumatol* 2017;27:251-254. doi: 10.1007/s00590-016-1888-2
2. Bickels J, Wittig JC, Kollender Y, et al. Enchondromas of the hand: Treatment with curettage and cemented internal fixation. *J Hand Surg Am* 2002;27:870-875.
3. Kim JK, Kim NK. Curettage and calcium phosphate bone cement injection for the treatment of enchondroma of the finger. *Hand Surg* 2012;17:65-70.
4. Figl M, Leixnering M. Retrospective review of outcome after surgical treatment of enchondromas in the hand. *Arch Orthop Trauma Surg* 2009;129:729-734. doi: 10.1007/s00402-008-0715-65
5. Yasuda M, Masada K, Takeuchi E. Treatment of enchondroma of the hand with injectable calcium phosphate bone cement. *J Hand Surg Am* 2006;31:98-102
6. Takigawa K. Chondroma of the bones of the hand. A review of 110 cases. *J Bone Joint Surg Am* 1971;58:1591-1600.
7. Taleb C, Gouzou S, Mantovani G, Liverneaux P. Treatment of benign bone tumours of the hand using osteoscopy. *Chir Main* 2010;29:78-81. doi: 10.1016/j.main.2009.12.001
8. Yanagawa T, Watanabe H, Shinozaki T, Takagishi K. Curettage of benign bone tumors without grafts gives sufficient bone strength. *Acta Orthop* 2009;80:9-13. doi: 10.1080/17453670902804604
9. Ablove RH, Moy OJ, Peimer CA, Wheeler DR. Early versus delayed treatment of enchondroma. *Am J Orthop (Belle Mead, NJ)*. 2000;29:771-772.
10. Wulle C. On the treatment of enchondroma. *J Hand Surg Am* 1990;15:320-330.
11. Pianta TJ, Baldwin PS, Obopilwe E, Mazzocca AD, Rodner CM, Silverstein EA. A biomechanical analysis of treatment options for enchondromas of the hand. *Hand (N Y)*. 2013;8:86-91. doi: 10.1007/s11552-012-9476-3

12. Sassoon AA, Fitz-Gibbon PD, Harmsen WS, Moran SL. Enchondromas of the hand: Factors affecting recurrence, healing, motion, and malignant transformation. *J Hand Surg Am* 2012;37:1229-1234. doi:10.1016/j.jhsa.2012.03.019
13. Yercan H, Ozalp T, Coşkunol E, Ozdemir O. Long-term results of autograft and allograft applications in hand enchondromas]. *Acta Orthop Traumatol Turc* 2004;38:337-342.
14. Bauer RD, Lewis MM, Posner MA. Treatment of enchondromas of the hand with allograft bone. *J Hand Surg Am* 1988;13:908-916.
15. Crawford K, Berrey BH, Pierce WA, Welch RD. In Vitro strength comparison of hydroxyapatite cement and polymethylmethacrylate in subchondral defects in caprine femora. *J Orthop Res* 1998;16:715-719
16. Liverneaux P. Treatment of bony fibrous dysplasia with calcium-phosphate cement: a case report. *Rev Chir Orthop Reparatrice Appar Mot* 2003;89:532-536.
17. Welkerling H, Raith J, Kastner N, Marschall C, Windhager R. Painful soft-tissue reaction to injectable Norian SRS calcium phosphate cement after curettage of enchondromas. *J Bone Joint Surg Br* 2003;85:238-239.
18. Liodaki E, Kraemer R, Mailaender P, Stang F. The Use of Bone Graft Substitute in Hand Surgery: A Prospective Observational Study. *Medicine*. 2016;95:e3631. doi: 10.1097/MD.0000000000003631
19. Decramer A, Leclercq C. Treatment of a fractured juxta-articular enchondroma of the middle phalanx with a Suzuki external fixator: a case report. *Tech Hand Up Extrem Surg*. 2015;19:46-49. doi:10.1097/BTH.0000000000000074
20. Hung YW, Ko WS, Liu WH, et al. Local review of treatment of hand enchondroma (artificial bone substitute versus autologous bone graft) in a tertiary referral centre: 13 years' experience. *Hong Kong Med J*. 2015;21:217-223. doi: 10.12809/hkmj144325
21. Giles DW, Miller SJ, Rayan GM. Adjunctive treatment of enchondromas with CO2 laser. *Lasers Surg Med* 1999;24:187-193.
22. Cha SM, Shin HD, Kim KC, Park IY. Extensive curettage using a high-speed burr versus dehydrated alcohol instillation for the treatment of enchondroma of the hand. *J Hand Surg Eur Vol* 2015;40:384-391. doi: 10.1177/1753193413517204
23. Bachoura A, Rice IS, Lubahn AR, Lubahn JD. The surgical management of hand enchondroma without postcurettage void augmentation: authors' experience and a systematic review. *Hand(N Y)* 2015;10:461-471. doi: 10.1007/s11552-015-9738-y

06-09 Mayıs 2018 tarihinde 16.Ulusal Türk El ve Üst Ekstremitte Cerrahisi Kongresinde sözlü bildiri olarak sunulmuştur.