

Small bowel obstruction secondary to an adhesion between ovary and small intestine loops: Case report

Ovaryan ve ince bağırsak iltihabı arasındaki yapışmaya bağlı ince bağırsak tıkanıklığı: Olgu sunumu

Houssam Belghali¹, Younes Hamdouni¹, Karim Ibn Majdoub Hassani¹, Imane Toughrai¹, Khalid Mazaz¹

¹ Visceral Surgery Service, Hassan II University Hospital, Faculty of Medicine and Pharmacy of Fez, Sidi Mohammed Ben Abdallah University, Fez, Morocco

ORCID ID of the authors
HB: 0000-0002-6734-2094
YH: 0000-0002-8037-8542
KIMH: 0000-0002-0421-7296
IT: 0000-0003-0401-3012
KM: 0000-0001-7779-7802

Abstract

Adhesion-related small bowel obstruction is a common pathology in visceral surgery. Postoperative adhesion is the most common etiology of acute intestinal occlusion. We report the case of an intestinal occlusion caused by an adhesion between the ovary and the small bowel loops. In order to share the epidemiological, clinical, prognostic and therapeutic aspects of this affection, and also the unusual localization of the adhesion, this is described in our case report. Computed tomography has improved the diagnosis of adhesive small bowel obstruction and its findings in bowel ischemia are helpful to guide the therapeutic attitude. The treatment was surgical and the postoperative course was simple.

Keywords: Obstruction, Small bowel, Adhesion

Öz

Adezyon ile ilişkili ince bağırsak tıkanıklığı, visseral cerrahide bir komatolojik patolojidir. Postoperatif yapışıklıklar, akut bağırsak tıkanıklığının en sık etyolojisidir. Bu durumu Epidemiyolojik, klinik, prognostik ve terapötik yönlerini paylaşmak için, ovaryan ve ince bağırsak ilmekleri arasındaki bir yapışma sonucu oluşan bir bağırsak tıkanıklığı olgusunu ve aynı zamanda, adezyonun alışılmadık lokalizasyonunu da olması sebebiye bildiririz. Bilgisayarlı tomografi yapıştırıcı ince bağırsak tıkanıklığı teşhisinde faydalıdır, ve bağırsak iskemisindeki bulguları, terapötik tutumu yönlendirmek için yararlıdır. Tedavisi cerrahi olup, hastanın postoperatif dönemi problemsiz idi.

Anahtar kelimeler: Obstrüksiyon, İnce bağırsak, Adezyon

Introduction

Adhesive occlusion has been reported as a common cause of hospitalization in gastrointestinal surgery [1]. It is the first etiology of acute intestinal obstruction, either by strangulation or compression or both. They can occur at any time during the life of operated patients. However spontaneous adhesions with no history of abdominal surgery are rare, but possible. It is a diagnostic and therapeutic emergency, the severity of occlusion is an important factor that affect the management of adhesive small bowel obstruction and which must be estimated to choose the appropriate treatment, which can be surgical or conservative. In patients without signs of severity, medical treatment finds its justification. However, it carries a risk of intestinal necrosis, requiring resection associated with a significant increase in mortality and morbidity.

Case presentation

A 32-year-old women, who had underwent a caesarean section 15 months ago, reoperated 2 weeks later for an undocumented gynecological problem. She was admitted to our hospital for with a three-day history of abdominal pain, retention of gas and stool and bilious vomiting. On physical examination, she was conscious, hemodynamically and respiratory stable, with a heart rate of 105 beats/min, and afebrile. Physical examination also revealed the presence of a pfannenstiel and midline abdominal scars, and a mild abdominal distension associated with tympany. The rest of the somatic examination did not reveal any pathological findings.

Corresponding author / Sorumlu yazar:
Houssam Belghali

Address / Adres: Visceral Surgery Service,
Hassan II University Hospital, Faculty of
Medicine and Pharmacy of Fez, Sidi Mohammed
Ben Abdallah University, Fez, Morocco
e-Mail: hbelghali10@gmail.com

Informed Consent: The author stated that the
written consent was obtained from the patient
presented in the study.

Hasta Onamı: Yazar çalışmada sunulan hastadan
yazılı onam alındığını ifade etmiştir.

Conflict of Interest: No conflict of interest was
declared by the authors.

Çıkar Çatışması: Yazarlar çıkar çatışması
bildirmemişlerdir.

Financial Disclosure: The authors declared that
this study has received no financial support.
Finansal Destek: Yazarlar bu çalışma için finansal
destek almadıklarını beyan etmişlerdir.

Received / Geliş tarihi: 21.09.2018
Accepted / Kabul tarihi: 15.11.2018
Published / Yayın tarihi: 26.11.2018

Copyright © 2018 The Author(s)
Published by JOSAM

This is an open access article distributed under the terms of the Creative
Commons Attribution-Non Commercial-NoDerivatives License 4.0 (CC
BY-NC-ND 4.0) where it is permissible to download, share, remix,
transform, and buildup the work provided it is properly cited. The work
cannot be used commercially without permission from the journal.



A plain abdominal X-ray film showed dilatation of small bowel loops and the presence of multiple air-fluid levels (figure 1). The abdominal CT-scan demonstrated dilated loops of small bowel 3 cm proximal to the point of obstruction, an image of swirling strands of soft tissue and fat attenuation in the right inguinal region realizing the whirl sign and a double bird's beak sign due to the mesenterico-axial volvulus (figure 2).

Surgical exploration revealed the presence of a small bowel volvulus secondary to an adhesion band between the ovary and the small intestine responsible if an intestinal distension located 1.3 m upstream of the ileocecal valve, without visible necrosis. A lysis of the adhesion was performed, with a small bowel reduction and retrograde evacuation of the proximal segment (figure 3). The postoperative period was uneventful; the patient was discharged on postoperative day four.

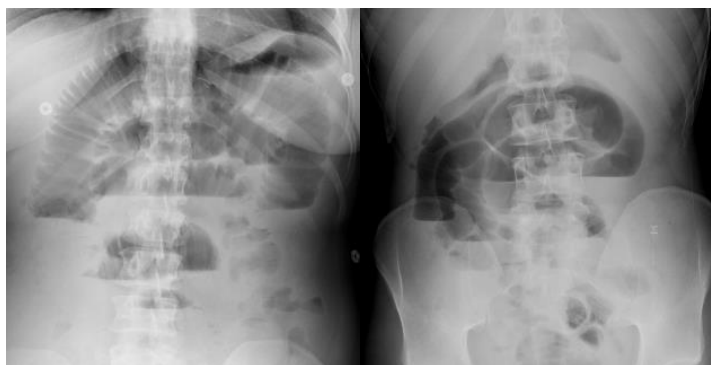

Figure 1: A plain abdominal X-ray film showed dilatation of small bowel loops and the presence of multiple air-fluid levels.

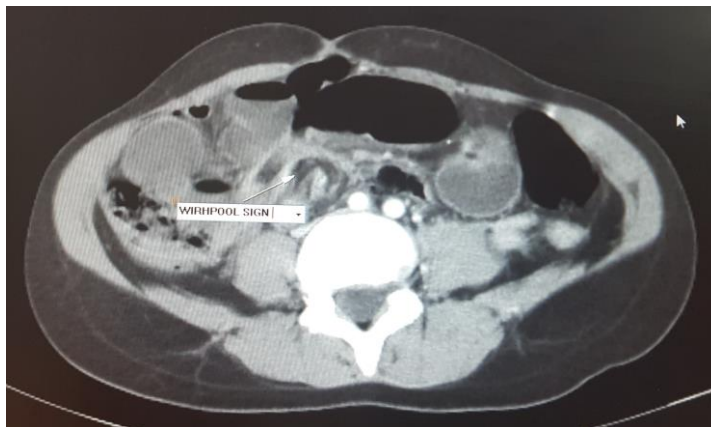


Figure 2: The whirl sign and a double bird's beak sign due to the mesenterico-axial volvulus.

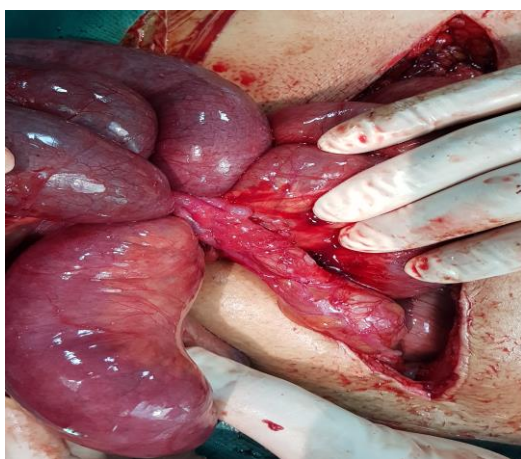


Figure 3: Flange between ovary and small intestine loops.

Discussion

Adhesive occlusion is a common cause of hospitalization in surgery. It occurs mainly in young patients with a history of abdominal surgery, the age of our patient was 32 years, which is consistent with others series, like the series of Mr. Maliki Alaoui [2] where the mean age was 41.9 years, Miller 46 years [3], Diakit  39.7 years [4] and Harouna [5] 32 years. However Catel [6] and Hiki [7] found an elderly population (61 and 59.6 years respectively). This can be explained by the young age of the Moroccan population. Adhesive occlusion affects mainly male with a sex ratio of 1.6. This has also been observed in other African studies [1-8]. On the other hand, there was a women predilection in Western series [3-4]. Numerous studies have shown that lower abdominal surgery is certainly associated with more adhesive occlusion [9-10], which is consistent with our case. In the literature we found that for Yazidi and Shapiro, colorectal surgery seems to be the most exposed to adhesions [11], for Shih and Irabor Do. [12] gynecological surgery is a significant cause of small bowel obstruction [13], according to A. Audebert near one out of 20 readmissions related to adhesions after gynecological laparotomy is due to a small bowel obstruction. An analysis of hospitalizations for intestinal obstruction non related to a tumoral process showed that in 50.4% of cases, occlusion was due to a prior gynecological intervention, most commonly an abdominal hysterectomy [14,15].

The time between index intervention and the first episode of small bowel obstruction varies widely from 8 days to 60 years [11]. In our case; occlusion was late, occurring 1 year and 6 months after the surgery. The clinical manifestations that were observed in our case are: abdominal pain, vomiting, and inability to pass gas abd stool, which is consistent with the results of Harouna's series [5]. The delay between the first symptoms and the consultation is an important factor that influences considerably the severity of the disorders, and the prognosis of the patients. The longer the delay, the more vitality of the intestine is at stake. In our case, the patient consulted within 72 hours. A complete physical examination should be performed to detect signs of severity [16]. The plain abdominal X-ray allows a first diagnostic and etiological assessment of the occlusive syndrome, its specificity and sensitivity remain low [10]. The abdominal CT scan confirm the diagnosis of small bowel obstruction with a sensitivity of 94 to 100% and a specificity of 90 to 95%. It not only makes the positive and accurate etiological diagnosis (sensitivity of 73 to 95%), but also identifies time-sensitive complications including ischemia and perforation, and thus determines a treatment strategy [6,17]. In addition, a laboratory tests are often used to evaluate the hydroelectrolytic disorders and to carry out a preoperative assessment. Therapeutically, there is no consensus about the choice between surgical treatment at the outset and conservative treatment, which finds full justification in patients without signs of clinical and biological severity. However, this treatment may miss a necrosis that would then require resection [11]. The duration of the conservative treatment can range from a few hours to 14 days [16].

In our case, we opted for a surgical treatment at the outset because of signs of ischemia (tachycardia, fever, and

leukocyte at 17000), with the CT scan showing mesenteric-axial volvulus. We performed a midline laparotomy straddling the umbilicus. Laparoscopic treatment of adhesive occlusions is an alternative to laparotomy in selected patients. Its best indication might be single adhesive band. This alternative to laparotomy could reduce the formation of adhesions [18, 19], and reduce the number of next occlusive episodes. The rate of conversion to laparotomy varies from 8 to 46% [19], it would be necessary for many reasons including: the non-visualization of the localization of the occlusion, an intestinal injury caused by the manipulation of dilated loops, the necessity to proceed to resection or a difficult dissection due to a multi-adherent abdomen. In addition, laparoscopy provides a certain number of advantages by reducing the operative time, the time of intestinal transit recovery, the postoperative stay and postoperative complications according to Ghariani [19]. In our case, we performed a laparotomy. The surgical technique consists first of all in an evacuation as complete as possible of the upstream bowel; it is only feasible in laparotomy. Evacuation allows: to ensure the decompression of the intestine to reduce the distension in order to prevent ischemia, to explore in a reliable manner the entire abdominal cavity. However, there is no evidence that it facilitates the transit recovery [20]. The section of a single adhesion band is usually performed without major difficulty. This can be difficult when the adhesion is very short, with much dilated upstream loops hindering the exposure of the initial lesion, or when the adhesion band is located in a difficult access area. In case of multiple adhesions, adhesiolysis can be difficult with a major risk of inadvertent bowel injury, so wisdom incites to treat only the obvious cause by performing partial adhesiolysis [20]. Once the obstacle is removed, it is important to assess the vitality of the intestinal loops, and in case of doubt, resection is required. Indeed, the risk is to leave in place a poorly vascularized intestinal segment that can be complicated in short-term by perforation and postoperative peritonitis or in long-term by ischemic stenosis. The resection of a small bowel loop has no special technical feature, but it is necessary to ensure the construction of a well-vascularized anastomosis. The duration of postoperative hospital stay depends on the therapeutic modality and the occurrence of complications; longer in patients who have undergone resection, than in those with viable bowel, or when opted for a conservative treatment before switching to surgery.

Conclusion

Continuous progress in the management of adhesive occlusions has been achieved as a result of a more careful clinical approach, nowadays it cannot be said that CT and laparoscopy has true impact on the prognosis of adhesive occlusion. It is certainly towards prevention strategies, thanks to panoply of better codified gestures and improved anti-adhesion devices that the surgeon must turn to reduce the frequency of a surgical complication that is often frustrating because of its relative unpredictability.

References

1. Kuremu RT, Jumbi G. Adhésive intestinal obstruction. *East Afr Med J.* 2006;83:333-6.
2. ALAOUI MM. Les occlusions intestinales sur brides postopératoires, étude rétrospective à propos de 134 cas. Thèse de Doctorat Médecine, Rabat. 2014;M1122014.
3. Miller G, Boman J, Shier I. Natural history of patients with adhesive small bowel obstruction. *Br J Surg.* 2000;8:1240-7.

4. Diakité MD, Gangaly D. Etude des occlusions sur bride dans les services des urgences chirurgicales, de chirurgie générale et pédiatrique du CHU Gabriel Touré. Thèse de Médecine université de Bamako faculté de médecine, de pharmacie et d'odontostomatologie, 2008.
5. Harouna Y, Maazou I, Almoustapha I, Samir R, Amadou S, Baoua A, et al. Les occlusions intestinales aiguës par brides : A propos de 87 cas. *Med Afr Noire.* 2005;935:317-9.
6. Catel L, Lefèvre F, Laurent V, Canard L, Bresier L, Guillemin FD et al. Occlusion sur bride. Quels critères scanographiques de gravité rechercher ? *J Radiol.* 2003;84:27-31.
7. Hiki N, Takeshita Y, Kubota K, Tsugi E, Yamaguchi H, Shimizu N, et al. A seasonal variation in the onset of postoperative adhesive small bowel obstruction is related to changes in the climate. *Dig Liver Dis.* 2004;36:125-9.
8. Harouna Y, Maazou I, Almoustapha I, Samir R, Amadou S, Baoua A et al. Les occlusions intestinales aiguës par brides : A propos de 87 cas. *Med Afr Noire.* 2005;935:317-9.
9. Kossi J, Salminen P, Laato M. The epidemiology and treatment patterns of postoperative adhesion induced intestinal obstruction in varsinais-suomi Hospital District. *Scand J Surg.* 2004;93:68-70.
10. Duron JJ, Silva NJ, Du Montcel ST, Berger A, Muscari F, Hennet H et al. Adhesive postoperative small bowel obstruction: Incidence and risk factors of recurrence after surgical treatment: a multicenter prospective study. *Ann Surg.* 2006;244:750-7.
11. Sarraf S Y, Shapiro ML. Small bowel obstruction: The eternal dilemma of when to intervene. *Scand J Surg.* 2010;99:78-80.
12. Irabar DO, Afuwape O. Primary Operative Management for Low Adhesive Bowel Obstruction. *East Cent. Afr J Surg.* 2012;17(1):65-9.
13. Shih SC, Jeng KS, Lin SC, Kao CR, Chou SY, Wang HY, et al. Adhesive small bowel obstruction: How long can patients tolerate conservative treatment? *World J Gastroenterol.* 2003;9:603-5.
14. Audebert A, Darai E, Benifla JL, Yazbeck C, Déchaud H, Wattiez A, et al. Adhérences postopératoires et leur prévention en chirurgie gynécologique : I. Ce qu'il faut savoir. *EMC Gynécologie obstétrique et fertilité.* 2011;10:1010-6.
15. Al-Sunaidi M, Tulandi T. Adhesion-related bowel obstruction after hysterectomy for benign conditions. *Obstet Gynecol* 2006;108:1162-6.
16. Shih SC, Jeng KS, Lin SC, Kao CR, Chou SY, Wang HY, et al. Adhesive small bowel obstruction : How long can patients tolerate conservative treatment ? *World J Gastroenterol.* 2003;9:603-5.
17. Delabrousse E, Bouland R, Salière P, Mickalakis D, Rodiere E, Kastler B. Le faces sign : valeur d'un signe TDM dans l'occlusion du grêle sur bride ou adhérence péritonéale. *J Radiol.* 2005;86:393-8.
18. Ouaiissi M, Gaujoux S, Veyrie N, Denève E, Bergand C, Castel B, et al. Les adhérences postopératoires après chirurgie digestive et leurs préventions: revue de la littérature. *J Visc Surg.* 2011;60:21-8.
19. Ghariani B, Houssa H, Sebai F. Traitement laparoscopique des occlusions mécaniques du grêle. *Tunis Med.* 2011;89:274-7.
20. Trésallet C, Roy B, Menegaux F. Occlusion du grêle de l'adulte. *EMC techniques chirurgicales- appareil digestif.* 2010;53:430-40.