

## Use of Dental Implantation in a Dog With Hypodontia in Permanent Dentition

Murat KİBAR<sup>1\*</sup>

<sup>1</sup>Artvin University, Artvin Vocational School, Hunting and Wild Life Programme, Artvin, Turkey

**Abstract:** The purpose of this article is to evaluate clinical properties of a rare hypodontia case in the permanent dentition in a dog, and its treatment by dental implantation. A 1.5-year-old male Canary dog was referred to the surgery department for missing of a tooth. All primary teeth were present except for the right mandibular fourth premolar (P4) at the time of the first dental examination. Mandibular oblique radiographs confirmed the finding of P4 hypodontia. The implant system consisted of an endosseous component, a transgingival collar, a collar-retaining screw, a coping, and a coping-retaining screw. Ceramic implant tooth was placed and fixed by dental acrylic. There was no any implant stability after 3 month the surgery. In conclusion, hypodontia is a rare abnormality that we now know can be seen in dogs. It can reconstructed by implant system and the owner's dissatisfaction can be fulfilled.

**Keywords:** dental implant, dog, hypodontia

### Kalıcı Dişlerinde Hipodenti Bulunan Bir Köpekte Diş İmplantı Kullanımı

**Özet:** Bu çalışmanın amacı, bir köpekte nadir görülen hipodontinin klinik bulgularının ve diş implantı kullanılarak tedavisinin değerlendirilmesidir. Canary ırkı 1,5 yaşında erkek köpek diş eksikliği ile cerrahi kliniğinde muayene edildi. İlk diş muayenesi sırasında sağ mandibular 4. premolar (P4) haricindeki dişler tamdı. Mandibulanın oblik radyografisi P4 hipodontiyi doğruladı. İmplant sistemi; kemik içi gövde, gingivadan geçen boyun, boynu tutturucu vida, kaplama ve kaplama vidasından oluşmaktaydı. Seramik diş implantı yerleştirildi ve diş akriliği ile sabitlendi. Cerrahiden 3 ay sonra herhangi stabilite devam etmekteydi. Sonuç olarak, köpeklerde görebileceğimiz hipodonti nadir izlenen bir anomalidir. Bu anomali, implant sistemi ile düzeltilerek hayvan sahibinin memnuniyetsizliği düzeltilebilir.

**Anahtar kelimeler:** diş implantı, köpek, hipodonti

---

\*Corresponding Author: Murat KİBAR Artvin University, 08100, Artvin, Turkey.  
E-mail: muratkibartr@yahoo.com

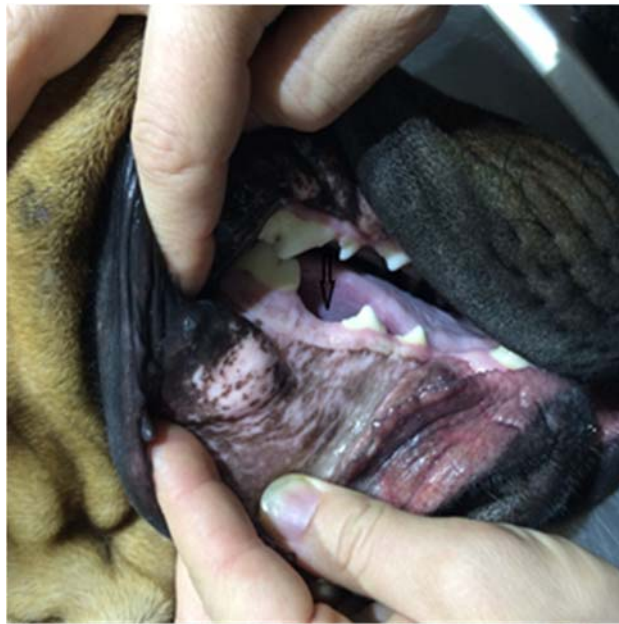## INTRODUCTION

Developmental dental disorders may result in anomalies in the structure, shape, size, or number of the teeth (1,2). Hypodontia, named as one or more missing teeth, is presented in different breeds of dogs. Hypodontia prevalence is noticed that between 1-14% ratio in human medicine (3).

The first successful implant in human dentistry was enforced in 1965 (1). Cosmetic dentistry is an expanding business in human medicine, and its popularity in the veterinary practice is sure to follow (4). Because suitable implantation in veterinary patients needs several times anesthetic events, the entire process can continue between 14 and 18 weeks (1). The purpose of this article is to evaluate clinical properties of a rare hypodontia case in the permanent dentition in a dog, and its treatment by dental implantation.

## CASE

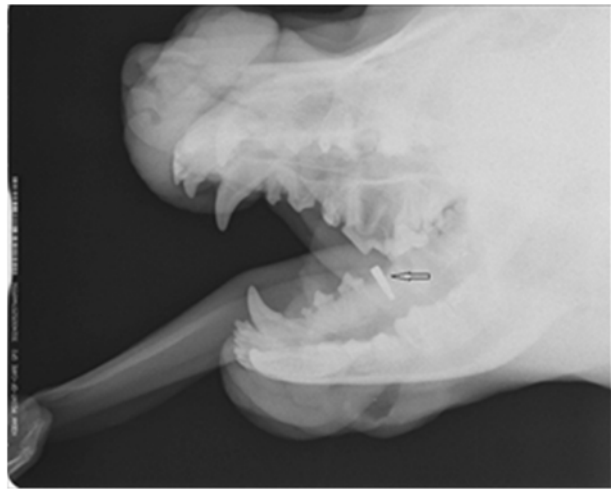
A 1.5-year-old male Canary dog was referred to the surgery department for missing of a tooth (Figure 1). His owner was discontented to this esthetic problem. His body weight was 43 kg. All primary teeth were present except for the right mandibular fourth premolar (P4) at the time of the first dental examination. Mandibular oblique radiographs confirmed the finding of P4 hypodontia. The implant system take placed an endosseous component, hereafter referred to as the implant, a coping, a coping-retaining screw, a transgingival collar, and a collar-retaining screw (Niko Dental, Bad Elstam, Germany).



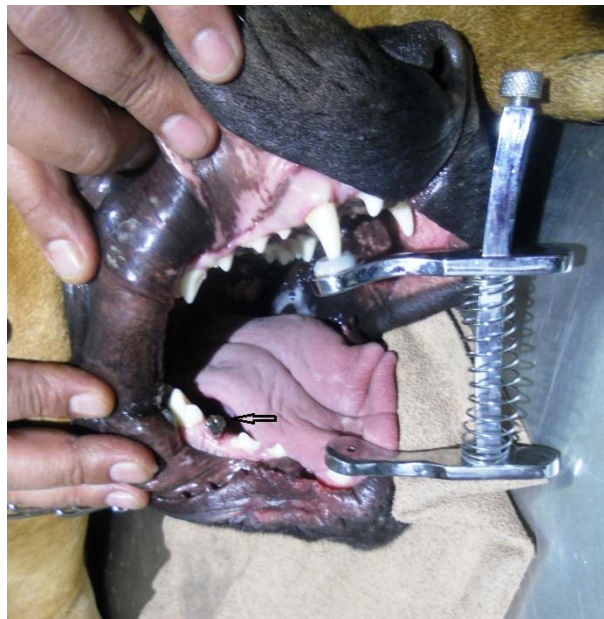**Figure-1.** View of missing tooth on the right mandible (arrow).

Dog was premedicated with xylazine 2 mg/kg IM and atropine 0.04 mg/kg SC, and general anesthesia was induced with ketamine 10 mg/kg IM. Directly on the ridge crest, a crestal incision was made in the linea alba. A hole (4.0 × 11.5 mm) was made by drill. This hole dilated by 4.2 × 11.5. For implant, the insertion torque, which demonstrates the cutting resistance of bone when its spin is stopped, was patented in Ncm (Saeshin, Korea). The implant was established at the bone level (Figure2). After stable installation of implant, cover screw was bonded to it (Figure3). The dog was then discharged and permitted only pureed food for the

first 10 days and a soft diet. Ten weeks were let to elapse to the maturation of gingival vascularity and provide bone healing.

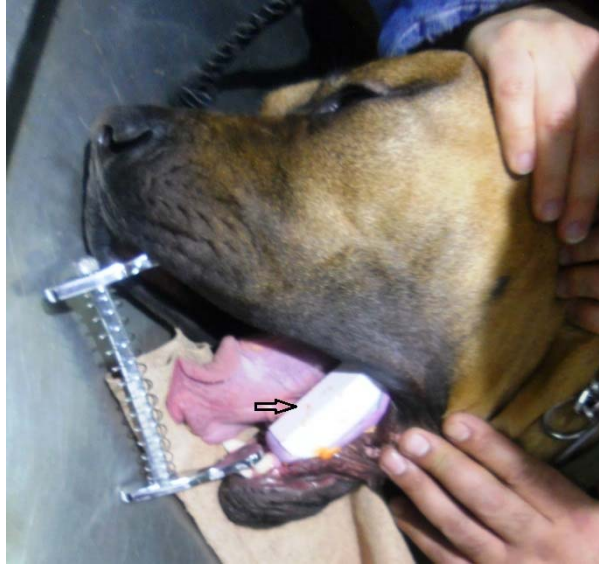

**Figure-2.** The radiographic appearance of the implant (arrow)in the bone level.

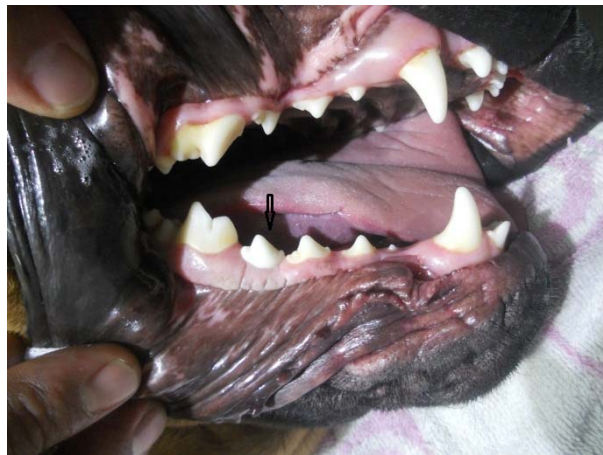

**Figure-3.** View of implant and cover screw (arrow) on the right mandible.

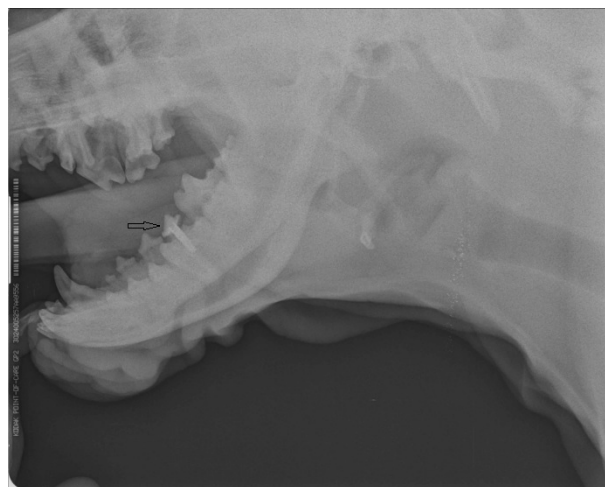
Transfer was placed right mandible. Two stage tooth mold was done by silicone gel (zeta plus, Italy) with 2 spatula. Mold of missing tooth was taken. Additionally, contrary P4 mold was also done (Figure 4). During a second procedure, the cover screw was lifted from implant, and the collar-retaining screw and collar were enclosed and squizzed with a small screwdriver and the anti-torque wrench. Next, the coping-retaining screw and coping were attached, the latter being squizzed minimally. Abudment was added on implant. After abudment was covering by teflon tape and tempit item. Abudment was applied by anticeptic and saliva was cleaned from area. Ceramic implant tooth was placed and fixed by dental acrylic (Aifix) (Figure 5). Radiographs were taken pre-operatively and immediately postoperatively (Figure 6). Thereafter, radiographic follow-up was planned at the scheduled monthly examination.



**Figure-4.** View of tooth mold (arrow) on the left mandible.



**Figure-5.** View of ceramic implant tooth(arrow) on right mandible.



**Figure-6.** The radiographic appearance of ceramic implant tooth (arrow).

There was no detected any other family history of a similar phenotype. No other general dysmorphic features were determined. The dentition of the patient's mother and brother were controlled clinically but no significant features were found. The patient's chest radiograph and preoperative laboratory findings were all normal. Implantation site tested in dog mandible was showed to be bone type II. There was no any implant instability after 3 month the surgery.

## DISCUSSION

The dog probably exposes more hereditary dental abnormalities than any other animal, because of the difference in shape and size of breeds as well as from sometimes indiscriminate and intensive inbreeding (2,5). It is reported that the prevalence of hypodontia (32.3%) is in 288 out of 627 examined dogs. This is significantly higher for large dolichocephalic breeds (2). In this case, hypodontia was determined in a Canary dog which is include large breed dogs. The third lower molars are the teeth most frequently missing followed by the first lower and upper premolars, and the second lower and upper premolars, as noticed by Pavlica et al., 2001. Hypodontia was identified the lower premolars in this case.

The patient described in this report appeared to be the first member of his family to show these clinical features. There was no family history of a similar phenotype. The possible genetic basis of hypodontia in this case is thus unknown. It may be X-linked like the other reported cases; however, this is not definite because of the negative family history.

Previous research has pointed that a region of necrotic bone surrounding the implant exists following surgery and that the extent of this region is influenced by drilling speed (6), design, and irrigation mode (or absence of irrigation) (7). In this case, implant was placed under a simplified technique where multiple drills of increasing diameter were utilized. All drilling procedures were conducted at 900 rpm under abundant irrigation. There was no any implant stability after 2 month the surgery.

It was noted that the bone implant score obtained from radiographic analysis was an accurate means of assessing peri-implant bone height is confirmed by the good correlation between bone implant score values and data on peri-implant attachment levels and pocket depths (8). By the radiographs bone implant score determined type II in implantation site on mandible. In conclusion, hypodontia is a rare abnormality that we now know can be seen in dogs. It can reconstructed by implant system and the owner's dissatisfaction can be fulfilled.

## REFERENCES

1. **Schroeder, H.E. (1991).** Development and Structure of the Tissues of the Tooth, Clinical Consideration. In: Schoeder, H.E. (Ed.), Oral Structural Biology. Thime, Stuttgart, pp. 171-186. <https://lib.ugent.be/en/catalog/rug01:000269550>
2. **Pavlica, Z., Erzavecic, V., Petelin, M. (2001).** Teeth abnormalities in the dog. ACTA Vet Brno, 70, 65-72. [https://www.omicsonline.org/veterinary-science-journals.php?gclid=EAlalQobChMIltnt8dSb3AIVBp3VCh0IOANJEAAAYASAAEgJ6pFD\\_BwE](https://www.omicsonline.org/veterinary-science-journals.php?gclid=EAlalQobChMIltnt8dSb3AIVBp3VCh0IOANJEAAAYASAAEgJ6pFD_BwE)
3. **Şişman, Y., Uysal, T., Gelgor, I. (2007).** Hypodontia. Does the prevalence and distribution pattern differ in orthodontic patients? Europ J Dent, 1, 167-173. <https://www.ncbi.nlm.nih.gov/pmc/articles/PMC2638243/>
4. **Ekren, O., Kurtoğlu, C. (2009).** The effect of implant abudment connection type to the clinical success of implant supported fix restorations: A literature reviev. Atatürk Univ J Dent Fac, 19, 131-137. <http://dergipark.gov.tr/ataunidfd/issue/2484/31794>

5. **Kertesz, P. (1993).** Dental Development and Abnormalities. In: Kertesz, P. (Ed.), A Colour Atlas of Veterinary Dentistry and Oral Surgery. Wolfe, London, pp. 51-72. <https://www.cabdirect.org/cabdirect/abstract/19932281193>
6. **Kim, S.J., Yoo, J., Kim, Y.S., Shin, S.W. (2010).** Temperature change in pig rib bone during implant site preparation by low-speed 6 International Journal of Biomaterials drilling. J Appl Oral Sci, 18, 22-527. <https://koreauniv.pure.elsevier.com/en/publications/temperature-change-in-pig-rib-bone-during-implant-site-preparatio>
7. **Scarano, A., Piattelli, A., Assenza, B., Carinci, F., Di Donato, L., Romani, G.L., Merla, A. (2011).** Infrared thermographic evaluation of temperature modifications induced during implant site preparation with cylindrical versus conical drills. Clin Impl Dent Rel Res, 13, 319-323. <https://www.ncbi.nlm.nih.gov/pubmed/19681941>
8. **Deporter, D.A., Friedland, B., Watson, P.A., Pilliar, R.M., Howley, T.P., Abdulla, D., Melcher, A.H., Smith, D.C. (1986).** A clinical and radiographic assessment of a porous surfaced, titanium alloy dental implant system in dogs. J Dent Res, 65, 1071-1077. <https://www.ncbi.nlm.nih.gov/pubmed/352562>