

## AETIOLOGICAL INVESTIGATION TO CYSTIC BRONCHIECTASIS IN AN ADULT PATIENT; CASE PRESENTATION

### ERİŞKİN HASTADA KİSTİK BRONŞEKTAZİYE ETYOLOJİK YAKLAŞIM; VAKA TAKDİMİ

Ayşe BAÇÇIOĞLU KAVUT<sup>1</sup> Ashhan YALÇIN<sup>2</sup>

<sup>1</sup>Erzurum Bölge Eğitim ve Araştırma Hastanesi, İmmünoloji ve Allerji Bölümü, Erzurum

<sup>2</sup>Nihat Kitapçı Göğüs Hastalıkları Hastanesi, Göğüs Hastalıkları Bölümü, Erzurum

**Key words:** Adult, bronchiectasis, cystic fibrosis, sweat test

**Anahtar sözcükler:** Erişkin, bronşektazi, kistik fibrosis, ter testi

Geliş tarihi: 19 / 03 / 2012

Kabul tarihi: 04 / 07 / 2012

#### SUMMARY

Bronchiectasis may be the pathological expression of a large variety of disorders. However, a search for the aetiology is underestimated in many cases. Here, we searched the possible underlying diseases in a 43-year-old woman with recurrent history of sinopulmonary infections who was diagnosed as having cystic bronchiectasis lately. Family history was positive for recurrent respiratory infections. During the last two decades Streptococcus pneumoniae and Haemophilus influenzae were isolated repeatedly from her sputum. At diagnosis, patient was searched for underlying diseases including infections, immunodeficiency, cystic fibrosis (CF), and allergic bronchopulmonary aspergillosis. Recurrent sweat-chloride test results were reported as borderline. However, no genetic mutations were detected for a diagnose of CF. Next, patient was given an individualized therapy, and taken into a follow-up. This case summarizes the screening tools when an adult presents with recurrent respiratory infections, and bronchiectasis.

#### ÖZET

Bronşektazi çeşitli hastalıkların patolojik yansıması olabilir. Ancak, etyolojik araştırma pek çok vakada hafife alınmaktadır. Burada tekrarlayan sinopulmoner enfeksiyon öyküsü olan ve ileri yaşta kistik bronşektazi tanısı alan 43 yaşındaki kadın hastayı altta yatan olası hastalıklar açısından araştırdık. Hastanın ailesinde tekrarlayan solunum yolu enfeksiyonu öyküsü mevcuttu. Son iki dekatta, balgamında Streptococcus pneumoniae ve Haemophilus influenzae tekrarlayan kereler izole edilmişti. Hasta tanı konulmasını takiben, enfeksiyonlar, immün yetmezlik, kistik fibrosis (KF) ve allerjik bronkopulmoner aspergillozis gibi altta yatan hastalıklar yönünden araştırıldı. Terde klor testi, tekrarlayan kereler sınırdan pozitif sonuçlandı. Ancak, KF tanısı için genetik mutasyon saptanmadı. Takiben, hastaya özel tedavi verilerek izleme alındı. Bu vaka, tekrarlayan solunum yolu enfeksiyonu ve bronşektazisi olan erişkin hastalara yaklaşım yöntemlerini göstermektedir.

## INTRODUCTION

Bronchiectasis is defined as irreversible dilatation of bronchi, leading to increased sputum production and chronic cough (1). There're three types of bronchiectasis as cylindrical - the least severe form -, varicose - bronchial fibrosis -, cystic/saccular - the most severe form- (1). Bronchiectasis may be also the pathological expression of another disorder, and so detecting the aetiology will have a positive effect on the prognosis of the patient. This case summarizes the immunologic approach to cystic form of bronchiectasis.

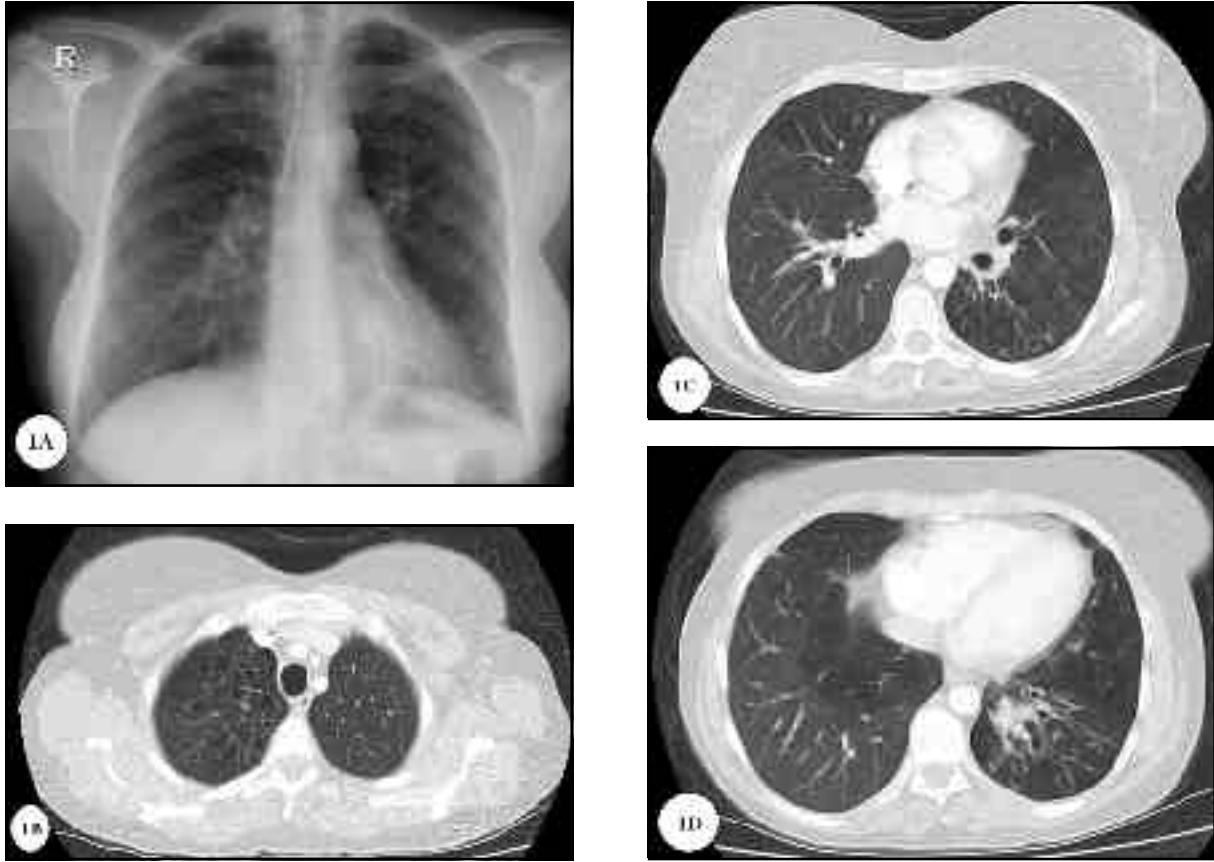
## CASE REPORT

A 43 - year - old woman suffered from recurrent sinopulmonary infections with symptoms of cough, thick - purulent sputum and rare haemoptysis during the last two decades. By the age of 40 years, she began to suffer from progressive shortness of breath. She was a non-smoker and was exposed to indoor fume. Her father died of lung disease. She had two healthy brothers and four children, and one of her son had been living recurrent respiratory infections.

She was admitted to Allergy and Immunology Clinic with treatment resistant dyspnoea. Although she was discharged from hospital where she was given antibiotic, systemic corticosteroid and bronchodilators for 10 days a few days ago, she had still purulent sputum, dyspnoea, and nasal obstruction. A physical examination disclosed that she was a thin but well developed white woman. She had a post-nasal drip and diffuse ronchi in her lung. In her chest roentgenogram, there were bilateral infiltrates at the right perihiler and left - lower zones. A high - resolution computed tomography (HRCT) scan revealed bilateral cystic bronchiectasis, and

peribronchial wall thickening predominantly in the right upper and middle lobes, and in the left lower lobe (Figure 1), and pansinusitis with no polyposis. Her predicted forced-expiratory-volume in the first second (FEV<sub>1</sub>) was 69% - 2L, FEV<sub>1</sub> / forced - vital - capacity (FVC) was 83%, forced - expiratory - flow 25-75% was 55% - 1.89L with a negative reversibility (5% - 90ml increase in FEV<sub>1</sub> after 2-agonist inhalation). Echocardiography showed a pulmonary systolic pressure of 35mmHg and normal ventricular function. Cultures of sputum were found to be positive for *tococcus pneumoniae* and *Haemophilus influenzae* like during the last two decades. Bronchoscopy was performed for the left hiler image with thickened bronchial wall and revealed mucus plugging. Brush samples were consistent with leucocytic inflammation and fibrosis with no malignant cell. Culture of bronchial lavage was negative for *Staphylococcus aureus*, *Pseudomonas aeruginosa*, *Mycobacterium tuberculosis* and fungus.

In the evaluation of underlying diseases, allergic bronchopulmonary - aspergillosis (ABPA) was inconsistent with the following results; 1) negative fungus hifa in her sputum, 2) negative aspergillum sensitivity in skin prick, intradermal and specific immunoglobulin (Ig) E tests, 3) normal blood eosinophilia (100/mm<sup>3</sup>), 4) normal serum total IgE (12.39kU/l). She was found non-atopic by negativity in skin prick tests with common inhalant allergens. Levels of Ig A, G, and M were found to be in normal limits excluding humoral immunodeficiency (482mg/dL, 1560mg/dL, and 96.1mg/dL respectively). Cystic fibrosis (CF) was proposed with cystic bronchiectasis, recurrent sinopulmonary infections, progressive loss in lung function, and malnutrition. Sweat - chloride tests were resulted as borderline



**Figure 1. A)** A chest roentgenogram showed bilateral infiltrates at the right perihiler and left-lower zone. **B)** High resolution computed tomography of the chest showed cystic bronchiectasis in the right upper lobe, **C)** Peribronchial wall thickening, **D)** cystic bronchiectasis predominantly in the left lower lobe.

for 3 times, as 50, 46, 48 mmol/Lt in different times (Normal :< 40 mmol/Lt, CF :> 60 mmol/Lt). In genetic analysis, no CF mutation was detected except the T allele in 5T/7T/9T polymorphism in multiplex-PCR (reverse hybridisation). The gastrointestinal system (GIS) involvement was examined for CF. Her height was at the 25th percentile, and weight below the 3rd percentile, but she had no symptoms of malabsorption, and needed no pancreatic enzyme substitution or vitamin supplements, except oral iron treatment. Hepatomegaly was noted in abdomen ultrasonography with normal liver function tests. Her pancreatic function was

sufficient as shown by normal serum amylase, glucose and HBA1C levels, and by abdomen magnetic resonance investigation. Serum 1-antitrypsin (AAT), thyroid -stimulating hormone, vitamin D, vitamin B12, total protein, electrolytes, and cholesterol profile were also in the normal range, except low uric acid levels (2.2 mg/dL).

As a result, no underlying disease was identified, except an imprecise diagnose of CF with borderline sweat-chloride test. The patient was taken into a follow-up, and her dyspnoea and sputum expectoration have benefited from nebulised hypertonic saline, oral acetyl cysteine and pulmonary physio-

## AETIOLOGICAL INVESTIGATION TO CYSTIC BRONCHIECTASIS

therapy which were added to her daily home treatment besides bronchodilators. Also she was given a flu and 23-valent pneumococcal vaccine. A written informed consent was taken from the patient for this publication.

### DISCUSSION

The development of broad spectrum antibiotics, better social conditions, appropriate treatment of pulmonary tuberculosis and vaccinations have most certainly contributed toward a decrease in postinfectious bronchiectasis (1,2). On the other hand, it is still common in Turkey with an insight into new causes, such as AIDS, possible complication of transplants, higher survival rate of patients with CF and immunodeficiency disorders (2). Aetiological investigation of bronchiectasis

is undervalued, because it is difficult to identify, and even it is found, doctors believe that it may not change the ongoing treatment (1). However, Shoemark et al obtained the aetiology of bronchiectasis in 165 adults with a rate of 74% which changed the therapeutic strategy in 37% of them (3). So, we performed an aetiologic work up in this patient with cystic bronchiectasis (Table 1).

She had no history of serious infection in her younger ages, which was the common cause of bronchiectasis (4). Mycobacterium which is a reason of bronchiectasis, is initially detected in older men with smoking habits and chronic obstructive pulmonary disease, but apical fibrocavitary disease, and thickening of the pleura were absent in

**Table 1.** Causes of cystic bronchiectasis.

Aetiology	Investigation
Idiopathic	
Postinfectious	Bronchoscopy with alveolar lavage Microbiologic work up
ABPA	Immunology work up (Total IgE, aspergillus prick test / specific IgE, sputum fungus investigation)
Cystic fibrosis	Sweat chloride test Genetic analysis Ion transport across the nasal epithelium
Immunodeficiency	Immunology work up (Ig A, G, M and Ig subgroups, vaccine response, complement activity)
Primary ciliary dyskinesia	Cilium function Exhaled nitric oxide
1-antitrypsin deficiency	1-antitrypsin level Genetic analysis
Diffuse panbronchiolitis	Exhaled nitric oxide Microbiological work up
Congenital anatomic defects	Radiologic work up Bronchoscopy
Connective - tissue disorders, and inflammatory bowel disease	Immunology work up (eg rheumatoid factor) Gastroenterology consultation

ABPA: Allergic bronchopulmonary aspergillosis

this patient (4). However, the infection may be a consequence contributing to the development of the disease, and routine sputum cultures should include tuberculosis and atypical Mycobacterium isolates in patients with bronchiectasis.

ABPA is a progressive immunologic disease ending with extensive bronchiectasis, and early diagnosis (ABPA seropositive stage) can prevent the development end stage disease (5). Our patient had symptoms of ABPA as coughing, sputum, wheezing and dyspnoea, and had bronchiectasis in the central and upper lobes. However, other diagnostic criteria of the disease including asthma (negative FEV1 reversibility), total IgE >1,000 kU/L, peripheral eosinophilia, sensitivity to aspergillus, precipitin for *A. fumigatus*, and the presence of migrating pulmonary infiltrates during exacerbations were absent in this patient (8).

Humoral immunodeficiency secondary to a defined genetic disorder appears during childhood, and our patient seemed to be asymptomatic in this period. On the other hand, selective Ig A or Ig G deficiency (Common variable immune deficiency) appears later on. However, even in patients with normal IgG serum levels, a deficient response to polysaccharide antigens may be present. Measuring the titers up to 14 serotypes, both prior to and 4 weeks following vaccination with pneumococcal-polysaccharide is recommended which was absent in our condition (6). Thus, it is important to assess that Ig and subclass levels, and a vaccine response in an adult with bronchiectasis of unknown origin and recurrent respiratory infections.

Primary ciliary dyskinesia (PCD) is an autosomal-recessive disorder accompanied with infertility and bronchiectasis (in the middle and lower lobes). Situs inversus

occurs in approximately 50% of the cases which is designated as the Kartagener syndrome. The definitive diagnosis is based on saccharin test, exhaled nitric oxide (FeNO), and ultrastructural ciliary exam of ciliated nasal epithelium (7). Our patient didn't have the characteristics for this disease such as infertility, location of bronchiectasis, and situs inversus.

A typical CF diagnose includes an elevated sweat chloride concentration plus a combination of clinical characteristics including chronic airway infection, bronchiectasis, abnormalities of GIS and the reproductive tract. Treatment with recombinant human - DNase showed good effect in CF bronchiectasis. Even though, CF was considered as a childhood disease, after the developments in the treatment of CF, survival improved. In the literature, the oldest age of newly diagnosed CF was 80 years. In case of borderline sweat test results, test should be repeated, and mutation analysis should be undertaken. Finding two abnormal genes with an intermediate sweat test or in vivo demonstration of ion transport across the nasal epithelium confirms CF. Adulthood CF have greater diversity of mutations, pulmonary disorder of minor severity, and intermediate to normal values on sweat tests, different rates of pancreatic sufficiency, less growth of *Pseudomonas aeruginosa*, and higher rates of infections by atypical Mycobacterium. Our case had CF phenotype including recurrent infections, cystic bronchiectasis, and pathological bacterial flora, intermediate sweat test with no mutations in the chromosome 7. However, this case might be a milder form, since only 40 mutations were searched and there was a variety of mutations for this disorder (1604 mutations) (8).

ATS/ERS recommend quantitative testing of AAT in individuals with bronchiectasis (9).

Deficiency of AAT is mainly associated to the development of emphysema, and also cylindrical or varicose bronchiectasis type predominating in the lower lobes in youngsters (9). Accurate diagnose is important because of the possibility of using AAT augmentation therapy. In this case, AAT level was normal and the patient's radiology was different from AAT deficiency as mainly central bronchiectasis with no emphysema.

Diffuse panbronchiolitis (DPB) is an idiopathic inflammatory disorder of bronchus and sinuses which is identified in adults between the 2<sup>nd</sup>-5<sup>th</sup> decades in non-smokers. The most frequently isolated pathogen in sputum is *Haemophilus influenzae*. The nasal NO is low, and HRCT findings are consist of centrilobular nodules, thickened bronchioles, air trapping, bronchiectasis in the lower lobes. Treatment with erythromycin for 2 years has a curative effect. Even though DPB is more common in Asia, this disorder should be included in differential diagnosis of bronchiectasis of unknown aetiology (10). Our patient's radiology was inconsistent with DPB.

Bronchiectasis can also result from a variety of congenital anatomic defects such as

bronchopulmonary sequestration, cartilage deficiency, tracheobronchomegaly, yellow-nail, and Swyer-James syndrome, which became clinically apparent in early ages. Connective - tissue disorders, and inflammatory bowel disease are also associated with non - cystic bronchiectasis, but in small numbers (11). These diseases can be differentiated with their specific systemic findings which were absent in our patient.

Investigation of the underlying aetiology in cystic bronchiectasis should be considered when an adult presents with recurrent respiratory infections, bronchiectasis, and obstructive lung disease. The importance of diagnosing the above mentioned pathologies is related to treatment specificities. Early diagnosis of bronchiectasis and detecting the aetiology will have a positive effect on the prognosis of the patient and on the prevention of bronchiectasis in newborns.

#### **Acknowledgement**

The authors thank to Prof Dr Ajlan Tukan and her coworkers of Ankara University, Faculty of Medicine, Department of Medical Genetics, for asistance with the cystic fibrosis gene mutation analysis.

#### **REFERENCES**

1. Amorima A, Gracia-Róldan J. Bronchiectasis: do we need etiological investigation? *Rev Port Pneumol* 2011; 17: 32-40.
2. Babayigit A, Olmez D, Uzuner N, Cakmakci H, Tuncel T, Karaman O. A neglected problem of developing countries: Noncystic fibrosis bronchiectasis. *Ann Thorac Med* 2009; 4: 21-4.
3. Shoemark A, Ozerovitch L, Wilson R. Aetiology in adult patients with bronchiectasis. *Respiratory Medicine* 2007; 101: 1163-70.
4. Shah PL, Mawdsley S, Nash K, Cullinan P, Cole PJ, Wilson R. Determinants of chronic infection in patients with bronchiectasis. *Eur Respir J* 1999; 14: 1340-4.
5. Oner Erkeköl F, Bavbek S, Göksel O, Mungan D, Aydın O, Can AB, ve ark. Allergic bronchopulmonary aspergillosis: 3 cases. *Tuberk Toraks* 2007; 55: 418-28.
6. Wood P, Stanworth S, Burton J, Jones A, Peckham DG, Green T, et al. Recognition, clinical diagnosis and management of patients with primary antibody deficiencies: a systematic review. *Clinical and Experimental Immunology* 2007; 149: 410-23.
7. Ware SM, Aygun MG, Hildebrandt F. Spectrum of clinical diseases caused by disorders of primary cilia. *Proc Am Thorac Soc* 2011; 8: 444-50.

8. Ozcelik U. Eriskinlerde kistik fibrozis. Toraks Dergisi 2004; 5: 8-18.
9. American Thoracic Society/European Respiratory Society Statement: standards for the diagnosis and management of individuals with alpha-1 antitrypsin deficiency. Am J Respir Crit Care Med 2003; 168: 818-900.
10. Adams NP, Congelton J. Diffuse panbronchiolitis. Eur Respir J 2008; 32: 237-8.

11. Pasteur MC, Bilton D, Hill AT; British Thoracic Society Bronchiectasis non-CF Guideline Group. Thorax 2010; 65: 1-58.

---

**Yazışma Adresi:**

Dr. Ayşe BAÇÇIOĞLU KAVUT  
Erzurum Bölge Eğitim ve Araştırma Hastanesi,  
İmmünoloji ve Allerji Bölümü, ERZURUM  
e-posta : ayshe\_dr@yahoo.com

---