



# Herpes Zoster Ophthalmicus

## Herpes Zoster Oftalmikus

Mustafa Burak Sayhan, Eylem Sezenler, İsmail Hakkı Nalbur, Gökçe Yağcı, Esra Gezer

Department of Emergency Medicine, Faculty of Medicine, Trakya University, Edirne, Turkey

### ABSTRACT

Herpes zoster (HZ) is a common diagnosis in the emergency department, but herpes zoster ophthalmicus (HZO) is a rare form of shingles that typically presents with prodromal symptoms followed by a rash distributed along the V1-V2 dermatomes. Classically, HZO begins with flu-like symptoms including fever, myalgia and malaise for approximately one week. In the current case, we describe a woman who presented to our medical center with a headache and rash on the right forehead. HZO is a potentially serious reactivation of varicella-zoster virus (VZV) in the distribution of the ophthalmic division of the trigeminal nerve. The differential diagnosis of HZO is an important task for emergency physicians because of its rapid onset and severity.

**Keywords:** Herpes zoster, ophthalmicus, emergency department  
**Received:** 04.07.2011 **Accepted:** 04.11.2011

### ÖZET

Herpes zoster (HZ) acil servisin sık tanılarındandır. Ancak herpes zoster oftalmikus (HZO) tipik olarak V1, V2 dermatomları boyunca döküntü sonrası prodromal belirtilerle ortaya çıkan zonanın seyrek rastlanan bir formudur. Klasik olarak, HZO yaklaşık bir hafta ateş, miyalji ve kırıklık gibi grip benzeri semptomlar ile başlar. Bu vakada, sağ alın bölgesinde döküntü ve baş ağrısı şikayeti ile başvuran hastayı tanımladık. HZO, trigeminal sinirin oftalmik dalının dağılımındaki varisella-zoster virüsünün (VZV) ciddi reaktivasyonudur. Herpes zoster oftalmikusun ayırıcı tanısı, başlangıcı ve morbitidesinden dolayı acil hekimleri için önemlidir.

**Anahtar Kelimeler:** Herpes zoster, oftalmikus, acil servis  
**Geliş Tarihi:** 04.07.2011 **Kabul Tarihi:** 04.11.2011

### Introduction

Herpes zoster (HZ) is a common diagnosis in the emergency department (ED), but herpes zoster ophthalmicus (HZO) is a rare form of shingles that typically presents with prodromal symptoms followed by a rash distributed along the V1-V2 dermatomes (1). Herpes zoster occurs frequently in immunocompromised patients, such as the elderly and those with lymphoproliferative malignancies, AIDS, diabetes and in transplant recipients (2). Classically, HZO begins with flu-like symptoms including fever, myalgia and malaise for approximately one week (3). In the current case, we describe a woman who presented to our medical center with a headache and rash on the right forehead.

### Case Report

A 71-year-old woman presented to her primary care physician four days before with a new-onset headache on the right side and a complaint of rash and itching after a black stain formed on her forehead. She had been given methylprednisolone cream. One day later, she presented to the same clinic again and cefasoline sodium, levocetirizine and tobramycin ophthalmic drops were prescribed. Three days later, the patient referred to our ED with a preliminary diagnosis of angioedema when she presented with a swollen eyelid. She did not complain of blurry vision, diplopia or visual loss. Upon questioning, she denied any recent history of sick contacts or trauma to the face or eye, chemical exposure or any new drug use. She had suffered from diabetes mellitus for ten years.

### Address for Correspondence/Yazışma Adresi:

Dr. Mustafa Burak Sayhan, Department of Emergency Medicine, Faculty of Medicine, Trakya University, Edirne, Turkey  
Phone: +90 532 700 00 95 E-mail: mustafaburak@yahoo.com

©Copyright 2012 by Emergency Physicians Association of Turkey - Available on-line at www.jaemcr.com  
©Telif Hakkı 2012 Acil Tıp Uzmanları Derneği - Makale metnine www.jaemcr.com web sayfasından ulaşılabilir.

Physical examination at the bedside revealed that the patient was alert and properly oriented. Her vital signs were within normal limits. Eye examination was also normal. A tender, erythematous, non-vesicular, crusting lesion was noted on the periorbital skin. Intense edema was seen on the eyelids of the right eye causing the closure of the eye and edema was also seen on the left eye. Indirect fundoscopic examination was normal (Figure 1a, b).

The patient's laboratory tests were within normal limits, except for an elevated glucose level of 363 mg/dL and erythrocyte sedimentation rate of 34 mm/h. An ophthalmological consultation was performed and a topical steroid was suggested. A dermatological consultation was performed upon admission to the hospital for treatment and observation. The patient was discharged from the hospital after ten days and recovered fully.

### Discussion

VZV, a member of the Herpesviridae family, is a double-stranded DNA virus characterized by an extremely short reproductive cycle (a few hours). After primary infection, VZV establishes a latent infection in sensory nerve root ganglia (4). VZV is a herpes virus that causes two distinct clinical syndromes. Varicella (chickenpox), the primary infection, is a common, extremely contagious and usually benign illness that occurs in epidemics (5). However, widespread varicella vaccination may change the epidemiology of HZ (6). The incidence of HZ infection among persons older than 75 years of age exceeds 10 cases per 1000 persons annually (2). HZO occurs when HZ presents in the ophthalmic division of the fifth cranial nerve. Ocular involvement occurs in approximately 50% of HZ patients without the use of antiviral therapy (6).

HZO represents between 10% and 25% of all cases of HZ, and there is a risk of vision loss in the affected eye in approximately half of HZO cases (4). Classically, involvement of the tip of the nose (Hutchinson's sign) has been thought to be a clinical predictor of ocular involvement (7). In the present case, it is unknown whether she had contracted varicella earlier in life, but it was learned that she had

been vaccinated. She was 71 years old same as the literature. There was no involvement of the tip of the nose, but lesions were seen at the root of the nose. There was no loss of vision.

Risks for reactivation include any decline in the T-cell mediated immune response including that caused by normal aging, human immunodeficiency virus/acquired immunodeficiency syndrome (HIV/AIDS) and immunosuppressive medications (5). Soyuncu et al. (2) reported in a clinical survey that there is a relationship between the presence of HZ and increasing age and cell-mediated immunosuppressive disorders in ED patients over the age of 45 years old. HZ should be considered as an indicator of cell-mediated immunosuppressive disorders, particularly in elderly patients.

Commonly reported complications of HZ infection include VZV pneumonia, encephalitis and hepatitis. The mortality associated with disseminated HZ has been substantially reduced by the availability of effective antiviral therapy (8). In the present case, our patient was 71 years old and she had diabetes. No other complications were seen.

Classically, HZO begins with flu-like symptoms including fever, myalgia and malaise for approximately one week. Typically, patients then develop a painful unilateral dermatome rash in the distribution of one or more branches of V1: supraorbital, lacrimal or nasociliary (5). HZO is commonly associated with ocular complications such as keratitis, iridocyclitis, muscular palsies and optic neuritis in approximately one half of cases (9). In the present case, the patient presented to our ED with a preliminary diagnosis of angioedema when she presented with a swollen eyelid. Further ocular complications were not seen.

Thomas et al. reported on the case of a 64-year-old Chinese man who presented to the ED with five days of increasingly blurry vision in his right eye (5). Our patient was admitted to our ED with a preliminary diagnosis of angioedema when she presented with a swollen eyelid. She did not complain of blurry vision, diplopia or

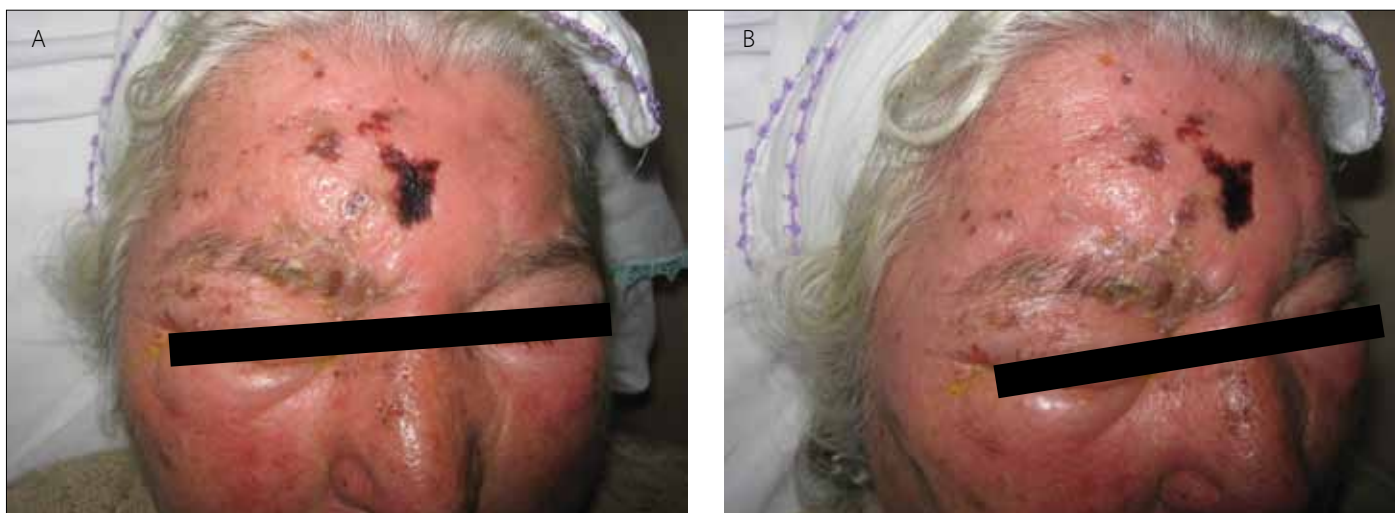


Figure 1a, b. Intense edema was seen on the eyelids of the right eye causing the closure of the eye. Edema of the left eye was also observed

visual loss. Lorenza et al. reported on a large clinical survey including 929 patients from 1993 through 2003, finding that some disease was detected in 55 of 776 patients referred for angioedema without urticaria. However, true angioedema of the lips diagnosed as a recurrence of herpes simplex type 1 infection was seen in only one woman; in another patient, angioedema had been present during a herpes zoster (shingles) outbreak (10).

The differential diagnosis of eyelid edema is extensive, but knowledge of the key features of several potential causes can assist physicians in diagnosing this condition. Angioedema is often but not always bilateral, with an abrupt onset over minutes to hours which may follow exposure; scaling is usually absent. HZO is seen in older adults and vesicles are often present, with pain or burning with an onset of hours to days (11). In the present case, a tender, erythematous, non-vesicular, crusting lesion was noted on the periorbital skin. Intense edema was seen on the eyelids of the right eye, causing the closure of the eye, and edema was also seen in the left eye.

Diagnostic testing is rarely indicated as diagnosis can almost always be made by a combination of history and physical examination. It is possible to use a Tzanck smear or Wright stain to determine whether lesions contain herpes-type virus (although these will not differentiate between VZV and other herpes viruses). Viral culture, direct immunofluorescence assays or PCR may also be used to confirm the diagnosis (5). In the present case, HZO was diagnosed by physical examination and history.

The goal of therapy is to limit the severity of acute and chronic pain, hasten the healing process and reduce the chances of dissemination. Antiviral therapies in the form of acyclovir (800 mg orally five times daily for 7 to 10 days), valacyclovir (1000 mg orally three times daily for 7 days) and famciclovir (500 mg orally three times daily for 7 day) are approved by the US Food and Drug Administration for the management of herpes zoster (1). To be effective, antiviral medication needs to be started within 72 h of the onset of acute symptoms. Antiviral agents show limited efficacy if administered within 72 h of acute symptom onset (12). In the present case, local wound care, pain control, initiation of antiviral medication and antibiotics were given. Acyclovir was started within 72 hours of the appearance of the initial symptoms.

The main complications of HZ include post-herpetic neuralgia (PHN) and ophthalmic problems, the latter in cases of ophthalmic HZ. Post-herpetic neuralgia is usually defined as pain in the involved dermatome that is still present a month after rash onset (13). The risk of post-herpetic neuralgia increases markedly with age (14). Early

initiation of tricyclic antidepressants (desipramine [Norpramin], 25 to 75 mg at bedtime) may inhibit post-herpetic neuralgia (11). Our patient did not complain of neuralgia.

The complications of HZ will become even less common as use of the varicella vaccine becomes more widespread (8). However, we determined that our patient had been vaccinated.

## Conclusion

HZO is a potentially serious reactivation of VZV in the distribution of the ophthalmic division of the trigeminal nerve. The differential diagnosis of HZO is an important task for emergency physicians because of its rapid onset and severity.

## Conflict of interest

No conflict of interest was declared by the authors.

## References

1. Delengocky T, Bui CM. Complete ophthalmoplegia with pupillary involvement as an initial clinical presentation of herpes zoster ophthalmicus. *J Am Osteopath Assoc* 2008; 108: 615-21.
2. Soyuncu S, Berk Y, Eken C, Gulen B, Oktay C. Herpes zoster as a useful clinical marker of underlying cell-mediated immune disorders. *Ann Acad Med Singapore* 2009; 38: 136-8.
3. Whitley RJ. A 70-year-old woman with shingles: review of herpes zoster. *JAMA* 2009; 302: 73-80. [\[CrossRef\]](#)
4. Bleibel W, Yi C, Bleibel H, D'Silvia KJ, Hemady N. Extraocular Myositis Preceding Herpes. *Zoster Ophthalmicus*. *Hospital physician* 2006;3:47-50.
5. Catron T, Hern HG. Herpes zoster ophthalmicus. *West J Emerg Med* 2008; 9: 174-6.
6. Liesegang TJ. Herpes zoster ophthalmicus natural history, risk factors, clinical presentation, and morbidity. *Ophthalmology* 2008; 115: 3-12. [\[CrossRef\]](#)
7. Shaikh S, Ta CN. Evaluation and management of herpes zoster ophthalmicus. *Am Fam Physician* 2002; 66: 1723-30.
8. Gnann JW Jr. Varicella-zoster virus: atypical presentations and unusual complications. *J Infect Dis*. 2002; 186: 91-8. [\[CrossRef\]](#)
9. Park KC, Yoon SS, Yoon JE, Rhee HY. A case of herpes zoster ophthalmicus with isolated trochlear nerve involvement. *J Clin Neurol* 2011; 7: 47-9. [\[CrossRef\]](#)
10. Zingale LC, Beltrami L, Zanichelli A, Maggioni L, Pappalardo E, Cicardi B, et al. Angioedema without urticaria: a large clinical survey. *CMAJ* 2006; 175: 1065-70. [\[CrossRef\]](#)
11. Papier A, Tuttle DJ, Mahar TJ. Differential diagnosis of the swollen red eyelid. *Am Fam Physician* 2007; 76: 1815-24.
12. Johnson RW, Bouhassira D, Kassianos G, Leplège A, Schmader KE, Weinke T. The impact of herpes zoster and post-herpetic neuralgia on quality-of-life. *BMC Med* 2010; 8: 1741-5. [\[CrossRef\]](#)
13. Opstelten W, Eekhof J, Neven AK, Verheij T. Treatment of herpes zoster. *Can Fam Physician* 2008; 54: 373-7.
14. Drolet M, Brisson M, Schmader KE, Levin MJ, Johnson R, Oxman MN, et al. The impact of herpes zoster and postherpetic neuralgia on health-related quality of life: a prospective study. *CMAJ* 2010; 182: 1731-6. [\[CrossRef\]](#)