



Total Rectal Prolapse Reduced via Ketamine Administration in the Emergency Department

Acil Serviste Ketamin Uygulaması ile Redükte Edilen Total Rektal Prolapsus

Muzaffer Emre Kesim¹, Yahya Ayhan Acar¹, İbrahim Arzıman¹, Ümit Kaldırım¹, Cengiz Kaya¹, Salih Müjdat Balkan²

¹Department of Emergency Medicine, Gülhane Military Medicine Academy, Ankara, Turkey
²Clinic of General Surgery, TOBB ETU Hospital, Ankara, Turkey

ABSTRACT

Total rectal prolapse (procidencia) is a clinical state in which all layers of the rectum protrude through the anal canal. The etiology is not completely understood. It is an uncommon situation and patients must be diagnosed early; cases should be reduced manually in the emergency department until ischemia occurs in order to decrease complications. Some additional techniques have been presented in the literature in cases of failure using manual reduction. Procedural sedation and analgesia procedure can improve patient comfort and the success rate of manual reduction alone or in addition to these techniques. In this case report, we present a total rectal prolapse reduced after procedural sedation via intravenous ketamine administration in the emergency department.

Keywords: Rectal prolapse, ketamine, emergency service
Received: 04.12.2011 **Accepted:** 09.01.2012

ÖZET

Total rektal prolapsus (prosidencia) rektumun bütün katlarının anal kanaldan sarktığı klinik durumdur. Etiyolojisi tam olarak anlaşılamamıştır. Nadir bir durumdur ve komplikasyonları azaltmak için hastalara acil serviste erken tanı konmalı ve prolapsus iskemisi oluşmadan önce elle redükte edilmelidir. Elle redüksiyonun başırlamadığı durumlar için literatürde bazı teknikler tanımlanmıştır. Prosedürel sedasyon ve analjezi işlemi, hastanın konforunu ve elle redüksiyon başarı oranını tek başına veya bu tekniklere ek olarak kullanıldığı zaman artırabilir. Bu yazıda acil serviste intravenöz ketamin ile prosedürel sedasyon sonrası redükte edilen total rektal prolapsus olgusunu sunduk.

Anahtar Kelimeler: Rektal prolapsus, ketamin, acil servis
Geliş Tarihi: 04.12.2011 **Kabul Tarihi:** 09.01.2012

Introduction

Rectal prolapse occurs when the rectum protrudes through the anal canal, either incompletely or totally. If all rectal layers protrude, it is called a total rectal prolapse (procidencia) (1). It is uncommon in emergency departments, but can have life-threatening complications such as bowel necrosis due to delayed reduction (2). Early recognition and reduction in the emergency department and enhanced analgesia and sedation protocols are needed, especially for patients with difficult reduction.

Case Report

A 23-year-old man was admitted to the emergency department with a painful rectal mass that raised while defecating 15-20 minutes before admission. In his history, it was found that he had been complaining of a mass for ten years but had not sought treatment. In the physical examination, the rectum was prolapsed 10 cm from the dentate line, extremely hyperemic and edematous and vascular structures were marked (Figure 1, 2). The patient declared that he had previously reduced a prolapse himself but could not manage this time. In the emergency department, the first attempt in manual reduction failed because of extreme pain. Then, 100 mg ketamine was administered intravenously and the prolapse was reduced in the sedated patient. Anal tonus was weak in the follow-up examination (Figure 3). The patient was admitted to the general surgery department for surgical treatment.

Discussion

Total rectal prolapse is rare with an unknown real incidence. While all age groups can be affected, there is a peak incidence in the sixth decade and 90% of patients are women (3). The pathophysiology is not clearly understood. There are four main theories: 1) poor bowel habits, 2) laxity of rectal ligaments, 3) a sliding hernia of Douglas and 4) rectal wall intusseption. Patients are usually

Address for Correspondence/Yazışma Adresi:

Dr. Yahya Ayhan Acar, Department of Emergency Medicine, Gülhane Military Medicine Academy, Ankara, Turkey
Phone: +90 532 601 68 09 E-mail: yahyaacar@gmail.com

©Copyright 2012 by Emergency Physicians Association of Turkey - Available on-line at www.jaemcr.com
©Telif Hakkı 2012 Acil Tıp Uzmanları Derneği - Makale metnine www.jaemcr.com web sayfasından ulaşılabilir.

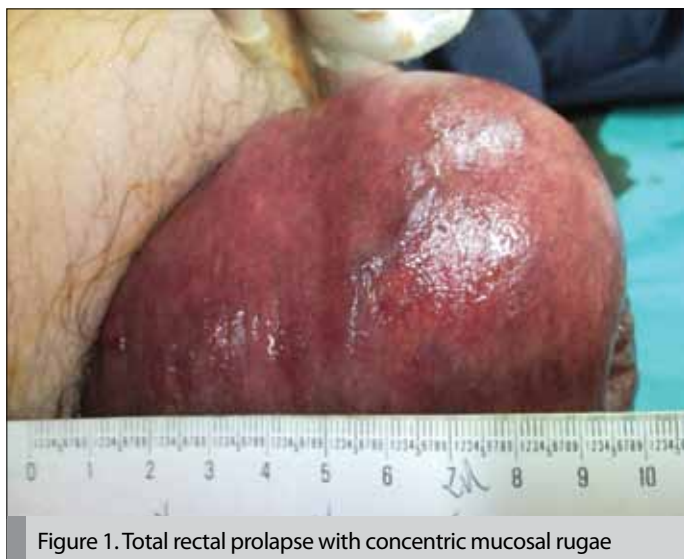

Figure 1. Total rectal prolapse with concentric mucosal rugae

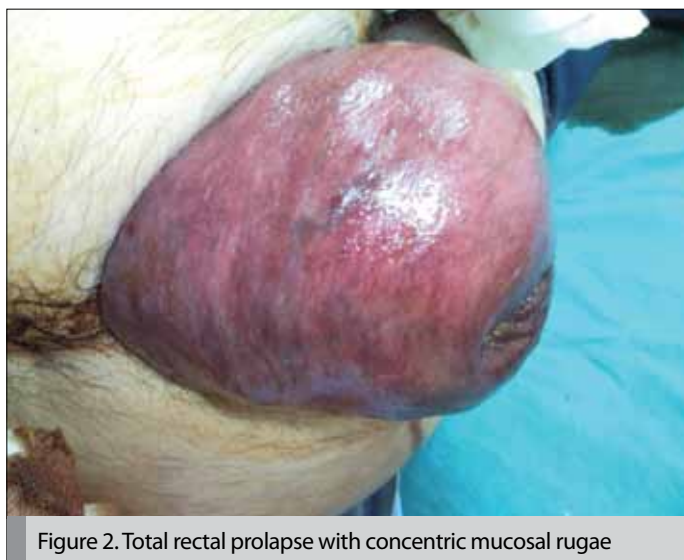


Figure 2. Total rectal prolapse with concentric mucosal rugae

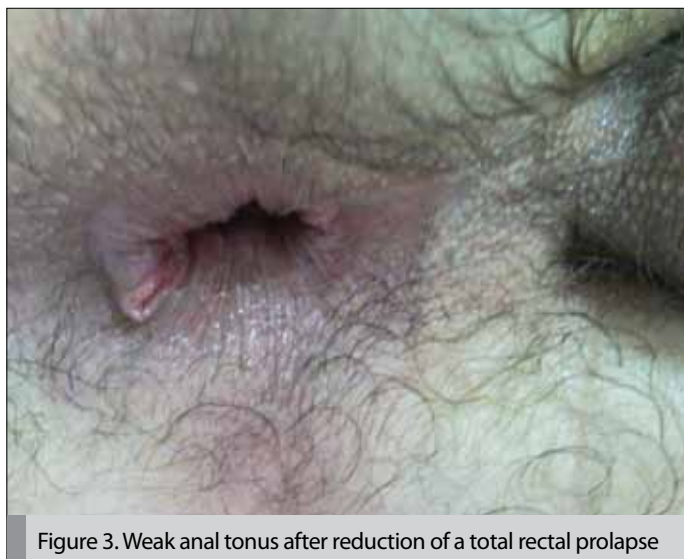

Figure 3. Weak anal tonus after reduction of a total rectal prolapse

aware of a rectal mass, except for some geriatric patients. In the early stages, the prolapse is raised upon defecation and reduces spontaneously. In progressive cases, prolapse can occur with simple daily activities and requires manual reduction. Patients usually complain of mucous drainage, hemorrhage, incontinence and pain. Rectal tonus is usually weak or absent. In a true rectal prolapse, the mucosal rugae are always concentric (3). In the emergency department, manual reduction of a rectal prolapse can be impossible due to extreme edema and pain. Blockage with local anesthesia, local ice and sugar administration or an elastic bandage over the prolapsed mass are some techniques used to facilitate manual reduction. Early reduction of a prolapse can reduce complication rates and enhance elective surgery. Manual reduction must not be attempted in cases with ischemia (1, 4).

Procedural sedation is a technique of administering sedatives (midazolam, propofol) or dissociative agents (ketamine) with or without opioid analgesics (fentanyl, morphine) to induce a state that allows the patient to tolerate unpleasant procedures while maintaining cardiorespiratory function (5). Ketamine hydrochloride is usually used as a sedation agent in the emergency department. It is a phencyclidine derivative that causes dissociation between the cortical and limbic systems, preventing the patient from perceiving sensory stimuli. It has a rapid onset and short duration of action and produces procedural amnesia and analgesia. It has not been associated with high rates of respiratory compromise and is generally thought to be a respiratory stimulant, although some respiratory depression can occur immediately after it is given as an intravenous bolus (6). Reduction of a rectal prolapse is an unpleasant procedure for the patient and can sometimes be impossible without using facilitating techniques. There is no consensus in the literature for the best technique and/or best agent for procedural sedation for the reduction of a rectal prolapse. In our case, the prolapsed edematous rectum was reduced only after intravenous administration of 100 mg ketamine. Further studies in this area are required.

Conclusion

Rectal prolapse is an emergent disease of the rectum. Reduction within a short time period is important in cases without ischemia to reduce complications. However, it has been determined that some facilitating techniques can be used; in our case, intravenous ketamine administration was successful. Additional studies must be done to determine the best agent for procedural sedation before reduction of a rectal prolapse.

Conflict of interest

No conflict of interest was declared by the authors.

References

1. Brian EB. Anorectal disorders. In Judith E. Tintinalli JE, MD, MS, Editor. Tintinalli's Emergency Medicine. 7th ed. New York: McGraw-Hill; 2011: p.597-8.
2. Temiz M, Aslan A, Erdoğan S, Canbolat E. Rektumda yırtık ve aşırı kanamaya sebep olan inkarsere rektal prolapsus. Bakırköy Tıp Dergisi 2008; 4: 166-9.
3. O'Brien DP 4th. Rectal prolapse. Clin Colon Rectal Surg 2007; 20: 125-32. [\[CrossRef\]](#)
4. Sungurtekin U, Sungurtekin H. Srangüle rektal prolapsus- Nadir görülen bir rektal prolapsus komplikasyonu. Kolon Rektum Hast Derg 2008; 18: 184-6.
5. Sener S, Eken C, Schultz CH, Serinken M, Ozsarac M. Ketamine with and without midazolam for emergency department sedation in adults: a randomized controlled trial. Ann Emerg Med 2011; 57: 109-16. [\[CrossRef\]](#)
6. Miner JR, Gray RO, Bahr J, Patel R, McGill JW. Randomized clinical trial of propofol versus ketamine for procedural sedation in the emergency department. Acad Emerg Med 2010; 17: 604-11. [\[CrossRef\]](#)