



Bilateral Iliopsoas Muscle Hematoma and Hemorrhage Secondary to a Coughing Attack in a Patient with Hemophilia A: A Case Report

Hemofili A Hastasında Öksürük Atağı Sonrası Gelişen Bilateral İliopsoas Kasında Hematom ve Hemoraji: Olgu Sunumu

Ferhat İçme¹, Murat Daş¹, Orhan Delice¹, Mehmet Yılmaz¹, İmdat Dilek², Nalan Kozacı³

¹Department of Emergency Medicine, Ankara Atatürk Education and Research Hospital, Ankara, Turkey

²Department of Hematology, Ankara Atatürk Education and Research Hospital, Ankara, Turkey

³Department of Emergency Medicine, Adana Numune Education and Research Hospital, Adana, Turkey

ABSTRACT

Hemophilia A is an X-linked recessive disease characterized by defective or dysfunctional deficiency of factor VIII in the circulation. The incidence of factor VIII deficiency is lower than the incidence of vWD but it is the most common hereditary factor deficiency among the others. The prevalence of factor VII deficiency is approximately 1/10,000 in liveborn babies. There are three clinical types defined as light, medium and severe. In patients with severe clinical type hemarthrosis and other bleeding, which require factor replacement, may occur from birth. In these patients hemorrhage may occur spontaneously or secondary to trauma. However, severe muscle hemorrhage either spontaneous or secondary to minor trauma is rarely seen. In this report we present a 46 year old male patient with hemophilia A who applied to the emergency service because of abdominal pain following a coughing attack and a swelling on the left side. We detected hemorrhage and hematoma in bilateral iliopsoas muscle which developed due to a previous coughing attack.

Keywords: Hemophilia A, iliopsoas hematoma, cough

Received: 25.10.2011 **Accepted:** 18.01.2012

ÖZET

Hemofili A dolaşımdaki faktör VIII in defektif veya disfonksiyonel sentezi eksikliği ile karakterli X'e bağlı resesif geçişli bir hastalıktır. Faktör VIII eksikliği, vWH sıklığından daha az ancak diğer herediter faktör eksikliklerinin en sık olanıdır. Sıklığı canlı doğan bebeklerde 1/10,000 civarındadır. Hafif, orta ve ağır olmak üzere 3 klinik tipi vardır. Klinik tipi ciddi olanlarda doğumdan itibaren faktör replasmanı gerektiren hematrozlar ve diğer kanamalarda görülebilir. Bu olgularda kanamalar travma sonrası yada spontan olabilir. Fakat spontan veya minör travmayla ciddi kas içi kanama görülmesi nadirdir. Burada öksürük atağını takiben karın ağrısı ve sonrasında sol yan tarafında oluşan şişlik nedeniyle acil servise başvuran ve bilateral iliopsoas kasında hematom saptanan 46 yaşında bir hemofili A olgusu sunuldu.

Anahtar Kelimeler: Hemofili A, iliopsoas hematomu, öksürük

Geliş Tarihi: 25.10.2011 **Kabul Tarihi:** 18.01.2012

Introduction

Hemophilia is a serious hereditary blood disorder, which has been humanity's problem for many years. Hemophilia has been transmitted from generation to generation since 10,000 BC and continued up to modern times. It can be seen all over the world and in every race equally. It is reported that the prevalence of hemophilia A is approximately 1/10,000 in live born male babies and it constitutes 85% of all hemophilia patients (1, 2).

Factor VIII deficiency is studied in 3 groups according to the degree of deficiency. The patients with level of factor VIII lower than 1% are defined as severe, levels between 1-5% are defined as moderate and patients with factor levels over 5% are defined as mild (1). This definition, generally but not always, also parallels the clinical appearance: the lower the level of factor VIII, the high-

Address for Correspondence/Yazışma Adresi:

Dr. Ferhat İçme, Department of Emergency Medicine, Ankara Atatürk Education and Research Hospital, Ankara, Turkey
Phone: +90 532 569 17 19 E-mail: ferhaticme@gmail.com

©Copyright 2013 by Emergency Physicians Association of Turkey - Available on-line at www.jaemcr.com
©Telif Hakkı 2013 Acil Tıp Uzmanları Derneği - Makale metnine www.jaemcr.com web sayfasından ulaşılabilir.



er the risk of bleeding (3). In the history of the patient, bleeding may be observed beginning from the newborn period according to the degree of the disease and patients are often diagnosed because of intractable bleeding during circumcision. Severe bleeding into the joints and muscles constitutes the most important part of the clinical aspect in terms of morbidity and mortality. Hemarthrosis constitutes approximately 70-80% of these severe bleeding episodes, whereas the incidence of hemorrhage in the muscle is 10-25% (4). Hemarthrosis develops most commonly in the knee and elbow joints, and hematomas develop in iliopsoas, calf and thigh muscles.

In this article we aimed to present a hemophilia A patient who applied to the emergency service with abdominal pain aggravated by minor trauma two days previously secondary to a coughing attack and swelling on the left side which occurred two hours before admission to ED. We detected hemorrhage and hematoma in bilateral iliopsoas muscle which we considered had developed due to a previous coughing attack.

Case Report

A forty-six-year-old male patient was admitted to the emergency department because of aggravation of abdominal pain, which began 2 days earlier and a swelling on the left side. The patient was hospitalized with the diagnosis of pneumonia 10 days previously and discharged with a prescription for antibiotic treatment. The patient said that his complaints of coughing continued after he was discharged, and the abdominal pain started 2 days earlier after an episode of coughing.

The patient's medical history revealed that he had been diagnosed with hemophilia A when he was 4 years old, he had bleeding in the knee, elbow and hip joints secondary to minor traumas, and after he was 25 years old when he enrolled in a prophylaxis program he had had no serious bleeding. In the physical examination the patient was conscious, and his general condition was moderate. Vital findings were normal except for tachycardia (110 beats/min). There was an overall sensitivity in the abdominal region, and there was a palpable mass of about 3x4 cm in size in the left hypochondrial region. The patient explained that the mass had been present for approximately 2 hours and had been growing. Biochemical markers revealed no significance. In complete blood count, white blood cell was 14.800 K/uL, hemoglobin 12.6 g/dL, hematocrit 37.3%, RBC 4.12 M/uL, and platelets 483.000 m/uL, respectively. Bleeding parameters were a PTT 66.1 sec, PT 13.4 sec and INR 1.2 respectively.

In the complete abdominal CT scan, diffuse hemorrhagic foci in two iliopsoas muscles which caused significant expansion, and edema; a loculated hemorrhagic area of 58x36 mm dimensions adjacent to the lateral side of the left iliopsoas muscle; and free fluid around both iliopsoas muscles, perirenal areas, and paracolic areas were detected (Figure 1, 2). The patient was hospitalized in the hematology department. In the hematology department, factor VIII at a dose of 40 U/kg was administered as replacement therapy, and analgesic medication administered additionally. 20 U/kg factor VIII was continued to be given every 12 hours for the next 13 days. The patient was discharged on the 14th day of admission upon regression of the hematoma and stable course of the hematocrit on follow-up, and a 20 U/kg factor VIII daily dose was prescribed. On the outpatient

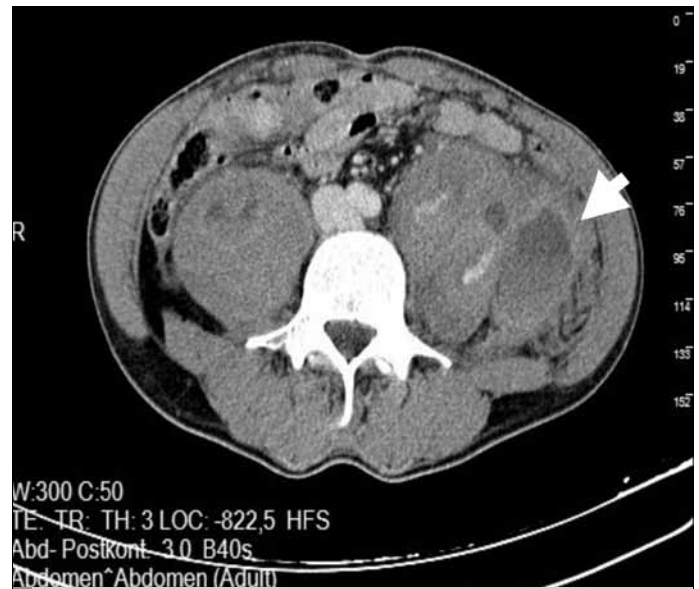


Figure 1. Hematoma in the left iliopsoas muscle

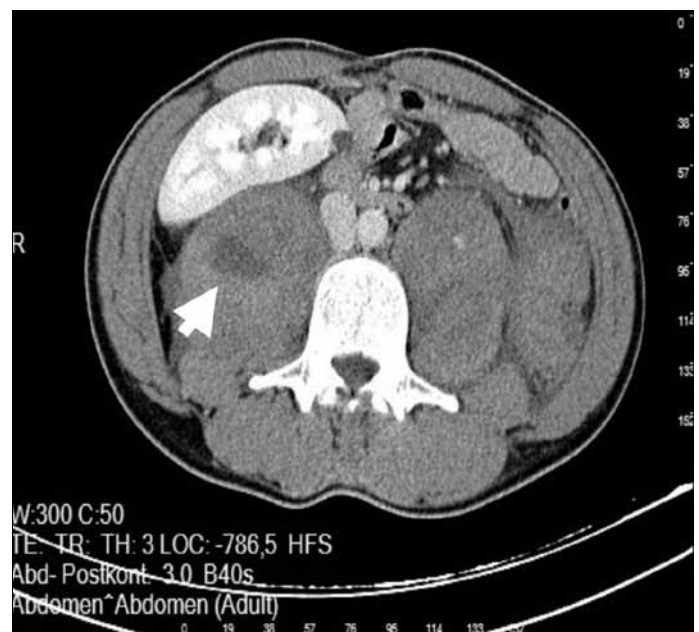


Figure 2. Hematoma in the right iliopsoas muscle

follow-up hematoma had decreased and disappeared on the 65th day of discharge.

Discussion

The most important complications of bleeding disorders in patients with hemophilia A are hemarthrosis and hematomas. Chronic synovitis, arthropathy, osteoporosis, and fractures are observed less frequently (4). Bleeding of the musculoskeletal system makes up to 80% of all bleeding, and intra-articular hemorrhage (70-80%), and intramuscular hemorrhage (10-25%) constitute the most important part in this (4). Intra-articular hemorrhage may occur spontaneously or may be caused by minor trauma and is an important cause of morbidity. Intramuscular hemorrhage could also create serious morbidity, and can be life threatening. The most important cause

of intramuscular hemorrhage is local trauma, and may rarely occur spontaneously or secondary to minor trauma (5). As in our case, the hematoma in the iliopsoas muscle caused by simply coughing without any local trauma and affecting both iliopsoas muscles is rarely seen. The bleeding often involves the iliopsoas muscle (55%), as in our patient, and more rarely the calf muscle (18%) and thigh muscle (18%) (6).

Hemorrhage in the iliopsoas muscle heals slowly and may cause serious morbidity. In patients with hemophilia A mortal bleeding is rarely seen except in intracranial bleeding. In these patients there is often hip flexion contracture, and lumbar lordosis is increased to compensate it. There is pain also in the groin. This pain is usually less severe than the pain of intra-articular hemorrhage. The pain may spread in the iliac fossa and on top of the thighs. The front of the hip may become sensitive. Femoral nerve compression occurs in 37% of iliopsoas hemorrhage, and loss of sensation on the front of the thigh, significant reduction of power in the quadriceps muscle and loss of the patellar reflex can be detected (7). In our patient, there was only abdominal pain. As in our case, early initiation of replacement therapy may prevent the growth of the hematoma and can reduce any neurological deficit or other complications.

The most appropriate diagnostic methods for iliopsoas hemorrhage are CT, MRI and USG (8).

In our patient, we obtained an abdominal tomography initially, in order to define the focus of bleeding, and rule out the presence of a hemorrhage in the retroperitoneal area. Then a follow-up for bleeding was performed with ultrasound.

Many recent observational studies have revealed the superiority of prophylactic treatment on on-demand treatment (treatment when bleeding occurs or episodic therapy), especially for hemophilia patients in childhood. For these patients, "primary prophylaxis" is seen as the most effective and safe treatment modality (9, 10). Our patient had not received any regular prophylactic therapy up to the age of 25 years, although he (had had developed serious bleedings in the knee, elbow and hip joints. In our patient, who received a regular prophylaxis program after he was 25 years old, the absence of a serious bleeding so far shows the effectiveness of regular prophylaxis.

A general principle in managing major or life-threatening bleeding in a hemophilic patient is early and complete factor replacement, before or at the same time as other diagnostic maneuvers (1). Factor replacement therapy is effective in controlling hemorrhage in hemophilia. Currently, plasma-derived concentrated factor VIII replacement, as in our case, or recombinant factor VIII preparations, which are becoming widely available, are treatment options for replacement therapy in hemophilia A patients. Although rare, replacement therapy with FFP may be available when these modalities are unavailable.

The dosage regimen of factor VIII in the hemophilic patient depends on the location of the hemorrhage and the clinical situation. The half-life of Factor VIII is approximately 8 to 12 hours. When major bleeding occurs in the central nervous system, GI tract, neck, throat, a large muscle, or when a severe injury is present, factor replace-

ment levels between 80% and 100% are necessary. In cases of hemarthrosis increasing the factor levels 30% may be sufficient (11). In our case 40 U/kg plasma derived factor VIII treatment was started immediately after the diagnosis. Then we continued the replacement therapy with dose modification (2 times a day 20 U/kg) and the patient was discharged on the 14th day (2x1 20 U/kg factor VIII prescribed).

In recent years the use of factors and monitoring of the patient's health regularly in the treatment of young patients with hemophilia, have become a accepted regimen for preventing various bleeding, sequelae, and formation of inhibitory conditions which may caused by this disease.

Conclusion

Although rates of complications can be decreased by regular follow-up and treatment in hemophilia patients; these patients may apply to ED at any time. The hemophilia patients with articular or abdominal pain should be evaluated more carefully. The necessity of starting the first dose immediately before diagnostic tests should always be considered and unnecessary procedures and tests should be avoided. Hospital facilities should be kept in a position to treat patients with hemophilia 7 days and 24 hours.

Conflict of interest

No conflict of interest was declared by the authors.

References

1. Manson W, Hemphill RR, Kempton CL. Hemophilias and von Willebrand Disease. In Tintinalli JE, Kelen GD, Stapczynski JS Emergency Medicine A Comprehensive Study Guide. 7th ed. New York: McGraw-Hill; 2010:1475-80.
2. Williams WJ, Beutler E, Erslev AJ, Lichtman M. Classification of Disorders of Hemostasis. Hematology, New York: Mc Graw-Hill Publishing, 1991: 1338-9.
3. Greene WB, Mc Milan CW. Nonsurgical management of hemophilic arthropathy. Instr Course Lect 1989; 38: 367-81.
4. Hassan TH, Badr MA, Fattah NRA, Badawy SM. Assessment of musculoskeletal function and mood in haemophilia A adolescents: a cross-sectional study. Haemophilia 2011; 17: 1-6. [CrossRef]
5. Battistella LR. Maintenance of musculoskeletal function in people with haemophilia. Haemophilia 1998; 4: 26-32. [CrossRef]
6. Beyer R, Ingerslev J, Sorensen B. Current practice in the management of muscle haematomas in patients with severe haemophilia. Haemophilia 2010; 16: 926-31. [CrossRef]
7. Çapacı K. Hemofilik hastalarda kas-iskelet sistemi sorunları ve fizik tedavi rehabilitasyon olanakları. 8. Ulusal hemofili kongresi kongre metinleri. 2011; 138-55. http://www.hedef-tr.org/content/8ulusal_kongre/8_ulusal_kongre_kitap.pdf.
8. Ashrani AA, Osip J, Christie B, Key NS. Iliopsoas haemorrhage in patients with bleeding disorders-experience from one centre. Haemophilia 2003; 9: 721-6. [CrossRef]
9. Steen Carlsson K, Hojgard S, Glomstein A, Lethagen S, Schulman S, Tengborn L, et al. On-demand vs. prophylactic treatment for severe haemophilia in Norway and Sweden: differences in treatment characteristics and outcome. Haemophilia 2003; 9: 555-66. [CrossRef]
10. Aledort LM, Haschmeyer RH, Pettersson H. A longitudinal study of orthopaedic outcomes for severe factor-VIII-deficient haemophiliacs. J Intern Med 1994; 236: 391-9. [CrossRef]
11. Bjorkman S, Berntorp E. Pharmacokinetics of coagulation factors: clinical relevance for patients with haemophilia. Clin Pharmacokinet 2001; 40: 815. [CrossRef]