



# Isolated Nominal Aphasia: Two Case Reports

## İzole Nominal Afazi: İki Olgu Sunumu

Umut Yücel Çavuş<sup>1</sup>, Ertan Sönmez<sup>2</sup>, Sema Avcı<sup>1</sup>, Sinan Yıldırım<sup>1</sup>, Metin Bircan<sup>3</sup>

<sup>1</sup>Clinic of Emergency Medicine, Dışkapı Yıldırım Beyazıt Training and Education Hospital, Ankara, Turkey

<sup>2</sup>Department of Emergency Medicine, Faculty of Medicine, Bezmialem Vakıf University, Istanbul, Turkey

<sup>3</sup>Department of Emergency Medicine, Adnan Menderes University Practice and Research Hospital, Aydın, Turkey

### ABSTRACT

Anomia is a problem with naming objects. This may be a result of injury to the parietal or temporal lobes of the brain. In stroke patients, isolated speech failure occurs rarely. In this report, we wish to emphasize that anomic aphasia can occur in rare conditions and emergency physicians can easily miss diagnose this because of the lack of any other neurological symptom.

**Keywords:** Isolated, nominal, aphasia

**Received:** 05.09.2012 **Accepted:** 14.12.2012

**Available Online Date:** 20.05.2013

### ÖZET

Anomi, objeleri isimlendirmedeki problem olarak tanımlanır. Bu durum genellikle beynin pariyetal ya da temporal lobunda meydana gelen hasar sonucu oluşur. Strok hastalarında izole konuşma bozukluğu nadiren meydana gelir. Bu olgu sunumunda, nadir görülen ve acil hekimleri için diğer nörolojik semptomların yokluğunda kolayca atlanabilecek bir durum olan nominal afaziyi vurgulamayı amaçladık.

**Anahtar Kelimeler:** İzole, nominal, afazi

**Geliş Tarihi:** 05.09.2012 **Kabul Tarihi:** 14.12.2012

**Çevrimiçi Yayın Tarihi:** 20.05.2013

### Introduction

The denomination of objects is a complex cortical procedure which is somehow effortless just peculiar to people (1-3). A problem with retaining and recalling words and names is a type of aphasia called anomia (4). It is caused by an injury to various parts of the parietal or temporal lobes of the brain. Trauma, stroke or tumors can cause this damage (5). Isolated speech disorders may rarely occur, although motor loss, cranial nerve involvement, loss of sensation, etc. are the traditional symptoms of stroke. This type of event can be quite complex, and usually involves a defect in one or more pathways between different parts of the brain. Herein, we report two cases admitted to the emergency department suffering from isolated anomic aphasia.

### Case Reports

#### Case 1

A 25-year-old male patient presented to the hospital complaining that he could not remember his wife's name and the names of objects. Neurologic assessment was found to be normal, except for nominal aphasia, i.e. the patient could not remember the words for pencil, key, glasses, etc. Cerebral computed tomography (CCT) scanning reported a left temporoparietal parenchymal hematoma with vasogenic edema and central heterogeneity (Figure 1). Also, cerebral magnetic resonance imaging (MRI) reported an intratumoral hemorrhage in the left temporoparietal lobe (Figure 2). Therefore, the patient underwent a neurosurgical operation. The presence of tumor was confirmed during surgery. No complications were observed after surgery. Nominal aphasia recovered and the patient was later discharged.

#### Case 2

A 62-year-old female patient presented to the hospital complaining that she could not remember her children's names. When she woke up in the morning, her speech was nonsensical. During the examination, she knew her relatives but simply could not remember their names. Assessment of the patient's vital findings and general physical examination were normal. Neurologic assessment was found to be normal except for nominal aphasia. Diffusion MRI scanning reported areas of restricted diffusion in the left temporoparietal lobe (Figure 3). The patient was admitted to the neurology department and was given antiaggregant treatment. After treatment, her symptoms resolved completely. The patient was discharged with 75 mg clopidogrel daily.



**Address for Correspondence/Yazışma Adresi:**

Dr. Umut Yücel Çavuş, Kardelen Mah. 2040 Sok. Batıpark Konutları A Blok No: 46 Batıkent, Ankara, Turkey

Phone: +90 505 264 80 50 E-mail: acildrumut@yahoo.com

©Copyright 2013 by Emergency Physicians Association of Turkey - Available online at [www.jaemcr.com](http://www.jaemcr.com)

©Telif Hakkı 2013 Acil Tıp Uzmanları Derneği - Makale metnine [www.jaemcr.com](http://www.jaemcr.com) web sayfasından ulaşılabilir.

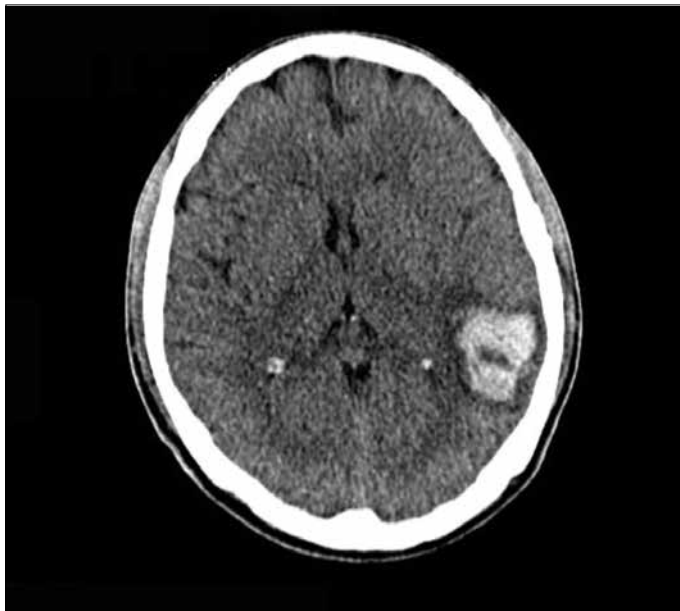


Figure 1. Left temporoparietal parenchymal hematoma with vasogenic edema and central heterogeneity on CCT.

## Discussion

Failure in naming can be the result of an impairment in object recognition with associative agnosia, in word comprehension such as in Wernicke's aphasia, in lexical retrieval as in the case of the tip-of-the-tongue phenomenon or in phonological encoding represented by phonemic paraphasias (6, 7). Many researchers have found contributing factors to anomia, although the main causes of anomic aphasia are not specifically known (5). It is obvious that people with damage to the left hemisphere of the brain are more likely to have anomic aphasia. Current studies have shown that damage to the left parietal lobe is the epicenter of anomic aphasia, although many experts believe that damage to Broca's area or Wernicke's area are the main causes of anomia (8). New data has shown that although the arcuate fasciculus's main duties do not comprise connecting Wernicke's area and Broca's area, any damage to this tract causes speech problems because the speech comprehension and utterance production areas are connected by this tract (8, 9). Our cases presented isolated nominal aphasia and were diagnosed left temporoparietal damage due to an intracerebral tumor or infarct.

## Conclusion

It should not be forgotten that isolated nominal aphasia can be easily confused by the physician. In emergency conditions, this could be the only symptom of important diseases. Therefore, in the emergency department, motor, sensory, balance and cranial nerve examinations should be performed, and the ability to name objects should be assessed during the neurological examination.

## Conflict of Interest

No conflict of interest was declared by the authors.

Peer-review: Externally peer-reviewed.

## Author Contributions

Concept - U.Y.Ç.; Design - U.Y.Ç.; Supervision - U.Y.Ç.; Funding - S.A.; Materials - S.A.; Data Collection and/or Processing - S.A., S.Y.; Analysis and/or Interpretation - E.S.; Literature Review - S.Y., M.B.; - U.Y.Ç., S.A.; Critical Review - E.S.

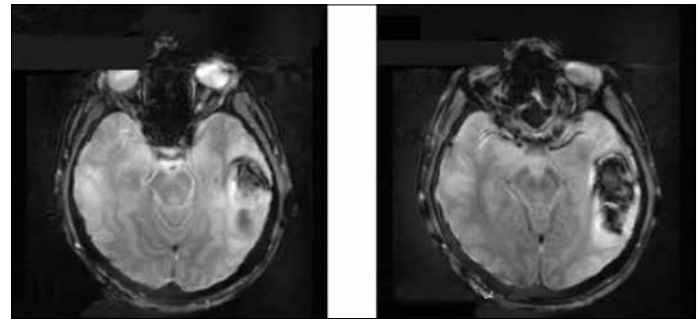


Figure 2. Intratumoral hemorrhage in the left temporoparietal lobe on MRI

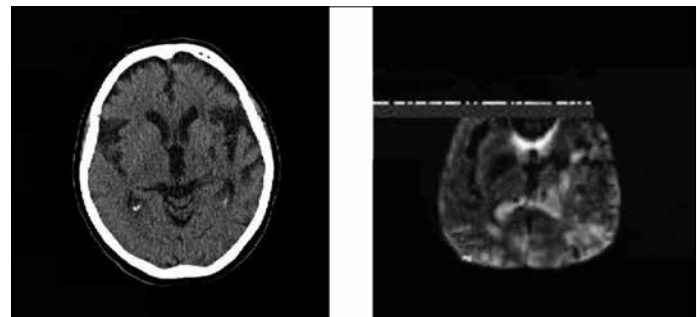


Figure 3. Restricted diffusion in the left temporoparietal lobe by diffusion MRI

## Çıkar Çatışması

Yazarlar herhangi bir çıkar çatışması bildirmemişlerdir.

Hakem değerlendirmesi: Dış bağımsız.

## Yazar Katkıları

Fikir - U.Y.Ç.; Tasarım - U.Y.Ç.; Denetleme - U.Y.Ç.; Kaynaklar - S.A.; Malzemeler - S.A.; Veri toplanması ve/veya işlemesi - S.A., S.Y.; Analiz ve/veya yorum - E.S.; Literatür taraması - S.Y., M.B.; Yazıyı yazan - U.Y.Ç., S.A.; Eleştirel inceleme - E.S.

## References

1. Damasio H, Tranel D, Grabowski T, Adolphs R. Neural systems behind word and concept retrieval. *Cognition* 2004; 92: 179-229. [CrossRef]
2. De Leon J, Gottesman RF, Kleinman JT, Newhart M, Davis C, Heidler Gary, et al. Neural regions essential for distinct cognitive processes underlying picture naming. *Brain* 2007; 130: 1408-22. [CrossRef]
3. Levelt WJ, Roelofs A, Meyer AS. A theory of lexical Access in speech production. *Behav Brain Sci* 1999; 22: 1-38. [CrossRef]
4. Collins English Dictionary. Complete and Unabridged 10th Edition. 2009.p.232.
5. Fridriksson J, Moser D, Ryalls J, Bonilha L, Rorden C, Baylis G, et al. Modulation of frontal lobe speech areas associated with the production and perception of speech movements. *Speech Lang Hear Res* 2009; 52: 812-9. [CrossRef]
6. Beauvois MF. Optic aphasia: a process of interaction between vision and language. *Philos Trans R Soc Lond B Biol Sci* 1982; 298: 35-47. [CrossRef]
7. Farah MJ, Wallace MA. Semantically-bounded anomia: implications for the neural implementation of naming. *Neuropsychologia* 1992; 30: 609-21. [CrossRef]
8. Fridriksson J, Kjartansson O, Morgan PS. Impaired speech repetition and left parietal lobe damage. *J Neurosci* 2010; 30: 11057-61. [CrossRef]
9. Anderson JM, Gilmore R, Roper S. Conduction aphasia and the arcuate fasciculus: A reexamination of the Wernicke-Geschwind model. *Brain Lang* 1999; 70: 1-12. [CrossRef]