



Complete Heart Block Related to Mumps Myocarditis in an 80-Year-Old Woman

80 Yaşındaki Bir Kadında Kabakulak Miyokarditine Bağlı Tam Blok

Şerife Özdiñç¹, Mustafa Tekin², Gülay Özkeçeci³, Gülşah Aşık⁴, Oya Oruç¹

¹Department of Emergency Medicine, Afyon Kocatepe University Faculty of Medicine, Afyonkarahisar, Turkey

²Department of Emergency Medicine, Afyonkarahisar State Hospital, Afyonkarahisar, Turkey

³Department of Cardiology, Afyon Kocatepe University Faculty of Medicine, Afyonkarahisar, Turkey

⁴Department of Microbiology, Afyon Kocatepe University Faculty of Medicine, Afyonkarahisar, Turkey

ABSTRACT

Introduction: Mumps is an acute, self-limited, highly infectious, systemic viral disease characterized by a swelling of the parotid glands. It is more common in school-aged children. We want to emphasize in this case report that mumps can also occur in old people and cause a mortal and rare complication such as complete AV block associated with mumps myocarditis.

Case Report: An 80-year-old woman admitted to the emergency room with complaints of swelling around the right ear, fatigue, weakness, dizziness, presyncope, and chest pain. Her grandson had had a fever and swelling around the right and left ear approximately 2 weeks before the beginning of her own ailment. Her core temperature was 37.5°C. Blood pressure was 120/60 mmHg and pulse rate was 37 beats/min. There was swelling of the right parotid gland and complete atrioventricular block in her electrocardiogram. The patient was consulted with a cardiologist and transferred to the cardiology clinic.

Conclusion: Mumps is most commonly occurs in children, and the most common presentation of the disease is parotitis. However, it may occur in elders and result in mortal complications.

Keywords: Bradycardia, complete atrioventricular block, elderly patients, emergency room, mumps, myocarditis

Received: 29.01.2015 **Accepted:** 25.03.2015

Available Online Date: 09.04.2015

ÖZET

Giriş: Kabakulak, parotis bezlerinde şişlikle karakterize, akut, kendi kendini sınırlayan, oldukça bulaşıcı, sistemik viral bir hastalıktır. Sıklıkla okul çağı çocuklarında görülür. Bu vaka sunumu ile kabakulağın, yaşlılarda da görülebileceğini, kabakulak miyokarditine bağlı tam atriyoventriküler blok gibi nadir ve ölümcül komplikasyonlara sebep olabileceğini vurgulamak istedik.

Olgu Sunumu: 80 yaşında bayan hasta sağ kulak çevresinde şişlik, yorgunluk, halsizlik, baş dönmesi, baygınlık hissi ve göğüs ağrısı şikayetleriyle acil servise başvurdu. Hastanın şikayetlerinin başlamasından yaklaşık iki hafta önce, hastanın torununda ateş ve sağ-sol kulak etrafında şişlik varmış. Hastanın vücut ısısı 37.5°C, kan basıncı 120/60 mmHg, kalp hızı 37/dakika tespit edildi. Sağ parotis bezi etrafında şişlik mevcuttu. Çekilen elektrokardiogramında tam atriyoventriküler blok tespit edildi. Hasta konsulte edilerek kardiyojini kliniğine devredildi.

Sonuç: Kabakulak daha sıklıkla çocukluk çağı hastalığıdır ve sıklıkla parotis ile seyredir. Fakat yaşlılarda da görülebilir ve ölümcül komplikasyonlara neden olabilir.

Anahtar Kelimeler: Acil servis, atriyoventriküler tam blok, bradikardi, kabakulak, miyokardit, yaşlı hasta

Geliş Tarihi: 29.01.2015 **Kabul Tarihi:** 25.03.2015

Çevrimiçi Yayın Tarihi: 09.04.2015

Introduction

Mumps is an acute, self-limited, highly infectious, systemic viral disease. Although more common in school-aged children, adults tend to be more severely affected by this disease than do children. Mumps is transmitted from person to person via respiratory droplets and saliva. The incubation period of mumps is 16-18 days. Following this period, prodromal symptoms such as low-grade fever, malaise, myalgias, headache, and anorexia occur. After 3-5 days, organ involvement is observed. The most common presentation is parotitis. Other reported sites of infection are the central nervous system, testes, ovaries, pancreas, and joints. Deafness, thyroiditis, hepatitis, nephritis, mastitis, prostatitis, cerebellitis, thrombocytopenia, and myocarditis are less

Address for Correspondence/Yazışma Adresi:

Şerife Özdiñç, Department of Emergency Medicine, Afyon Kocatepe University Faculty of Medicine, Afyonkarahisar, Turkey.
Phone: +90 272 246 33 22 E-mail: drseri03@hotmail.com

©Copyright 2015 by Emergency Physicians Association of Turkey - Available online at www.jaemcr.com

©Telif Hakkı 2015 Acil Tıp Uzmanları Derneği - Makale metnine www.jaemcr.com web sayfasından ulaşılabilir.

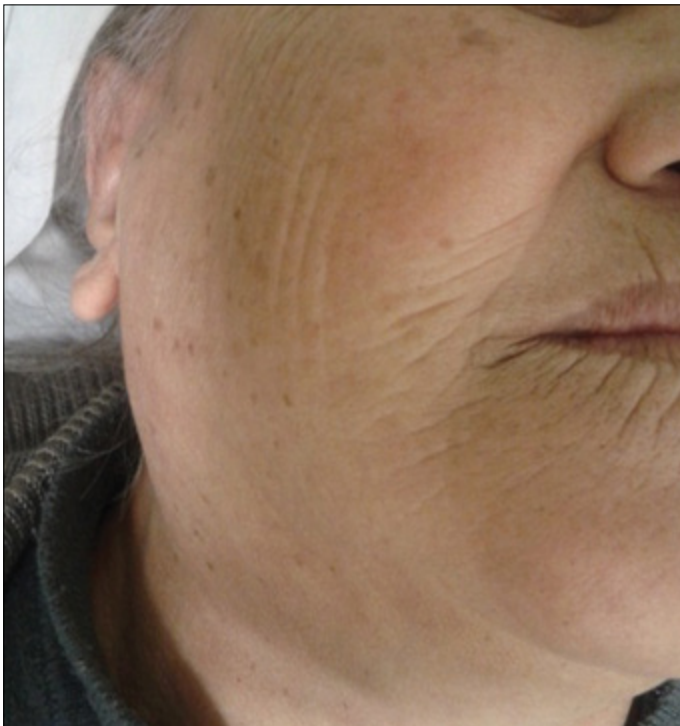

Figure 1. Swelling of the right parotid gland of the patient

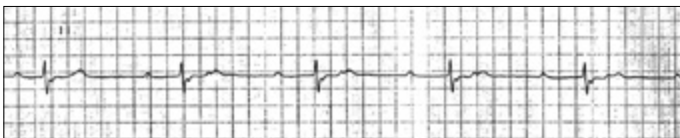


Figure 2. A complete atrioventricular block in the patient's electrocardiogram

common (1,2), with myocarditis being typically asymptomatic (3). Electrocardiographic findings related to mumps myocarditis are changes in ST segment and T wave, prolongation of the QRS wave, tachyarrhythmias, and bradycardia (3,4). Here we report the case of an 80-year-old woman with complete heart block associated with mumps myocarditis. We want to emphasize via the present case that mumps can also occur in elderly people and cause a mortal and rare complication, resulting in a complete atrioventricular (AV) block. To the best of our knowledge, this is the first elderly case of complete heart block associated with mumps myocarditis reported.

Case Report

An 80-year-old woman was admitted to the emergency room with complaints of swelling around the right ear, fatigue, weakness, dizziness, presyncope, and chest pain. In her history, she had had pyrexia of 38°C and a swelling of the right parotid gland approximately 1 week before. Her grandson had had a fever and swelling around the right and left ear approximately 2 weeks before the beginning of her own ailment. Finally, she complained of general fatigue, weakness, dizziness, presyncope, and chest pain. There were no remarkable features in either her personal medical history or that of her family. We learned from her family that she had undergone a check-up before her complaints began but no remarkable

pathological findings were detected. Her core temperature was 37.5°C, blood pressure was 120/60 mmHg, and pulse rate was 37 beats/min. There was swelling of the right parotid gland (Figure 1). Examination of all other systems yielded normal results. There was a complete AV block in her electrocardiogram (Figure 2). Her hematocrit; white blood cell count; sedimentation rate; and C reactive protein, blood urea nitrogen, serum electrolyte, and transaminase levels were all within the normal range. Serum amylase level was 2307 (28-100) units/L. Serum lipase level was in the normal range. Serum troponin T level was 0.037 (0-0.014) ng/mL, serum creatinine kinase and creatinine kinase MB levels were within normal ranges. Mumps immunoglobulin (Ig) G and Ig M were detected in the patient's serum using commercial Indirect Immunofluorescence Test (Anti-Mumps IIFT IgG/IgM, Euroimmun AG, Lübeck, Germany; Figure 3). Chest X-ray revealed normal results. Echocardiogram showed no pericardial effusion and normal left ventricular function. The patient then consulted a cardiology clinic and was hospitalized. She was monitored and administered conservative and supportive medical care. On the fifth day of hospitalization, hypotension and syncope occurred. Atropine was carefully administered (total 3 mg, intravenously); however, her vital signs did not improve. Hence, transcutaneous pacing was performed into her heart. Following this procedure, the patient's vital signs markedly improved. On the seventh day of hospitalization, the patient, whose symptoms and signs had improved, was discharged with recommendations. Informed consent was obtained.

Discussion

Mumps is generally believed to be a mild childhood ailment, but it can still cause dangerous complications, when observed in adults, as in the present case. Some of the possible complications of mumps include oophoritis, orchitis, meningitis, pancreatitis, deafness, cerebellitis, and also myocarditis (5). The incidence of myocarditis is 4%-15% (4). If myocardial involvement is not diffuse, signs of viral infection such as fever and myalgia can mask symptoms of myocardial dysfunction. Hence, the diagnosis of myocarditis can be omitted. In severe cases, heart failure symptoms can be observed. Angina-type chest pain, as in the present case, is common (3). In physical examination, systemic signs of viral infection, unilateral or bilateral parotitis, and signs of heart failure, tachycardia, bradycardia and others accompanying symptoms, can be detected. In the present case, we detected bradycardia and her pulse rate was 37 beats/min. Thirteen percent of adults with myocarditis have significant electrocardiographic findings such as ST segment and T wave changes and bradycardia. Bradycardia is a rare complication of mumps myocarditis and its actual incidence is unknown (4). Chest X-ray and echocardiography is generally not used as a diagnostic tool for mumps myocarditis. However, in diffuse myocarditis, signs of heart failure can be observed in chest X-ray and echocardiography. Cardiac markers may be increased, as in the present case. Serum amylase levels are increased in almost all patients. The increase in serum lipase levels is due to the involvement of the pancreatic gland. Mumps is confirmed by detecting mumps IgM antibodies in serum samples collected after symptom onset. A positive IgM test result indicates current or very recent infection or re-infection. Viral

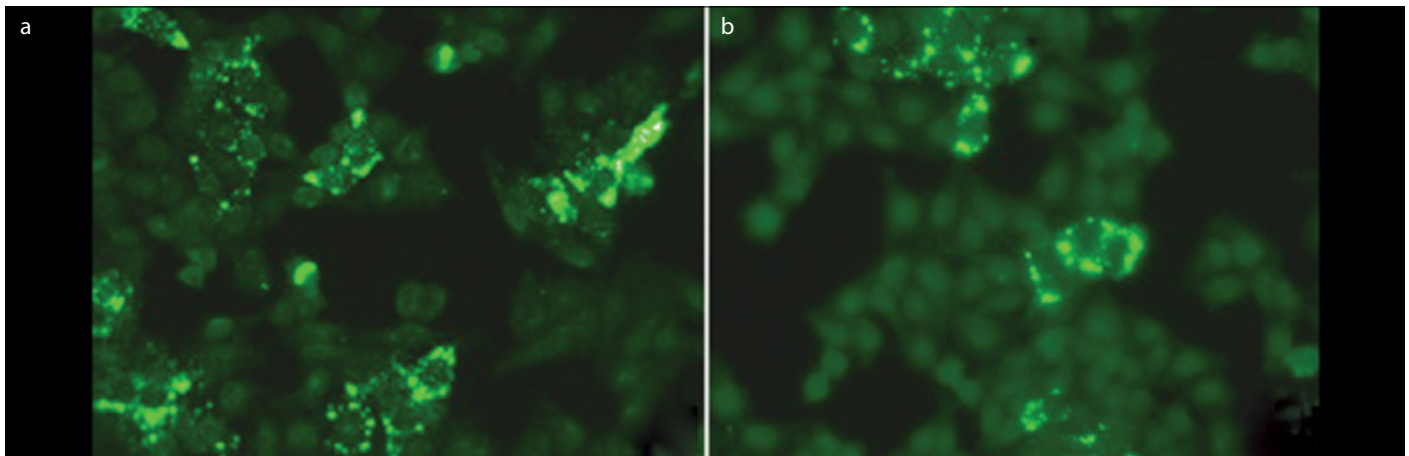


Figure 3. a, b. View of patient's anti-mumps immunofluorescent assay. Immunoglobulin M (a) and immunoglobulin G (b) with a 20x magnification fluorescence microscope

culture is the gold standard for mumps confirmation, whereas real time reverse transcriptase polymerase chain reaction is another method to detect mumps viral ribonucleic acid. Implementation of these methods is tedious. Therefore, standard serologic assays that detect mumps IgM in both enzyme immune assay (EIA) and immunofluorescence assay (IFA) formats are used in routine laboratories. Both EIA and IFA assays can perform well for diagnosis of primary mumps infection. Acute-phase mumps specimens may contain significant levels of mumps IgG. IFA format is particularly susceptible to interference by high levels of mumps IgG (6).

Although complete AV block associated with mumps myocarditis is typically benign (7), patients should be observed carefully because they can deteriorate. In the present case, hypotension and syncope occurred. Atropine was administered; however, her vital signs were not improved. Therefore, a transcutaneous pacing was performed into her heart. Myocarditis associated mumps are typically transient; however, transcutaneous pacing may be inevitable for symptomatic patients as in the present case. Moreover, complete AV block caused by mumps myocarditis is responsible for 8%-12% of the cases of sudden death (8).

Conclusion

Mumps is more common in children, and the most common presentation of the disease is a parotitis. We want to emphasize and create awareness with this case report that mumps can occur in elderly people and cause complete AV block associated with mumps myocarditis.

Informed Consent: Written informed consent was obtained from the patient who participated in this study.

Peer-review: Externally peer-reviewed.

Author Contributions: Concept - S.O., M.T.; Design - S.O., O.O.; Supervision - G.O., G.A.; Materials - S.O., M.T., G.O.; Data Collection and/or Processing - S.O., M.T., G.O., G.A.; Analysis and/or Interpretation - S.O., G.O., O.O., G.A.; Literature Review - S.O., G.A., O.O.; Writer - S.O.; Critical Review - G.O., O.O.

Acknowledgement: We thank Mr. John Christopher Bavin Embleton for English editing of our manuscript.

Conflict of Interest: No conflict of interest was declared by the authors.

Financial Disclosure: The authors declared that this study has received no financial support.

Hasta Onamı: Yazılı hasta onamı bu olguya katılan hastadan alınmıştır.

Hakem değerlendirmesi: Dış bağımsız.

Yazar Katkıları: Fikir - S.O., M.T.; Tasarım - S.O., O.O.; Denetleme - G.O., G.A.; Malzemeler - S.O., M.T., G.O.; Veri toplanması ve/veya işlemesi - S.O., M.T., G.O., G.A.; Analiz ve/veya Yorum - S.O., G.O., O.O., G.A.; Literatür taraması - S.O., G.A., O.O.; Yazıyı yazan - S.O.; Eleştirel inceleme - G.O., O.O.

Teşekkür: Makalemizin İngilizce edisyonu için John Christopher Bavin'e teşekkür ederiz.

Çıkar Çatışması: Yazarlar çıkar çatışması bildirmemişlerdir.

Finansal Destek: Yazarlar bu çalışma için finansal destek almadıklarını beyan etmişlerdir.

References

1. Krugman S, Katz SL, Gershon AA, Hotez PJ. Mumps. In: Gershon AA. Krugman's Infectious Diseases of Children. 11th ed. Philadelphia: Mosby, 2004. p. 391-401.
2. Nussinovitch M, Volovitz B, Varsano I. Complications of mumps requiring hospitalization in children. Eur J Pediatr 1995; 154: 732-4. [CrossRef]
3. Green GB, Hill PM. Cardiovascular Diseases. In Judith E. Tintinalli, MD, MS, Editor. Emergency Medicine. 10th ed. New York: McGraw-Hill; 2010. p. 361-473.
4. Alai MS, Suri P, Habib K, Lone NA. Complete Heart Block In Mumps Myocarditis. JK Science 2007; 9: 90-1.
5. Philip RN, Reinhard KR, Lackman DB. Observations on a mumps epidemic in a virgin population. Am J Hyg 1959; 69: 91-111.
6. Krause CH, Molyneaux PJ, Ho-Yen DO, McIntyre P, Carman WF, Templeton KE. Comparison of mumps-IgM ELISAs in acute infection. J Clin Virol 2007; 38: 153-6. [CrossRef]
7. Arita M, Ueno Y, Masuyama Y. Complete heart block in mumps myocarditis. Br Heart J 1981; 46: 342-4. [CrossRef]
8. Drory Y, Turetz Y, Hiss Y, Lev B, Fisman EZ, Pines A, et al. Sudden unexpected death in person less than 40 years of age. Am J Cardiol 1991; 68: 1388-92. [CrossRef]